

Methods of obtaining peripheral venous access in difficult situations

David Mbamalu, Ashis Banerjee

Summary

Peripheral venous access is frequently required in the hospital environment. This can occasionally be difficult to obtain. We have reviewed the pertinent literature and propose a structured algorithmic approach to reduce patient discomfort and to minimise the time involved in securing venous access.

Keywords: peripheral venous access; ultrasound; transillumination; venous cannulation

The placement of peripheral intravenous lines forms a significant part of the workload of junior medical^{1,2} and, increasingly, nursing staff^{3–6} in a hospital environment. However, peripheral venous line placement can be difficult, especially at the extremes of age or if the patient is obese, dark skinned, an intravenous drug abuser, is hypotensive or has multiple injuries limiting the number of limbs available for use.

Central venous line placement is not to be undertaken lightly as a substitute for difficult peripheral venous access. The procedures involved usually require a high level of operator skill, as well as conferring a risk of morbidity and mortality.^{7–9} Central venous lines can, in any case, be inserted via peripheral veins if required.^{10,11}

We therefore decided to review methods of obtaining peripheral venous access, with emphasis on difficult situations. We believe that proper selection of site and optimal technique will minimise the need for repeated attempts at venous access. We have devised an algorithmic approach to help in this situation.

We carried out a Medline search for the years from 1980 to 1998 using the keywords 'peripheral venous access' and 'venous cannulation'. We chose 35 articles for the purposes of the review. This includes a 1975 reference obtained by cross-referencing the articles initially generated. We also manually searched current textbooks on anaesthetics, intensive care, emergency medicine, phlebotomy and acute paediatrics. All the articles chosen were in the English language.

Methods of improving venous prominence and/or locating peripheral veins

In general, the upper limb is the preferred site for placing an intravenous cannula. This is because of the increased incidence of thrombophlebitis and thrombosis with lower limb infusions,^{12,13} as well as the need to often immobilise the patient if a drip is sited in the lower limb. The non-dominant upper limb is preferred as an initial option.

An attempt should initially be made to locate visible veins with the limb dependent, that is, below the level of the heart. A visible vein should also be easily compressible in order to qualify for use. The vein should be palpated by the operator's index finger to determine the relative size of the vessel and the direction in which it runs. A firm to hard non-compressible vein is indicative of thrombosis and not suitable for further efforts at venous access.

If the peripheral veins are not prominent and need to be made more prominent, gentle slapping of the skin overlying the vein may make it more prominent. The mechanism by which this occurs is unclear. This slapping must not be too firm as pain may cause reflex vasoconstriction. Milking the vein from proximal to distal may also increase venous prominence. Venous prominence is further augmented by the use of a proximal venous tourniquet. This can be either a purpose-made tourniquet or the tourniquet effect can be achieved by manual proximal circumferential compression of the limb by an assistant. The tourniquet should be applied 5–10 cm proximal to the selected site. This compression must be sufficient to permit arterial inflow whilst restricting venous outflow. In order to get accurate control of outflow occlusion, a sphygmomanometer cuff may be used. There are various views on what inflation pressure is best for this purpose but consensus opinion appears to indicate a choice of at or just below diastolic pressure.^{14–16} Manual limb compression by an assistant is difficult to control and, in our experience, a purpose-made tourniquet is preferable. Prolonged application of a venous tourniquet, for more than 5 minutes, increases venous tortuosity and fragility and should thus be avoided.

If venous prominence is not improved by these measures, asking the patient to grip and relax their hands repeatedly, and application of a warm compress (pads soaked in lukewarm water) for at least 2–3 minutes will improve venous visibility. This is achieved by increased local blood flow which increases venous

Accident and Emergency Department,
The Whittington Hospital, Highgate
Hill, London N19 5NF, UK
D Mbamalu
A Banerjee

Correspondence to Mr A Banerjee

Accepted 31 March 1999

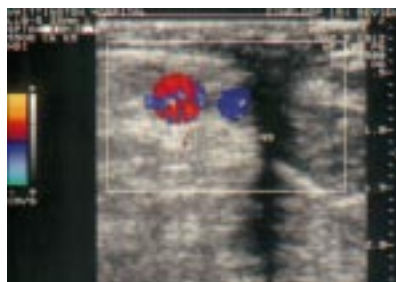


Figure 1 Transverse scan of right antecubital region, without tourniquet, using 10 MHz linear array probe. A = artery; V = vein; NS = shadow of needle/cannula assembly

distension. Immersing the limb in warm water may achieve the same effect. The use of betadine swabs is reportedly helpful in dark skinned patients.¹⁷ Gently wiping the skin with an alcohol swab may help visualisation of the vein as the reflection of the light off the skin changes.¹⁸

Transillumination may help at this stage. The lights in the treatment room need to be turned off and a torch can be placed under the limb to visualise the veins. Venous visualisation may also be possible, even with haematoma formation and with previously punctured veins. The Landry light is a portable battery-operated device which uses a halogen light source delivered through dual fibre-optic arms which rotate 360°. Veins can be identified through the fibre-optic arms as dark lines in the pinker subcutaneous tissue. Surface veins appear darker and more defined than the diffuse lines of deep veins. It does, however, require experience in interpreting visual cues, which is not difficult to acquire.^{19–21} Topical venodilation may be achieved by the application of 4% nitroglycerine ointment, smeared onto the skin and left for 2–3 minutes.^{22–24}

A venous distension device has been evaluated in adults in whom non-emergent intravenous cannulation was found to be difficult. This essentially relies on the production of a vacuum around the limb distal to a tourniquet.^{25–26} The device is a plastic film-covered cardboard mailing tube that can be placed over the forearm. A rubber sleeve attached to the distal end forms a seal after a blood pressure cuff is wrapped around the sleeve and the upper arm. A rubber squeeze bulb is attached to the distal end of the device and is used to generate a vacuum within the device. The cuff is used as a tourniquet. Although initial results were promising, the method does not seem to have gained widespread acceptance.

Infusion of small veins beyond a proximal tourniquet with a bolus of warm crystalloid may help in improving visualisation of larger veins, when large bore access is required.^{27–28}

Ultrasound-guided venepuncture has been described for placement of central venous lines via peripheral veins.^{29–33} This is operator dependent, with a long learning curve, but with increasing availability of ultrasound facilities in accident and emergency departments and perhaps on general wards and in clinics, may become an option for the near future. The use of a transversely oriented 7.5 MHz linear transducer is helpful to locate superficial veins (see figure 1) which can be identified even in the presence of oedema. In one study, a hand-held Doppler was felt to accurately identify forearm veins larger than 2 mm in diameter in patients with invisible and impalpable veins, in the presence of a venous tourniquet.³⁴

Peripheral venous cut-down is suggested as an option for securing venous access in an emergency situation, especially in multiple trauma victims.³⁵ A skin

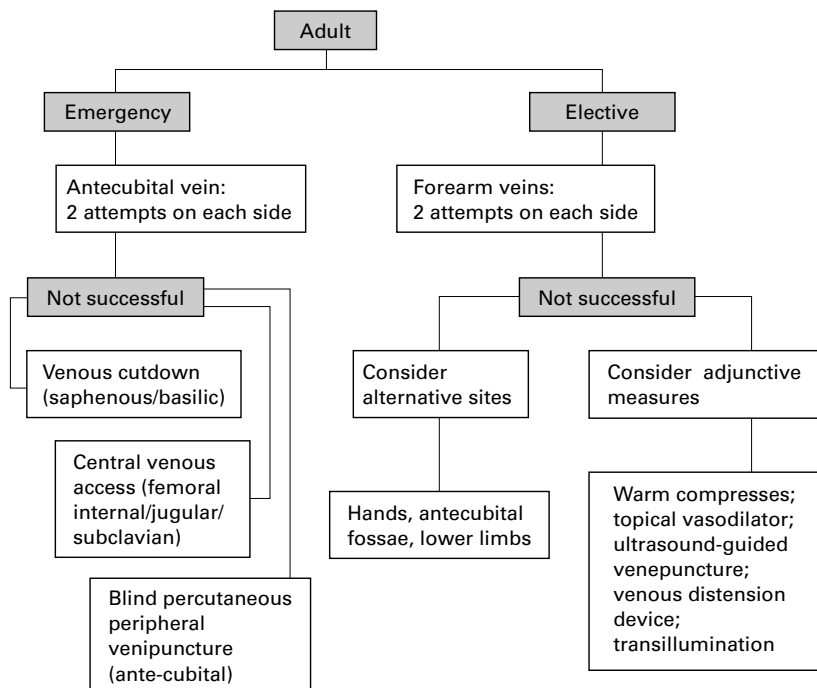


Figure 2 Algorithm for peripheral venous access in adults

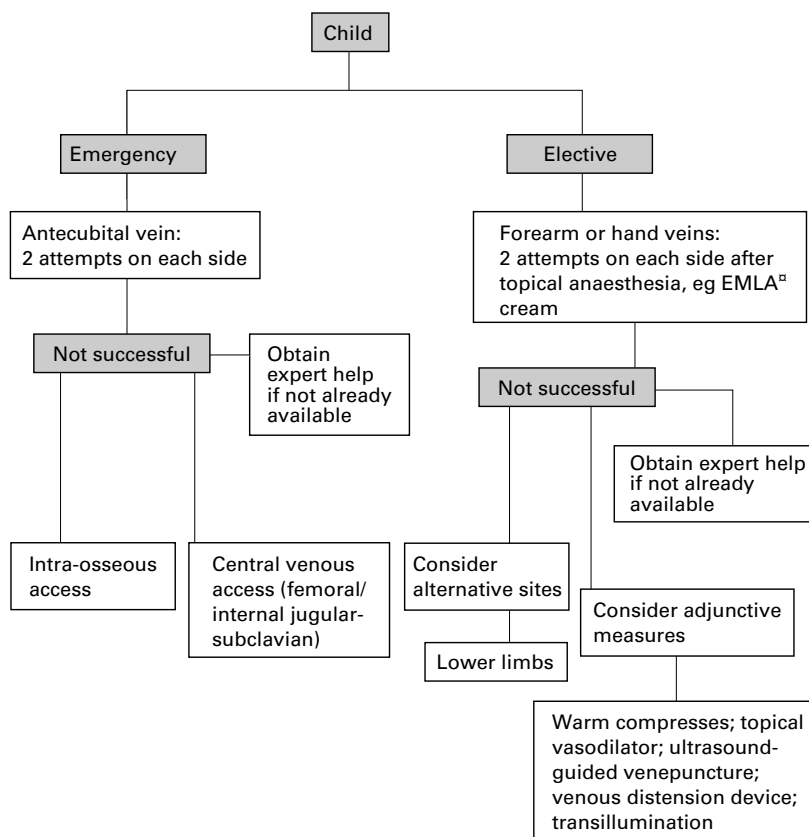


Figure 3 Algorithm for peripheral venous access in children

incision can be made directly over either the long saphenous vein in the ankle or the median basilic vein in the elbow. The vein is exposed by blunt dissection and cannulated under direct vision after making a small incision in the wall and ligating the distal end. The cannula is secured with another ligature to the proximal end. Even if the operator is not familiar with this procedure, a catheter over needle assembly can be introduced into the vein under direct vision.

There are a variety of methods described to improve peripheral venous access. The use of a sequential algorithmic approach (see figures 2 and 3) and the employment of adjunctive measures should make venepuncture less of an ordeal than it can be. A view has been expressed that structured venepuncture training is essential and we would concur with this view.³⁶

- NHS Management Executive. *Junior Doctors: The New Deal*. London: NHS Management Executive, 1991.
- Department of Health and Social Security. Hospital medical staffing: achieving a balance - plan for action. London: DHSS, 1987.
- Pickersgill F. A 'new deal' for nurses too? *Nursing Standard* 1993;35:21-2.
- United Kingdom Central Council for Nursing, Midwifery and Health Visiting. *The scope of professional practice*. London: UKCC, 1992.
- Inwood S, Taylor CF. Designing a nurse training programme for venepuncture. *Nursing Standard* 1996;10:40-2.
- Hand D. Taking a giant leap towards freedom. *Nursing Standard*, 1992;6(42):23
- Statter MB. Peripheral and central venous access. *Semin Paediatric Surg* 1992;1:181-7.
- Stenzel JP, Green TP, Fuhrman BP, et al. Percutaneous central venous catheterization in a paediatric intensive care unit: a survival analysis of complications. *Crit Care Med* 1989;17:984-8.
- Baskett PJF, Dow A, Nolan J, Maull K. *Practical procedures in anaesthesia and critical care*. London: Mosby, 1984; pp 8-13.
- Dudley HAF, Eckersley JRT, Paterson-Brown S. *A guide to practical procedures in medicine and surgery*. Oxford: Heinemann Medical Books, 1989; p 48.
- Lumley J, Russell WJ. Insertion of central venous catheters through arm veins. *Anaesth Intens Care* 1975;3:101-4.
- Tager IB, Ginsberg MB, Ellis SE, et al. An epidemiological study of the risks associated with peripheral venous catheters. *Am J Epidemiol* 1983;118:839-51.
- Clutton-Brock TH. How to set up a drip and keep it going. *Br J Hosp Med* 1984;32:162-7.
- Roberts GH, Carson J. Venepuncture tips for radiological technologists. *Radiol Technol* 1993; 65:107-15.
- Datta S, Hanning CD. How to insert a peripheral venous cannula. *Br J Hosp Med* 1990;43:67-9.
- Garza D, Becan-Mcbride K. *Phlebotomy handbook*. Stamford, CT, USA: Appleton and Lange, 1996; p 134.
- Bhende MS. Venepuncture and peripheral venous access. In: Henretting FM, King C, eds, *Textbook of paediatric emergency procedures*. Baltimore: Williams & Wilkins, 1997; p 803.
- Liu PL. Atlas of basic anaesthesia procedures. In: Barnett J, ed, *Principles and procedures in anaesthesiology*, Part VI. Philadelphia: Lippincott, 1992; p 381.
- Sieh A, Brentin L. A little light makes venepuncture easier. *R N* 1993;March:40-3.
- Nager AK, Karasic R. Use of transillumination to assist placement of intravenous catheters in the paediatric emergency department. *Paediatr Emerg Care* 1992;8:307.
- Zimmerman E. The Landry vein light: increasing venipuncture success rates. *J Paediatr Nurs* 1991;6:64-6.
- Vaksmann G, Rey C, Breviere GM, Smadja D, Dupuis C. Nitroglycerine ointment as aid to venous cannulation in children. *J Paediatr* 1987; 111:89-91.
- Roberge RJ, Kelly M, Evans TC, et al. Facilitated intravenous access through local application of nitro-glycerine ointment. *Ann Emerg Med* 1987;16:546-9.
- Michael A, Andrew M. The application of emla and glyceryl trinitrate ointment prior to venepuncture. *Anaesth Intens Care* 1996;24: 360-4.
- Hedges JR, Weinschenker E, Dirksing R. Evaluation of venous distension device: potential aid for intravenous cannulation. *Am J Emerg Med* 1986;15:540-3.
- Amsterdam J, Hedges J, Weinschenker E, Schwytzer DJ. Evaluation of venous distension device: phase II: cannulation of non-emergent patients. *Am J Emerg Med* 1988;6:224-7.
- Czepizak CA, O'Callaghan JM, Venus B, Gravestein N. Vascular access. In: Kirby RR, Gravestein N, eds, *Clinical anaesthesia practice*. 1994; p 547.

- 28 Williams DJ, Bayliss R, Hinchcliffe R. Intra-venous access: obtaining large bore access in the shocked patient. *Ann R Coll Surg Engl* 1997;79:466.
- 29 Jaques PF, Mauro MA, Keefe B. Ultrasound guidance for vascular access. *J Vasc Intervent Radiol* 1992;3:427-30.
- 30 Donaldson JS, Morello FP, Junewick JJ, O'Donovan JC, Lim-Dunham J. Peripherally inserted central venous catheters: US guided vascular access in paediatric patients. *Radiology* 1995;197:542-4.
- 31 Sofocleous CT. Sonographically guided placement of peripherally inserted central venous catheters: review of 355 procedures. *AJR* 1998;170:1613-6.
- 32 Cardella JF, Fox PS, Lawler JB. Interventional radiological placement of peripherally inserted central catheters. *J Vasc Intervent Radiol* 1993;4:653-60.
- 33 Crowley JJ, Pereira JK, Harris LS, Becker CJ. Peripherally inserted central catheters: experience in 523 children. *Radiology* 1997;204:617-21.
- 34 Whiteley MS, Chang BP, Marsh H P, Williams AR, Marton HC, Horrocks M. Use of hand-held Doppler to identify 'difficult' forearm veins for cannulation. *Ann R Coll Surg Engl* 1995;77:224-6.
- 35 *Advanced Trauma Life Support Course for Physicians*. Chicago: American College of Surgeons, 1993; p 109.
- 36 McConnell AA, Mackay GM. Venepuncture: the medicolegal hazards. *Postgrad Med J* 1996;72:23-4.

Images in medicine

Hydatid disease of the liver

A 72-year-old Greek man was admitted to the hospital because of hepatomegaly and a mild elevation of serum liver enzymes. He complained of mild epigastric discomfort, especially after meals. Physical examination showed a moderately enlarged, firm, and nodular liver. His white cell count was $11.8 \times 10^9/l$, with 16% eosinophils. A computed tomographic (CT) scan of the liver (figure) revealed large cystic, lobulated structures with daughter cysts, a picture consistent with hydatid disease of the liver. Hydatid disease or echinococcosis was confirmed by a high antibody titer to hydatid antigen.

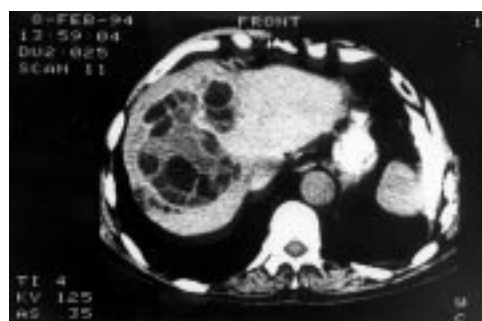


Figure CT scan of the liver

DEMETRIOS PAPAIOANNIDES
ANTHOULA PAPAGIANNI

*Department of Internal Medicine, General Hospital of
Arta, PO Box 92, 47 100 Arta, Greece*

NIKOLAOS AKRITIDES

*Department of Internal Medicine, 'Hatzikosta' General
Hospital, Makrygianni Avenue, 45 001 Ioannina, Greece*

Accepted 19 April 1999

Correspondence to Demetrios Papaioannides, PO Box 92, 47
100 Arta, Greece