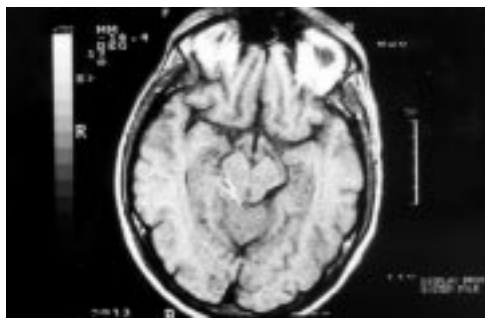

## A focal central nervous system mass in an AIDS patient with tuberculous meningitis

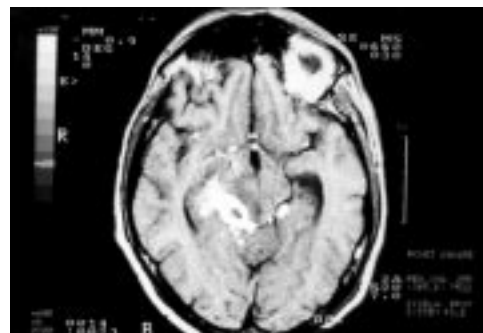Miguel Martín-Luquero, Luis A Marcos, Natalia Freijanes, José Luis Pérez-Castrillón

A 36-year-old man who had been seropositive for human immunodeficiency virus (HIV) for 2 years and who had not undergone treatment, was admitted to the hospital. He reported fever and headache during the week prior to admission. His CD4 count was  $26 \times 10^6/l$ . The results of the physical examination were unremarkable. Contrast-enhanced T-1 weighted magnetic resonance imaging (MRI) displayed basal meningeal involvement, but no evidence of a cerebral mass (figure 1). Cerebrospinal fluid (CSF) examination revealed 435 white blood cells/mm<sup>3</sup>, with 60% neutrophils and 40% lymphocytes, glucose 40 mg/dl, protein 199 mg/dl and adenosine deaminase 40 IU/l. The fluid smears were negative for acid-fast bacilli and a fluid culture revealed *Mycobacterium tuberculosis*. The *M tuberculosis* isolates were susceptible to isoniazid, rifampicin, ethambutol, and streptomycin. The patient received isoniazid (300 mg daily), rifampicin (600 mg daily), pyrazinamide (1500 mg daily) and ethambutol (1800 mg daily). Antiretroviral treatment with zidovudine and didanosine was initiated. The patient improved and was asymptomatic after 3 weeks.

One month later the fever re-appeared, the CD4 count was  $42 \times 10^6/l$ , and the HIV viral load was 2525 000 copies/ml. The patient also suffered from headaches and appeared lethargic. On physical examination he showed marked stiffness of the neck and left hemiparesis. Contrast-enhanced T-1 weighted MRI (figure 2) displayed a large mass with a hypo-intense centre in the perimesencephalic region.



**Figure 1** Contrast-enhanced T-1 weighted MRI at presentation



**Figure 2** Contrast-enhanced T-1 weighted MRI one month later

Department of  
Internal Medicine,  
Hospital Rio Hortega,  
University of  
Valladolid, Valladolid,  
Spain

M Martín-Luquero  
L A Marcos  
N Freijanes  
J L Pérez-Castrillón

Correspondence to  
José Luis Pérez Castrillón,  
Department of Internal  
Medicine, Cardenal  
Torquemada s/n, 47010  
Valladolid, Spain

Accepted 26 April 1999

### Questions

- 1 What is the differential diagnosis?
- 2 What is the clinical diagnosis?
- 3 What is the treatment?

## Answers

### QUESTION 1

The causes of focal CNS mass lesion in a patient with acquired immune deficiency syndrome (AIDS) appear in the box.

#### Causes of focal CNS mass lesion in AIDS

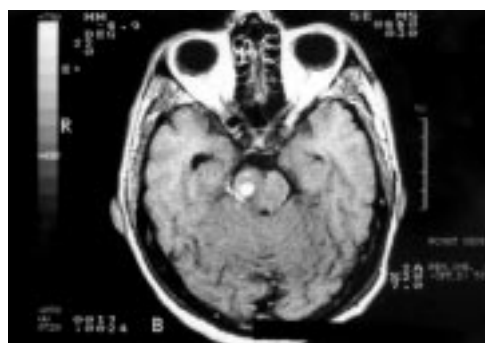
- toxoplasmosis
- primary CNS lymphoma
- cryptococcosis (pseudocyst)
- tuberculosis (granuloma)
- syphilis (gumma)
- abscess (cryptococcal, tuberculous or bacterial)

### QUESTION 2

The patient developed a mass lesion during adequate treatment for tuberculous meningitis. The MRI findings, in association with clinical and laboratory evidence of tuberculosis, suggest the paradoxical growth of an intracranial tuberculoma.

### QUESTION 3

The optimal therapy is unknown due to the rarity of the disease. It should be treated empirically with at least four drugs. The value of adjunctive steroids cannot be determined. The patient was treated with isoniazid, rifampicin, pyrazinamide, ethambutol and dexamethasone. He recovered, and a subsequent MRI displayed a partial resolution of the tuberculoma (figure 3).



**Figure 3** Contrast-enhanced T-1 weighted MRI after treatment

## Discussion

Tuberculosis has become another serious complication of AIDS, and the combination of both poses a significant clinical problem.<sup>1</sup> Intracranial tuberculoma are caseous foci with fibrous encapsulation which develop in association with deep-seated tubercles and which are acquired during periods of haematogenous dissemination.<sup>2</sup> They normally present with the symptoms and signs of a mass lesion. Headache, seizures, paralysis, and personality changes may be observed. CSF protein increase is common, but pleiocytosis is rare. The diagnosis is based on characteristic computed tomography or MRI findings in association with clinical and laboratory evidence of tuberculosis.

The patient displayed an unusual reaction during adequate treatment and his lesions worsened. The pathogenesis of paradoxical reactions remains unclear; they can occur during adequate treatment, and do not indicate the presence of drug-resistant organisms as a response to inadequate treatment.<sup>3-4</sup> The most probable explanation may be an enhanced immune response to dying tubercle bacilli following the initiation of therapy. Seven cases of paradoxical expansion of intracranial tuberculoma in AIDS patients had been previously reported.<sup>5-7</sup> The use of highly active antiretroviral therapy in HIV disease can result in some degree of immune reconstitution that may facilitate paradoxical expansion of tuberculoma. The immune status of our patient, however, was similar.

Our patient improved under treatment with corticosteroids, which are known to inhibit T-helper type 1 activity and tumour necrosis factor- $\alpha$  production and to stimulate T-helper type 2 cell activity, which may contribute to the regulation of immune response in paradoxical expansion.<sup>7</sup> Surgical intervention should be considered when medical therapy fails or for relief of intracranial pressure.

Tuberculosis must be considered in the differential diagnosis of contrast-enhancing lesions of the central nervous system in AIDS patients, including those who have been treated for tuberculosis.

### Final diagnosis

Paradoxical growth of intracranial tuberculoma during adequate treatment for tuberculous meningitis.

**Keywords:** intracranial tuberculoma; tuberculous meningitis; acquired immune deficiency syndrome

1 Berenguer J, Moreno S, Laguna F, *et al.* Tuberculous meningitis in patients with the human immunodeficiency virus. *N Engl J Med* 1992;326:668-72.  
 2 Leonard JM, Des Prez RM. Tuberculous meningitis. *Infect Dis Clin North Am* 1990;4:769-87  
 3 Teoh R, Humphries MJ, O'Mahony G. Symptomatic intracranial tuberculoma developing during treatment of tuberculosis: a report of 10 patients and review of the literature. *Q J Med* 1987;63:449-60  
 4 Afghani B, Lieberman JM. Paradoxical enlargement or development of intracranial tuberculomas during therapy: case report and review. *Clin Infect Dis* 1994;19:1092-9.

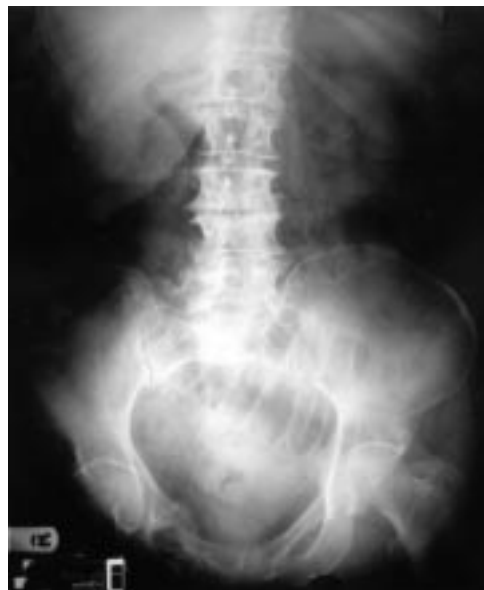5 Ramdas K, Minamoto GY. Paradoxical presentation of intracranial tuberculomas after chemotherapy in a patient with AIDS. *Clin Infect Dis* 1994;19:793-4  
 6 Crump JA, Tyrer MJ, Lloyd-Owen SJ, Han LY, Lipman MC, Johnson MA. Miliary tuberculosis with paradoxical expansion of intracranial tuberculomas complicating human immunodeficiency virus infection in a patient receiving highly active antiretroviral therapy. *Clin Infect Dis* 1998;26:1008-9  
 7 Lesprit P, Zagdanski A, De La Blanchardière A, *et al.* Cerebral tuberculosis in patients with the acquired immunodeficiency syndrome (AIDS). Report of 6 cases and review. *Medicine* 1997;76:423-31.

## Vomiting and constipation in an elderly diabetic woman

A Salih

An 80-year-old woman was admitted to William Harvey Hospital on 25 December 1997, with a 3-day history of generalised abdominal discomfort, intermittent vomiting and absolute constipation. Her medical history included hypertension, gall stones and insulin-dependent diabetes mellitus. There was no history of surgery.

On physical examination she was a moderately overweight woman, with mild dehydration, moderate abdominal distension, mild lower abdominal tenderness, normal bowel sounds and no evidence of inguinal or femoral herniae. Rectal examination revealed an empty rectum. Full blood count, urea and electrolytes, liver function test and serum amylase were normal. Her plain abdominal X-ray is shown in the figure.



### Questions

- 1 What does this plain abdominal X-ray show?
- 2 What is the most probable diagnosis?
- 3 How would you treat this patient?

William Harvey  
Hospital, Ashford,  
Kent TN24 0LZ, UK  
A Salih

Accepted 26 April 1999

**Figure** Plain abdominal X-ray