

## Short reports

# Spontaneous necrosis of parathyroid adenoma: biochemical and imaging follow-up for two years

W B Chan, C C Chow, A D King, V T F Yeung, J K Y Li, W Y So, C S Cockram

### Summary

**We report a patient with a biochemically and radiologically confirmed parathyroid adenoma, which underwent spontaneous resolution by necrosis. The patient was followed-up over the subsequent two years during which time the tumour and hypercalcaemia recurred. Sequential radiological and biochemical changes at the time of diagnosis, spontaneous necrosis and recurrence are documented fully.**

**Keywords:** hyperparathyroidism; hypocalcaemia; apoplexy

Primary hyperparathyroidism is one of the commonest endocrine disorders. However, spontaneous resolution by necrosis of a parathyroid adenoma is rare. Although there have been approximately 10 reported cases since the condition was first described in 1946,<sup>1</sup> in most cases the infarcted gland was removed soon after diagnosis. Therefore, the natural history, biochemical and hormonal changes following spontaneous infarction are not well known. We report a patient who had spontaneous infarction of her parathyroid adenoma, while awaiting surgery, with detailed documentation of the above-mentioned features.

### Case report

A 78-year-old woman was referred to our clinic for further management of Type 2 diabetes. She gave a history of renal stone, with right nephrectomy, 8 years before. She was put on oral hypoglycaemic therapy. She was found incidentally to have hypercalcaemia with a calcium concentration of 3.43 mmol/l (normal range 2.20–2.62 mmol/l) together with a reduced phosphate concentration of 0.55 mmol/l (0.82–1.40 mmol/l). Alkaline phosphatase was normal at 85 IU/l (45–145 IU/l). There was renal impairment with a plasma creatinine concentration of 160 µmol/l (44–107 µmol/l), but she had stable glycaemic control as indicated by a HbA<sub>1c</sub> concentration of 7.4%. Physical examination revealed mild peripheral neuropathy and the nephrectomy scar, but no obvious neck mass. Further investigations confirmed primary hyperparathyroidism. Her parathyroid hormone (PTH) was 44 pmol/l (1.16–5.67 pmol/l, intact PTH assay; coefficient of variation 7%) with concomitant plasma calcium of 3.40 mmol/l and ionized calcium of 1.61 mmol/l (1.13–1.32 mmol/l).

Ultrasound of the abdomen confirmed the previous right nephrectomy but showed no other abnormality. Her hypercalcaemia improved to approximately 2.8 mmol/l with adequate hydration, a low calcium diet and oral phosphate solution. She was referred for parathyroidectomy and was on the waiting list for surgery. During subsequent follow-up, her alkaline phosphatase gradually increased to 1465 IU/l, indicating development of parathyroid bone disease. Her glycaemic control was stable on oral hypoglycaemic therapy and there was no further deterioration of diabetic complications.

She was put on the waiting list for surgery, which was very long in our hospital. Two years later, she underwent pre-operative imaging to localise the parathyroid adenoma. Computed tomography (CT) showed a 2.5 × 1.5 cm well-defined parathyroid adenoma posterior to the upper pole of the left lobe of the thyroid. The adenoma was of homogenous soft tissue attenuation and revealed diffuse enhancement after contrast (figure 1). However, 4 months later, before surgery could be performed, she was admitted to our hospital having sustained a fracture of the right neck of femur after a fall. On admission, she was found to be hypocalcaemic (plasma calcium concentration 1.37 mmol/l (albumin adjusted)). Plasma phosphate was 0.89 mmol/l, magnesium was 0.55 mmol/l (0.67–1.01 mmol/l) and alkaline phosphatase was 1730 IU/l. Trousseau's sign was positive and the electrocardiogram showed a prolonged QT interval. She was treated with intravenous calcium gluconate followed by oral calcium supplementation and calcitriol. Magnesium was replaced with oral magnesium chloride. Two days later, the PTH concentration was 32.5 pmol/l and the calcium concentration 1.84 mmol/l. Serum 25-OH vitamin D3 concentration was 34 nmol/l (10–50 nmol/l). A CT scan of the neck showed no change in the size of the parathyroid adenoma but now there was evidence of central necrosis with a low attenuation centre which failed to enhance after contrast (figure 2). Plasma calcium was maintained within the normal range with calcitriol and oral calcium, and a right hip replacement was performed uneventfully.

On subsequent follow-up, her calcium level was maintained within the normal range and calcium and calcitriol doses were gradually reduced over a period of 8 months. The parathyroid hormone concentration dropped gradually to 5.4 pmol/l one month after admission and then showed a gradual rise during

Department of  
Medicine and  
Therapeutics, Prince  
of Wales Hospital, The  
Chinese University of  
Hong Kong, Hong  
Kong

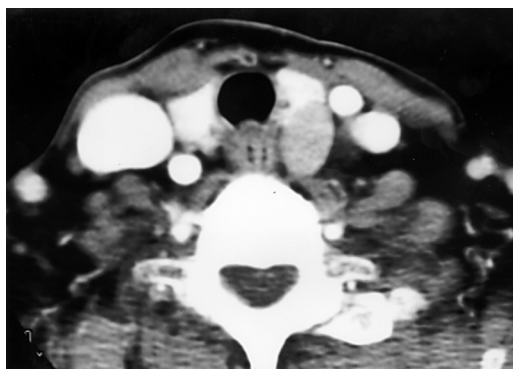
W B Chan  
C C Chow  
J K Y Li  
W Y So  
C S Cockram

Department of  
Radiology and Organ  
Imaging, Prince of  
Wales Hospital, The  
Chinese University of  
Hong Kong, Hong  
Kong

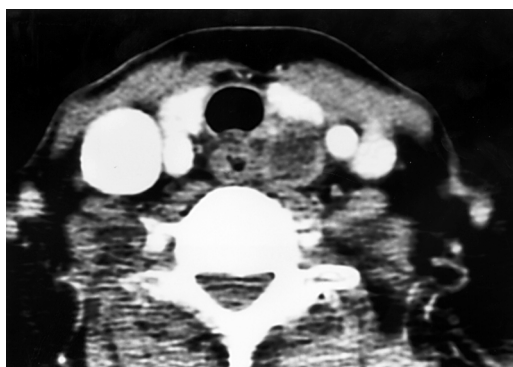
A D King

Department of  
Medicine, Our Lady of  
Maryknoll Hospital,  
Hong Kong.  
V T F Yeung

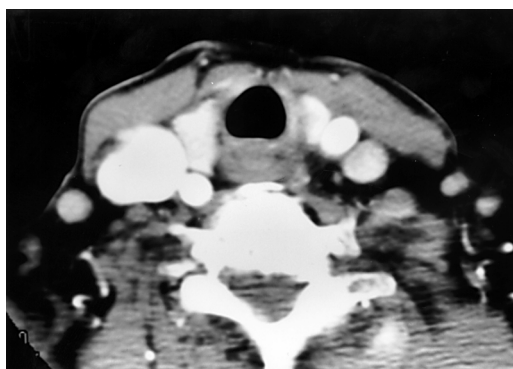
Submitted 1 June 1999  
Accepted 13 August 1999



**Figure 1** Contrast CT scan of the neck showing a parathyroid adenoma posterior to the left lobe of the thyroid at diagnosis



**Figure 2** Contrast CT scan of the neck at the time of spontaneous necrosis

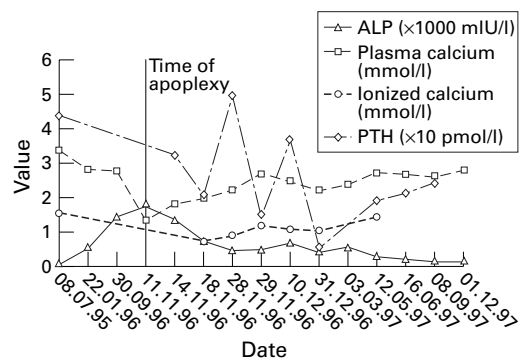


**Figure 3** Contrast CT scan of the neck at the time of involution

further follow-up. A further CT scan of the neck 3 months later showed involution of the parathyroid adenoma which had almost disappeared, leaving a residual 5 mm soft tissue mass (figure 3). Her calcium concentration rose beyond the normal range one month after calcium and calcitriol were stopped. Recurrence of primary hyperparathyroidism was confirmed with concomitant measurements of PTH (24.2 pmol/l) and plasma calcium (2.68 mmol/l). Details of the biochemical changes and clinical events are summarised in figure 4.

### Discussion

Parathyroid apoplexy, as described by Eric Nylen to signify parathyroid spontaneous



**Figure 4** Biochemical profile over 2 years

necrosis or haemorrhage, is a rare complication of primary hyperparathyroidism.<sup>2</sup> So far, only around 10 cases have been reported in the literature. Its presentation can be quite variable, including pressure symptoms due to haemorrhage,<sup>3-6</sup> neck pain,<sup>7-9</sup> hypercalcaemia due to acute release of stored PTH,<sup>10</sup> hypocalcaemia due to autoperathyroidectomy,<sup>1,2,8,11</sup> or normalisation of plasma calcium.<sup>9,12,13</sup> The biochemical changes can be drastic if there is significant necrosis, and death has been reported due to severe hypercalcaemia.<sup>10</sup> Most reported cases were treated by parathyroidectomy after the event and therefore the long-term consequences and clinical course remain unclear.

As our patient was already 77 years old at the time of parathyroid apoplexy, and was reluctant to undergo any further surgical intervention, it provided us with an opportunity to examine the subsequent course of this condition. She was relatively asymptomatic, despite severe hypocalcaemia. We did not observe a phase of transient worsening of hypercalcaemia. This may be due to delayed presentation, but agrees with some case reports of patients with normal or low calcium concentration at the time of presentation.<sup>1,2,8,11</sup> Of those cases in whom PTH concentration had been measured at the time of presentation, most showed a decrease in PTH soon after the episode of necrosis.<sup>2,9</sup> However, our patient had a persistently raised PTH level at presentation and subsequently showed a further rise to 49.4 pmol/l. Although the PTH level remained above the normal range, it stayed well below the initial level. We postulate that the abrupt drop in PTH due to parathyroid necrosis resulted in hypocalcaemia and hungry bone syndrome. The situation closely simulates that of surgical parathyroidectomy. This may have further triggered a secondary or compensatory response. This is supported by the observation that the PTH concentration gradually returned to near normal as the hypocalcaemia resolved with treatment. The other possibility was osteomalacia due to vitamin D deficiency. There has been a reported case of osteomalacia associated with primary hyperparathyroidism<sup>14</sup>; however, the normal vitamin D3 level excluded this diagnosis.

Although the necrotic parathyroid adenoma was not excised and hence there was no histo-

logical confirmation, the characteristic CT and clinical features appear confirmatory. In addition, the CT scan several months later showed continuous involution of the initial necrotic adenoma. This further confirmed the initial diagnosis of parathyroid adenoma necrosis. There have been reports of primary hyperparathyroidism entering remission after parathyroid gland necrosis.<sup>2 9 13 15</sup> However, in most reported cases, the necrotic parathyroid adenoma were excised.<sup>9 13 15</sup> A recent report by Nylen *et al* showed that the primary hyperparathyroidism could enter remission even without surgical excision.<sup>2</sup> By contrast, our patient exhibited recurrence of the disease 9 months after the acute event and the repeated CT 3 months after the event still showed a 5-mm soft tissue mass suggesting a remnant adenoma. Thus, such patients need to be followed closely as recurrence with a need for treatment is possible.

The cause of necrosis in our patient remains uncertain. There was no evidence to suggest previous hypotension, angiography<sup>16</sup> or thyroid surgery,<sup>5</sup> as suggested by previous reports, although hypotension related to fracture is still a possible cause. However, one common feature shared by all reported cases is that the adenomas exceed 1 cm in diameter, most

### Learning points

- primary hyperparathyroid patients with parathyroid adenoma greater than 1 cm diameter need early surgical excision in order to avoid potential crisis of apoplexy
- surgical removal of adenoma is still indicated after apoplexy due to the possibility of recurrence

exceeding 2 cm. Relatively large size may increase the risk of ischaemia and necrosis, and this may be an additional indication for early surgical intervention in subjects with parathyroid adenomas exceeding 1 cm in size.

### Conclusion

In summary, we present a case of parathyroid apoplexy complicated initially by hypocalcaemia, but with later recurrence of hypercalcaemia. The later recurrence of disease weighs in favour of surgical intervention in these patients. Review of the literature indicates that this complication occurs primarily in subjects with large parathyroid adenomas (>1 cm diameter).

- 1 Norris EH. Primary hyperparathyroidism. *Arch Pathol* 1946;42:261.
- 2 Nylen E, Shah A, Hall J. Spontaneous remission of primary hyperparathyroidism from parathyroid apoplexy. *J Clin Endocrinol Metab* 1996;81:1326-8.
- 3 Hotes LS, Barzilay J, Cloud LP, Rolla AR. Spontaneous hematoma of a parathyroid adenoma. *Am J Med Sci* 1989;297:331-3.
- 4 Berry BE, Carpenter PC, Fulton RE, Danielson GK. Mediastinal hemorrhage from parathyroid adenoma simulating dissecting aneurysm. *Arch Surg* 1974;108:740-1.
- 5 Pearl MA, Sternberg WH, Dingman JF. Unusual cases of hyperparathyroidism. *Arch Intern Med* 1962;110:481.
- 6 Jordan FT, Harness JK, Thompson NW. Spontaneous cervical hematoma: a rare manifestation of parathyroid adenoma. *Surgery* 1981;89:697-700.
- 7 Howard JE, Follis RH, Yendt ER, *et al*. Hyperparathyroidism. Case report illustrating spontaneous remission due to necrosis of adenoma, and a study of the incidence of necrosis in parathyroid adenoma. *J Clin Endocrinol* 1953;13:997-1008.
- 8 Northcutt RC, Levinson JD, Earnest JB. Hypocalcaemia resulting from infarction of a parathyroid adenoma. *Ann Intern Med* 1969;70:353-6.
- 9 Mclatchie GR, Morris EW, Forrester A, Fogelman I. Autoparathyroidectomy: a case report. *Br J Surg* 1979;66:552-3.
- 10 Dowlatabadi H. Acute fatal parathyroid poisoning associated with necrosis of the parathyroid adenoma prior to death. *J Clin Endocrinol* 1959;19:1481.
- 11 Johnston CC, Schnute RB. A case of primary parathyroidism with spontaneous remission following infarction of the adenoma with development of hypocalcemia tetany. *J Clin Endocrinol* 1961;21:196.
- 12 Connor TB, Clark JW, Martin LG, Lovice H. Intermittent hyperparathyroidism. *Trans Am Clin Climatol Assoc* 1965;77:80.
- 13 Mir R, Gerold T, Khan S, Weitz J. Spontaneous infarction of parathyroid adenoma: a case report and literature review. *Head Neck* 1993;15:566-8.
- 14 Natsui K, Tanaka K, Suda M, *et al*. Spontaneous remission of primary hyperparathyroidism due to hemorrhagic infarction in the parathyroid. *Intern Med* 1996;35:646-9.
- 15 Li JKY, Chow CC, Yeung VTF, *et al*. Primary hyperparathyroidism complicated by osteomalacia. *Ann Clin Biochem* 1996;33:571-4.
- 16 Farndon JR, Dale JK, Welles SA Jr. Selective arteriography causing infarction of a parathyroid adenoma. *J R Soc Med* 1982;75:978-80.