

Behçet's disease

V Kontogiannis, R J Powell

Abstract

Behçet's disease is a systemic vasculitis of unknown aetiology characteristically affecting venules. Onset is typically in young adults with recurrent oral and genital ulceration, uveitis, skin manifestations, arthritis, neurological involvement, and a tendency to thrombosis. It has a worldwide distribution but is prevalent in Japan, the Middle East, and some Mediterranean countries. International diagnostic criteria have been proposed, however diagnosis can be problematical, particularly if the typical ulcers are not obvious at presentation. Treatment is challenging, must be tailored to the pattern of organ involvement for each patient and often requires combination therapies.

(Postgrad Med J 2000;76:629–637)

Keywords: Behçet's disease; oral ulcers; uveitis; immunosuppressants

History

Remarkably this condition was recognised in the 5th century BC by Hippocrates,¹ re-described by the Greek Adamantiades in 1931,² but in 1937 the classical triad of oral and genital ulceration with ocular inflammation was reported by the Turk Hulusi Behçet.³ Further clinical features including cutaneous, neurological, vascular, gastrointestinal, and arthritis have since been identified. Until recently Behçet's disease was classified as a spondyloarthropathy⁴ but now is considered to be a systemic vasculitis.

Epidemiology

Onset of disease in the third decade of life is typical but it can occur at any age. Behçet's disease is most common in the so-called "silk route" countries, around the Mediterranean and in Japan, with prevalence rates per 100 000 of population being 80–300 in Turkey⁵ and 13.6 in Japan.⁶ It is much less common in Northern Europe: 0.55 in Germany,⁷ 0.27–0.64 in Britain,⁸ and in the USA is even more uncommon at 0.13.¹⁰

The male to female ratio is even in both northern Europe and Japan⁶ but increases significantly (1.5–5:1) in certain Mediterranean countries and the Middle East.^{11–14} Familial cases, although unusual, are also reported,¹⁵ particularly among Middle Eastern populations.¹⁶

Clinical presentation

Behçet's disease has a very wide spectrum of clinical features and it is characterised by unpredictable exacerbations and remissions.

Oral ulcers are a defining feature (97%–100% of cases)¹⁷ and are the initial symptom in most cases but not necessarily the presenting

symptom⁵ and can be minor, major, or herpetiform. Minor ulcers have a diameter <10 mm, are shallow, covered by a grey membranous slough, surrounded by an erythematous halo, and heal without scarring in 1–2 weeks. Major ulcers are morphologically similar but larger (>10 mm), deeper, more painful, and heal in 10–30 days or more often with scarring and tissue loss. Increased sensitivity of the area and even a mucosal nodule are frequently noted by patients before the ulceration develops. In herpetiform ulceration, numerous (10–100), 1–2 mm yellowish, papular lesions become confluent and form larger plaques and can heal with scarring.¹⁹ Ulcers frequently occur at the sites of trauma²⁰ and can be difficult to differentiate from recurrent oral aphthosis on the basis of severity, duration, and frequency. In Behçet's disease, increased number of ulcers (more than six at the same time), varying size and location (soft palate, oropharynx) are useful distinguishing features.¹⁸ Recurrent oral ulceration is often reported in other members of the patient's family. The favourable effect of smoking on recurrent oral ulceration,¹⁹ also appears to be evident in Behçet's disease.²¹

Genital ulcers are less common than oral ulcers occurring in 60%–80% of cases.⁶ They can be painful leading to problems both sitting down and walking, pain on intercourse, and dysuria. Morphologically, they are similar to mouth ulcers and their appearance can be preceded by a tender nodule. The scrotum is the most frequently involved site in males but ulcers on the shaft and glans penis are notable. In females, the ulcers most commonly occur on the labia but the vagina and cervix can be affected. Deep ulcers may scar and those in the vagina may be complicated by bladder or urethral fistulae.²² Groin, perineal, and perianal ulcers are reported. A lymphocytic and monocytic infiltrate in the dermis, particularly around the small vessels, typifies both oral and genital ulcers.

Skin lesions occur in about 80% of patients and can be divided into two main types—namely, erythema nodosum and the papulopustular/acneiform lesions. The erythema nodosum-like lesions are most commonly seen on the legs, they do not ulcerate and resolve leaving hyperpigmented areas. Histology shows a focal small vessel vasculitis/perivascular lymphocytic infiltrate involving particularly the venules with panniculitis.²³ Another cause of painful, erythematous nodules on the lower extremities is superficial thrombophlebitis which can be migratory and should be differentiated clinically from erythema nodosum. Acneiform and papulopustular lesions can occur at any site; they are sterile and morphologically very similar to adolescent

Clinical Immunology
Unit, University
Hospital, Queens
Medical Centre,
Nottingham NG7 2UH,
UK

V Kontogiannis
R J Powell

Correspondence to:
Dr Powell

Submitted 18 June 1999
Accepted 16 November 1999

acne. Histologically they are characterised by a leucocytoclastic vasculitis (neutrophil infiltrate) with fibrinoid necrosis.²⁴ Pyoderma gangrenosum,^{25 26} Sweet's syndrome,^{27 28} and erythema multiforme²⁹ have all been described with Behçet's disease.

The *pathergy* reaction represents hyper-reactivity in the skin following trauma, including minor injury (shaving, venepuncture sites, etc). The formal pathergy test involves intradermal pricking of the skin with a needle and it is considered positive if an erythematous papule or a pustule develops at the prick site within 48 hours. Histology reveals epidermal thickening, cell vacuolisation, subcorneal pustules, and a dense infiltrate of T lymphocytes and macrophages is present in the dermis especially around vessels.³⁰ The suppression of the reaction after surgical cleaning of the skin³¹ suggests a possible role of bacteria or skin products. Pathergy is highly specific for Behçet's disease, therefore has been included in the diagnostic criteria for the disease.³² A positive pathergy test has been reported in healthy individuals,³³ rarely in spondyloarthropathies,³⁴ and up to a quarter of patients with chronic myeloid leukaemia treated with interferon- α .³⁵ More than 60% of Turkish³⁶ and Middle Eastern³⁷ patients and 44% of the Japanese⁶ demonstrate pathergy. Pathergy is uncommon in individuals living in Britain and USA,^{10 38 39} which reduces its diagnostic value in these countries.

The possibility of compromised wound healing in the presence of pathergy has recently been addressed by a study from Turkey which revealed that although skin wounds in Behçet's disease are associated with increased inflammation, healing is not impaired.⁴⁰

Ocular involvement is bilateral in the majority of cases, although the severity may be asymmetrical.⁴¹ Characteristically, it occurs within the first 2–3 years of the onset of Behçet's disease⁴² being the presenting feature in approximately 20% of patients.⁴³ Its frequency varies from 40%–70% among different populations^{6 44 45} and visual loss occurs in up to 25% of the affected patients.⁴⁶ The clinical pattern of the eye disease is characteristically recurrent and explosive in nature with episodes lasting 2–4 weeks followed by periods of quiescence. Isolated anterior uveitis is a frequent and relatively benign lesion when isolated and although hypopyon is considered to be a characteristic sign of Behçet's disease, it is only observed in one third of cases.⁴⁵ Concurrent involvement of the posterior chamber is commonly seen⁴⁷ and can lead to blindness. This retinal disease is characterised by occlusion of arteries and veins with retinal haemorrhages, oedema, and neovascularisation as well as inflammation of the vitreous. Fluorescein angiography is particularly useful in revealing the extent and nature of the inflammation. The end stage disease is characterised by retinal and optic atrophy with attenuated retinal vessels and complications include glaucoma, cataract, and retinal detachment.⁴⁷

Milder forms of ocular disease such as episcleritis and conjunctivitis can also occur.

Typically a non-erosive, non-deforming *arthritis* is seen in about 50% of the patients with an oligoarticular or monoarticular pattern. The arthritis/arthralgias are usually transient in nature with episodes lasting from a few days to weeks involving peripheral joints, particularly the knees, ankles, and wrists.⁴⁸ Synovial fluid appears cloudy with an increased number of polymorphonuclear cells and good mucin clot formation, however synovial histology is not diagnostic.⁴⁹

Fatigue is a common symptom of Behçet's disease, which correlates with disease activity,⁵⁰ but must be distinguished from that associated with fibromyalgia which can co-occur, particularly females.³¹

A widespread *vasculitis* is the primary lesion in Behçet's disease and vessels of all sizes, both arteries and veins, may be involved in 9%–25% of patients depending on the population studied.^{6 8 51} A tendency for both superficial and deep vein thrombosis is well recognised, the veins of the lower extremities being the most commonly affected sites, however subsequent pulmonary embolism is uncommon.^{51 52} Thrombosis in the dural sinuses, superior and inferior vena cava and Budd-Chiari syndrome carry a poor prognosis.⁵³ Reduced synthesis of prostacyclin by the endothelial cells,⁵⁴ defective fibrinolytic activity,⁵⁵ and increased levels of endothelin-1⁵⁶ have all been reported in patients with Behçet's disease but these data do not correlate with clinical thrombosis.

Arterial aneurysms and occlusions are less common and are associated with the presence of venous thromboses.⁵⁷ Arteries of all sizes and sites may be affected^{51 52} and in particular pulmonary arterial aneurysms are a serious and potentially lethal complication seen on chest radiography as characteristic nodular shadows. These pulmonary aneurysms occur in approximately 1% of patients, almost exclusively males and the main presenting symptom is typically massive haemoptysis.⁵⁷

Neuro-Behçet's occurs in approximately 5% of cases. In parenchymal disease the brain stem is most frequently involved but the hemispheres, meninges, and spinal cord can also be affected either individually or in combination and during the course of the disease brain atrophy may develop.⁵⁸ Clinical presentations include bilateral pyramidal symptoms, mental changes, hemiparesis, cranial nerve palsies, sphincter disturbances, and brain stem symptoms in the majority of patients. Sensory signs are characteristically absent. Headaches should be regarded as part of central nervous system involvement only when other neurological signs and symptoms are also present. Isolated psychiatric symptoms and peripheral nerve involvement are rare.⁵⁹ Cerebrospinal fluid can be normal or show pleocytosis (neutrophils with or without lymphocytes), increased protein, and raised pressure. Magnetic resonance imaging (MRI) is more sensitive than computed tomography revealing mass-like lesions, isolated brain stem and basal ganglia lesions, multiple small white matter lesions, or lesions in the spinal cord.⁵⁸

Table 1 Criteria for diagnosis of Behçet's disease

Recurrent oral ulceration	Minor aphthous, major aphthous, or herpetiform ulceration observed by physician or patient, which recurred at least three times in one 12 month period
Plus two of:	
Recurrent genital ulceration	Aphthous ulceration or scarring, observed by physician or patient
Eye lesions	Anterior uveitis, posterior uveitis, or cells in vitreous on slit lamp examination; or retinal vasculitis observed by ophthalmologist
Skin lesions	Erythema nodosum observed by physician or patient, pseudofolliculitis, or papulopustular lesions; or acneiform nodules observed by physician in postadolescent patients not on corticosteroid treatment
Positive pathology test	Read by physician at 24–48 hours (findings applicable only in absence of other clinical explanations)

Surprisingly frequent are the audiovestibular abnormalities in Behçet's disease which have been demonstrated in more than half of the patients. Bilateral, symmetrical, sensorineural hearing loss of the cochlear type and unilateral peripheral vestibular dysfunction are the most common findings, although central deficits can develop.⁶⁰

Brain involvement secondary to arterial occlusions/aneurysms and dural sinus thromboses can also develop.

The prevalence of *gastrointestinal* involvement varies among different populations being particularly common in Japanese patients.⁶ Ulcers predominantly occur in the ileocaecal region,⁹ but can be seen throughout the intestinal tract, including the oesophagus, causing dysphagia, abdominal pain, and diarrhoea, which is occasionally bloody, and intestinal perforation and perianal fistulae can result.

Various other features are associated with Behçet's disease without being characteristic for this disease. Self limiting *epididymitis* is seen in 5%–10% of patients.⁴⁵

Although Behçet's disease is a systemic vasculitis, the kidneys are characteristically spared. Benign, mild proteinuria and microscopic haematuria may occur in some patients but only a few cases of biopsy proved glomerulonephritis have been reported.^{61 62} The kidneys can also be affected in cases complicated by amyloid deposits or renal vein thrombosis.⁶³ Systemic amyloidosis of the AA type is a very rare complication that can occur any time in the course of Behçet's disease,⁶⁴ but it should be considered in cases presenting with nephrotic syndrome particularly in patients of Mediterranean origin.

Cardiac involvement is unusual in Behçet's disease but cases of pericarditis,⁶⁵ valvular involvement,⁶⁶ coronary thrombosis and aneurysms,^{67 68} right ventricular thrombosis,⁵¹ and endomyocardial fibrosis⁶⁹ have all been documented. A recent study found mitral valve prolapse and dilatation of the proximal aorta in 50% and 30% of patients respectively.⁷⁰

Juvenile Behçet's disease is uncommon, accounting for 3%–7% of all cases,^{11 71} but only a few neonatal cases have been reported. Clinically, juveniles may have a less severe course,⁷² but an increased incidence and severity of ocular disease is reported in a single study.⁷¹

Pregnancy does not consistently alter the activity of the disease and equally, no increased incidence of miscarriages or other pregnancy complications have been identified among pregnant women suffering from Behçet's disease.⁷³

Diagnosis—disease activity

There are no diagnostic investigations for the disease the diagnosis relying solely on the clinical picture. Despite published diagnostic criteria³² (table 1), problems still arise as features may not be present at the same time and incomplete forms of the condition can occur.

Objective assessment of disease activity is problematical as erythrocyte sedimentation rate and C reactive protein are not consistently raised. The complement component C9 is reported to be raised during active disease,²⁹ but its discriminant value has not been assessed.

Permanent organ damage should be excluded from any current activity assessment and symptoms related to fibromyalgia or other conditions must not be attributed to active Behçet's disease.

Differential diagnosis

A detailed history is essential to reveal the existence of other clinical features of Behçet's disease. Isolated recurrent *oral and genital ulceration* (bipolar aphthosis Neumann)⁷⁴ does not fulfil the diagnostic criteria and may be a *forme fruste* of Behçet's disease.

Sarcoidosis can present with erythema nodosum, uveitis, and arthralgia but the presence of mouth ulcers, chest radiography findings and the chronic non-explosive course of uveitis⁴⁷ are useful distinguishing features.

Oral and genital lesions can occur in *Reiter's syndrome* where the arthritis is typically erosive with sacroiliac joint involvement and circinate balanitis and urethritis are not features of Behçet's disease.

Stevens-Johnson's syndrome involves the skin and mucosal surfaces with conjunctival inflammation but skin lesions are annular and posterior uveitis is not a feature.

Inflammatory bowel disease associated with oral ulcers and uveitis represents a diagnostic problem but in inflammatory bowel disease uveitis does not have such an explosive nature and retinal vasculitis is absent.

Multiple sclerosis can be difficult to distinguish from neuro-Behçet's, in the absence of other features of Behçet's disease.

The *Vogt-Koyanagi-Harada syndrome* is a granulomatous panuveitis associated with variable occurrence of poliosis, vitiligo, alopecia, auditory, and central nervous system signs. It is associated with HLA-DR4, is often complicated by cataracts and glaucoma and it is very responsive to steroid treatment.⁷⁵

PFAPA syndrome (Periodic Fever, Aphthous stomatitis, Pharyngitis, and cervical Adenitis) is a condition that affects children with a relapsing, benign course which may respond to short courses of steroids or cimetidine.^{76 77}

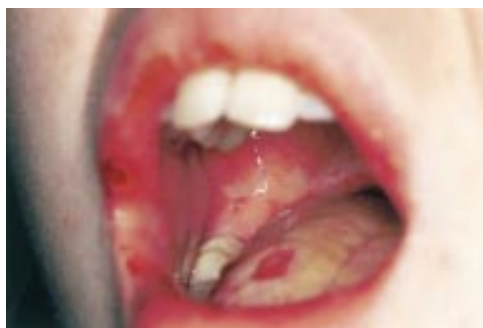

Figure 1 Aphthous ulcers involving the lip and tongue.

There are sporadic reports of patients with symptoms both of Behçet's disease and relapsing polychondritis, the so-called *MAGIC syndrome*.⁷⁸

See figs 1–8 for diagnostic features.

Aetiology/pathogenesis

It is a vasculitic condition of unknown aetiology but it is not a typical autoimmune disease having no female preponderance, no association with other autoimmune diseases or classically autoimmune associated HLA antigens (A1, B8, DR3, DR4) or autoantibodies. The geographic distribution of the disease favours an infective or environmental cause, although occasional familial cases occur.

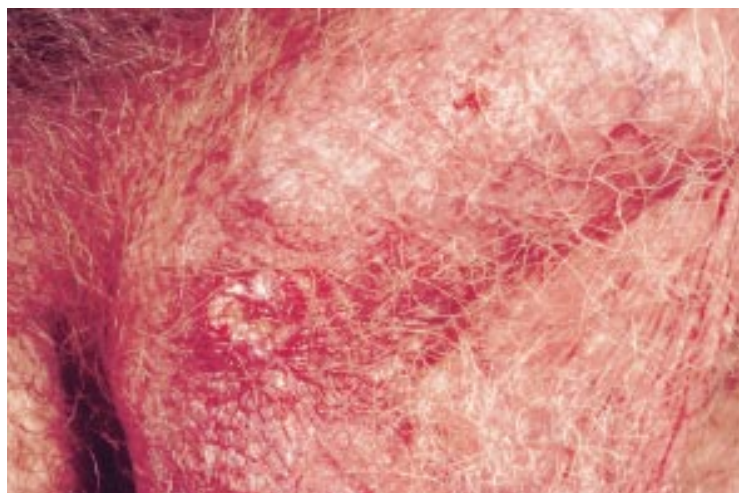


Figure 2 Scrotal ulcer healing with scarring.

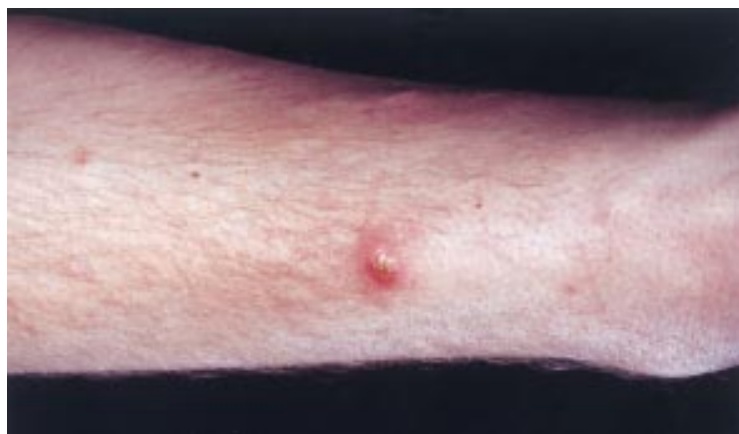

Figure 3 Acneiform skin lesion.

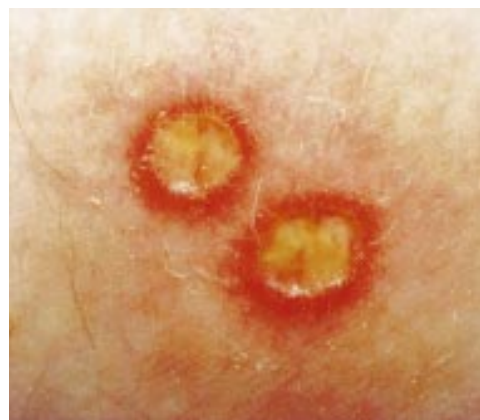

Figure 4 Pustular skin lesions remarkably resembling aphthous ulcers.

GENETICS

Several studies have confirmed a strong association with HLA-B51 particularly in patients from Japan⁷⁹ (B51 and DRw52), Mediterranean, and Middle Eastern countries^{37 42 70 80 81} whereas this is not mirrored in patients from Northern Europe and England.^{42 82 83} However in Northern Europe, HLA-B51 is more common in males than females and seems to be associated with uveitis.¹¹ In particular, the HLA-B*5101 allele in Japanese⁸⁴ and Greek⁸⁵ patients and both B*5101 and B*5108 in a population of European patients⁸⁶ seems to be important.

Recent studies suggest that MICA (major histocompatibility complex class I chain related gene A) which is located near the B51, may be the pathogenetic gene, as it occurs in a higher frequency than B51 in Japanese⁸⁷ and Caucasoids,⁸⁸ although this was not confirmed in Middle Eastern patients.⁸⁹ Further studies from Japan suggest that the susceptibility locus for Behçet's disease may be located between the MICA and HLA-B genes.⁹⁰

Familial cases of Behçet's disease are uncommon therefore is difficult to attribute the pathogenesis solely to genetic factors. Although the above findings are sometimes conflicting and their biological significance is not clearly understood, there could be two explanations for these associations (as in any HLA related disease): (1) only B51 may be able to express a critical peptide and (2) B51 may be responsible for the deletion of a T cell modulatory for the disease process.

Furthermore, the classical neutrophil hyper-reactivity notable in Behçet's disease has been strongly associated with HLA-B51 positivity. However this association applies regardless whether the individual suffers from Behçet's disease or not.^{91 92}

INFECTIVE

The geographic distribution and differences in the manifestations of the disease in different countries favour an infectious agent possibly acting as a trigger factor.

A viral aetiology was suggested by Behçet in his original publication, based on his observation of inclusion bodies in the ulcers.³ Particular attention has been drawn to herpes simplex

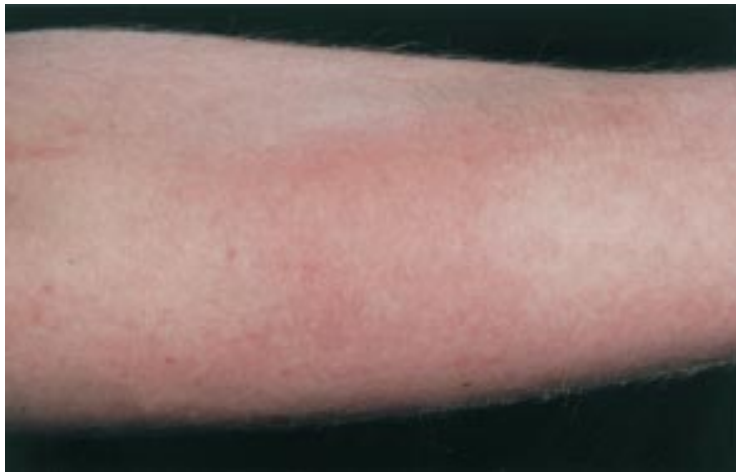

Figure 5 Erythema nodosum.

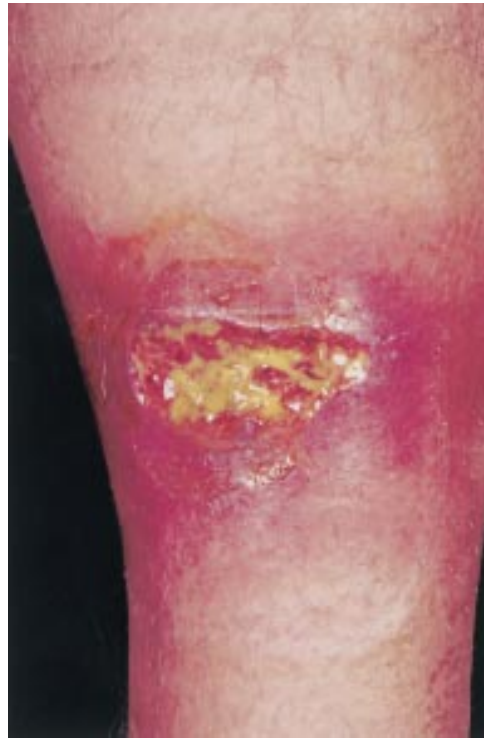

Figure 6 Typical pyoderma gangrenosum lesion in a young male patient with severe disease.

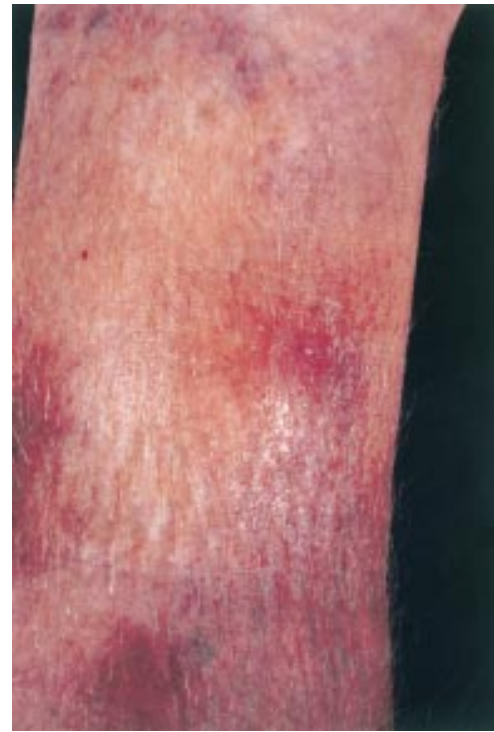

Figure 7 Superficial thrombophlebitis in the lower leg.

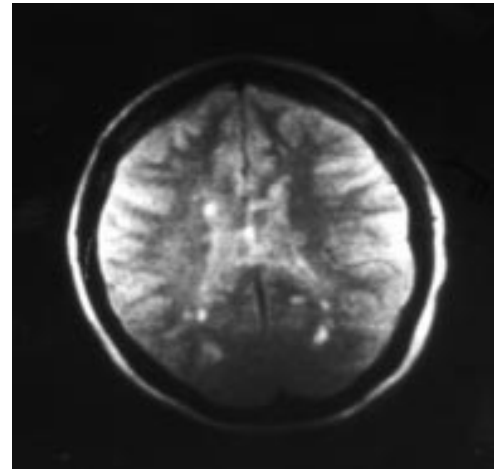


Figure 8 Brain MRI in a patient with neuro-Behçet's showing multiple lesions. The MRI findings in neuro-Behçet's are non-specific.

virus type 1 (HSV1). HSV1 genome has been identified by hybridisation in peripheral blood lymphocytes and monocytes of patients with Behçet's disease.^{93,94} Serum antibodies to HSV1 were found in a higher proportion in patients with Behçet's disease than in healthy controls, however viral DNA was not detected in biopsy samples taken from oral ulcers.⁹⁵ HSV1 DNA was found using the polymerase chain reaction in biopsy samples taken from genital ulcers of patients but not in biopsies from normal controls.⁹⁶ HSV1 DNA was found in all biopsy specimens of seven patients with Behçet's disease who had intestinal ulcers but only in two of 13 with Crohn's disease.⁹⁷ Although the results of the above studies are interesting, they need confirmation in larger studies.

The possible role of bacteria in the aetio-pathogenesis of Behçet's disease is also interesting. Serum antibody titres and delayed type hypersensitivity of patients with Behçet's disease against streptococcal antigens were found to be significantly higher than in controls and higher prevalence of an unusual type of *Streptococcus sanguis* was found in the oral flora of these patients.⁹⁸ It has been observed that dental treatment and streptococcal antigen skin testing can induce severe symptoms in stable Behçet's disease patients⁹⁹ and a higher incidence of tonsillitis and dental caries has been found in the presymptomatic period of patients with Behçet's disease.^{100,101} Furthermore, the pathergy reaction is significantly suppressed after surgical cleaning of the skin which results in the removal of bacterial organisms.¹⁰²

Production of inflammatory cytokines (interleukin (IL)-1, IL-6, IL-8, interferon gamma, and tumour necrosis factor-alpha (TNF- α)) by peripheral blood mononuclear cells and T lymphocytes is enhanced after in vitro stimulation of these cells with streptococcus related antigens suggesting that hypersensitivity to streptococcal strains may play a part in the pathogenesis of Behçet's disease.^{103 104}

Increased levels of IgA antibodies to the mycobacterial 65 kD heat shock protein (HSP), which cross reacts with strains of *S sanguis*, have been described in the serum of patients with Behçet's disease¹⁰⁵ and significant lymphoproliferative responses have been elicited after stimulation of T cells with the same HSP and four peptides derived from the 60 kD human HSP sequence.¹⁰⁶ One of the above HSP 60 kD peptides, which is also uveitogenic in experimental rats,¹⁰⁷ yielded vigorous proliferation in T cells of patients with Behçet's disease in comparison both with those with rheumatoid arthritis and healthy controls. The latter finding could indicate that the T cells were expanded oligoclonally (in an antigen specific manner) even before stimulation with the HSP.¹⁰⁴ However, another study documented hyper-responsiveness of T cells to superantigens and suggested that T cell hypersensitivity is a consequence of intrinsic T cell abnormalities.

The finding that the 60 kD HSP peptides have been found to stimulate predominantly $\gamma\delta$ -T cells has been suggested as a laboratory test for the diagnosis of the disease¹⁰⁸ but this test has not been widely adopted. Increased numbers of $\gamma\delta$ -T cells have also been observed in the cerebrospinal fluid of neuro-Behçet's patients.¹⁰⁹ The precise role of $\gamma\delta$ -T cells in Behçet's disease is not clearly understood but they may produce cytokines essential for the development of the disease, such as TNF- α .

Circulating immune complexes have been detected in 40%–60% of patients and were closely associated with disease activity¹¹⁰ but no deposition of immune complexes has been observed in the lesional biopsies.⁸² Other observations include reduced number of CD4+ cells¹¹¹, decreased activity of NK cells during active disease,¹¹² increased soluble IL-2 receptors¹¹³ and interferon gamma.⁹⁰ Levels of IL-10, IL-2, and sTNFR-75 (soluble TNF receptor-75) are raised in Behçet's disease and sTNFR-75 levels are reported to correlate with disease activity.¹¹⁴

Management

The diversity of clinical features demands the collaboration between various organ specialists and treatment must be tailored to the organ involvement and degree of severity of the individual patient.

TOPICAL TREATMENT

Oral ulceration can often be managed with soluble prednisolone mouthwashes (5 mg in 20 ml of water, four times a day, not to be swallowed) and corticosteroid pastes may be useful for deeper ulcers. Potent corticosteroid creams are useful for genital ulceration,

although long term use may be complicated by skin atrophy. Intra-articular corticosteroid injections are usually very effective in cases of severe joint involvement. Local mydriatics/steroids are useful during acute ocular attacks the former to prevent synechia formation.

SYSTEMIC TREATMENT

The treatment of Behçet's disease is highly problematical and one often has to resort to combinations of drugs in an attempt to control the various clinical manifestations. Only a few controlled trials are available and these will be denoted by an asterisk (*).

Non-steroidal anti-inflammatory drugs can be useful for symptom relief during attacks of arthritis.

Colchicine

Colchicine is an inhibitor of neutrophil migration, once a popular choice for any feature of the disease, has been shown to be effective only for erythema nodosum and arthralgia (*),¹¹⁵ and combined treatment with cyclosporin, may reduce the frequency of the ocular attacks.¹¹⁶

Azathioprine

Azathioprine, 2.5 mg/kg/day, reduces the development of new eye disease and the frequency of ocular attacks, has a favourable effect on arthritis, oral and genital ulceration, and thrombophlebitis (*),¹¹³ and improves the long term prognosis.¹¹⁷

Methotrexate

Methotrexate is reported to slow down the progression of neuropsychiatric disease¹¹⁸ and have a beneficial effect on cutaneous vasculitis.¹¹⁹

Cyclosporin A

Cyclosporin A is an effective, rapidly acting drug not only alleviating acute attacks of uveitis (thus preserving visual acuity), but also reducing the frequency of ocular attacks and extraocular features of the disease^{120 121} and is reported to have a favourable effect on hearing loss in Behçet's disease.¹²² Unfortunately relapses on reducing the dose or stopping treatment are often seen.

Tacrolimus

Tacrolimus (FK 506) is an immunosuppressive agent with an activity similar to cyclosporin A, which can suppress active uveitis even when cyclosporin A has failed, and it may be better tolerated.^{123 124} Cyclosporin and tacrolimus are drugs of choice for ocular involvement, however, their use can be limited by renal impairment and/or hypertension and regular monitoring of blood pressure, renal function, and blood trough levels is required.

Pulsed intravenous cyclophosphamide

Pulsed intravenous cyclophosphamide has shown to be as effective as cyclosporin A in the long term treatment of uveitis (*)¹²⁵ but is also useful in neurological and arterial involvement.^{57 126} Efficacy of regular, oral chlorambucil is also reported^{127 128} but controlled studies for both alkylating agents are lacking.

Systemic corticosteroids

Systemic corticosteroids have a role in uveitis and severe attacks of arterial and neurological disease in combination with immunosuppressants/cytotoxics and a synergistic action with cyclosporin A in ocular disease is reported.¹²⁹ Long term corticosteroids, however, should be avoided and recent evidence for another systemic vasculitis, namely systemic lupus erythematosus, shows that steroids are associated with increased mortality from coronary heart disease.¹³⁰

Thalidomide

Thalidomide, 100–300 mg/day, is very effective for oral and genital ulcers and follicular lesions of Behçet's disease and possibly prevents new eye disease (*).¹³¹ Cases of successfully treated associated pyoderma gangrenosum are also reported.^{26 132} Although it paradoxically leads to an exacerbation of the erythema nodosum,¹³¹ it is an extremely useful alternative for disabling ulceration when other treatments have failed. Because of the risks of teratogenicity and neurotoxicity, a published guideline for its use and dispensing is available.¹³³

Based on the evidence for a bacterial aetiology, penicillin^{134 135} (*) and minocyclin¹⁰⁴ have been tried in the treatment of Behçet's disease with reported improvement of ulceration, skin lesions, and arthritis.

Anticoagulation for thrombosis is appropriate, however the degree and duration of warfarin therapy is debatable. Despite adequate anticoagulation patients can develop new thromboses presumably related to the underlying vascular inflammation, which also demands specific treatment.

Surgical intervention is required in cases of arterial aneurysms, unfortunately with a high rate of recurrence and mortality¹³⁶ and in severe intestinal involvement.

Prognosis

Behçet's disease runs a chronic course with unpredictable exacerbations and remissions whose frequency and severity diminish with time.¹³⁷ Rupture of arterial aneurysms (particularly in young males), extensive thrombotic events, and perforated intestinal ulcers can be causes of death but the overall mortality does not appear to be higher than in general population.^{34 138} Morbidity, however, is high and ocular and neurological involvement may result in significant disabilities.

- 1 Feigenbaum A. Description of Behçet's syndrome in the Hippocratic third book of endemic diseases. *Br J Ophthalmol* 1956;40:355–7.
- 2 Adamantiades B. Sur un cas d'iritis à hypopyon recidivante. *Ann Ocul* 1931;168:271–4.
- 3 Behçet H. Über rezidivierende, apthose, durch ein Virus verursachte Geschwüre am Mund, am Auge und an den Genitalien. *Dermatol Wochenschr* 1937;36:1152–7.
- 4 Dilsen N, Konice M, Aral O. Why Behçet's disease should be accepted as a seronegative arthritis. In: Lehner T, Barnes CG, eds. *Recent advances in Behçet's disease*. London: Royal Society of Medicine Services, 1986: 281–4.
- 5 Yazici H, Yurdakul S, Hamuryudan V. Behçet's syndrome. In: Klippel JH, Dieppe PA, eds. *Rheumatology*. Vol 2. 2nd Ed. London: Mosby, 1998: 7.26.1–7.26.6.
- 6 Nakae K, Masaki F, Hashimoto T, et al. Recent epidemiological features of Behçet's disease in Japan. In: Wechsler B, Godeau P, eds. *Behçet's disease*. Amsterdam: Excerpta Medica, 1993: 153–8.

- 7 Zouboulis C, Djawari D, Kirch W, et al. Adamantiades-Behçet's disease in Germany. Data of the German registry in 1996. In: Hamza M, ed. *7th International conference on Behçet's disease*. Tunis: PUB ADHOUA, 1996: 180–5.
- 8 Chamberlain M. Behçet's syndrome in 32 patients in Yorkshire. *Ann Rheum Dis* 1977;36:491–9.
- 9 Jankowski J, Crombie I, Jankowski R. Behçet's syndrome in Scotland. *Postgrad Med J* 1992;68:566–70.
- 10 O'Duffy J. Summary of international symposium on Behçet's disease. Istanbul, September 29–30, 1977. *J Rheumatol* 1978;5:229–33.
- 11 Zouboulis C, Kötter I, Djawari D, et al. Epidemiological features of Adamantiades-Behçet's disease in Germany and in Europe. *Yonsei Med J* 1997;38:411–22.
- 12 Davatchi F. Epidemiology of Behçet's disease in middle East and Asia. *8th International conference on Behçet's disease* (abstract). Reggio Emilia: Prex srl, 1998: 42.
- 13 Zouboulis C. Epidemiology of Adamantiades-Behçet's disease in Europe. *8th International congress on Behçet's disease* (abstract). Reggio Emilia: Prex srl, 1998: 41.
- 14 Atmaca L, Idil A, Batioglu F. A descriptive study on Behçet's disease. *Acta Ophthalmol Scand* 1996;74:403–6.
- 15 Nishiura K, Kotake S, Ichii A, et al. Familial occurrence of Behçet's disease. *Jpn J Ophthalmol* 1996;40:255–9.
- 16 Kone-Paut I, Yurdakul S, Bahabri S, et al. Clinical features of Behçet's disease in children: an international collaborative study of 86 cases. *J Pediatr* 1998;132:721–5.
- 17 Yazici H, Yurdakul S, Hamuryudan V. Behçet's syndrome. *Curr Opin Rheumatol* 1999;11:53–7.
- 18 Main D, Chamberlain MA. Clinical differentiation of oral ulceration in Behçet's disease. *Br J Rheumatol* 1992;31:767–70.
- 19 Rogers RI. Recurrent aphthous stomatitis: clinical characteristics and associated systemic disorders. *Seminars Cutan Med Surg* 1997;16:278–83.
- 20 Wray D, Graykowski EA, Notkins AL. Role of mucosal injury in initiating recurrent aphthous stomatitis. *BMJ* 1981;283:1569–70.
- 21 Silveira L, McGrath H. Smoking controls symptomatology of Behçet's disease. *Arthritis Rheum* 1992;35(suppl):12S.
- 22 Dunlop E. Genital and other manifestations of Behçet's disease seen in venereological clinical practice. In: Lehner T, Barnes G, eds. *Behçet's syndrome. Clinical and immunological features*. London: Academic Press, 1979: 159–75.
- 23 Chun S, Su WP, Lee S, et al. Erythema nodosum-like lesions in Behçet's syndrome: a histopathologic study of 30 cases. *J Cutan Pathol* 1989;16:259–65.
- 24 Lakhanpal S, O'Duffy JD, Lie J. Pathology. In: Plotkin G, Calabro J, O'Duffy J, eds. *Behçet's disease: a contemporary synopsis*. New York: Futura Publishing Company, 1988: 102–42.
- 25 Lee E, Bang D, Lee S, et al. Dermatologic manifestations of Behçet's disease. *Yonsei Med J* 1997;38:380–9.
- 26 Rustin M, Gilkes J, Robinson T. Pyoderma gangrenosum associated with Behçet's disease: treatment with thalidomide. *J Am Acad Dermatol* 1990;23:941–4.
- 27 Lee MS, Barnetson R. Sweet's syndrome associated with Behçet's disease. *Australas J Dermatol* 1996;37:99–101.
- 28 Uysal H, Vahaboglu H, Inan L, et al. Acute febrile neutrophilic dermatosis (Sweet's syndrome) in neuro-Behçet's disease. *Clin Neurol Neurosurg* 1993;95:319–22.
- 29 Lehner T. Behçet's disease. In: Weatherall DJ, Ledingham JGG, Warrell DA, eds. *Oxford textbook of medicine*. Vol 3. 3rd Ed. Oxford: Oxford University Press, 1996: 3043–7.
- 30 Gül A, Esin S, Dilsen N, et al. Immunohistology of skin pathology reaction in Behçet's disease. *Br J Dermatol* 1995;132:901–7.
- 31 Yavuz S, Fresco I, Hamuryudan V, et al. Fibromyalgia in Behçet's disease. *J Rheumatol* 1998;25:2219–20.
- 32 International study group for Behçet's disease. Criteria for diagnosis of Behçet's disease. *Lancet* 1990;335:1078–80.
- 33 Aral O, Dilsen N, Konice M. Positive skin pathology reactivity as a genetic marker of Behçet's disease. In: Lehner T, Barnes C, eds. *Recent advances in Behçet's disease*. London: Royal Society of Medicine Services, 1986:173–5.
- 34 Kaklamani V, Vaiopoulos G, Kaklamani P. Behçet's disease. *Semin Arthritis Rheum* 1998;27:197–217.
- 35 Budak-Alpdogan T, Demircay Z, Alpdogan O, et al. Skin hyperreactivity in Behçet's patients (pathergy reaction) is also positive in interferon-alpha treated chronic myeloid leukaemia patients, indicating similarly altered neutrophil functions in both disorders. *Br J Rheumatol* 1998;37:1148–51.
- 36 Yazici H, Tüzün Y, Pazarlı H, et al. Influence of age of onset and patient's sex on the prevalence and severity of manifestations of Behçet's syndrome. *Ann Rheum Dis* 1984;43:783–9.
- 37 Assaad-Khalil S, Kamel F, Ismail E. Starting a regional registry for patients with Behçet's disease in North West Nile delta region in Egypt. In: Hamza M, ed. *7th International conference on Behçet's disease*. Tunis: PUB ADHOUA, 1996: 173–6.
- 38 Davies P, Fordham J, Kirwan J, et al. The pathergy test and Behçet's syndrome in Britain. *Ann Rheum Dis* 1984;43:70–3.
- 39 Yazici H, Chamberlain MA, Tüzün Y, et al. A comparative study of the pathergy reaction among Turkish and British patients with Behçet's disease. *Ann Rheum Dis* 1984;43:74–5.
- 40 Mat M, Nazarbachi M, Tüzün Y, et al. Wound healing in Behçet's syndrome. *Int J Dermatol* 1998;37:194–6.
- 41 Secchi A, Tognon S. Specific clinical aspects of ocular Behçet (abstract). *8th International congress on Behçet's disease*. Reggio Emilia: Prex srl, 1998: 74.
- 42 Yazici H, Tuzun Y, Pazarli H, et al. Behçet's disease as seen in Turkey. *Haematologica* 1980;65:381–3.

- 43 Mishima S, Masuda K, Izawa Y, et al. Behçet's disease in Japan: ophthalmologic aspects. *Trans Am Ophthalmol Soc* 1979;76:225-9.
- 44 Dündar S, Ünal S, Sivri B, et al. Behçet's disease in Turkish population: analysis of 200 cases. In: Lehner T, Barnes C, eds. *Recent advances in Behçet's disease*. London: Royal Society of Medicine Services, 1986: 219-21.
- 45 Shahram F, Davatchi, F, Akbarian M, et al. The 1996 survey of Behçet's disease in Iran, study of 3153 cases. In: Hamza M, ed. *7th International conference on Behçet's disease*. Tunis: PUB ADHOUA, 1996:165-69.
- 46 Hazleman B. Rheumatic disorders of the eye and the various structures involved. *Br J Rheumatol* 1996;35:258-68.
- 47 Nussenblatt R, Whitcup SM, Palestine A. Behçet's disease. In: Nussenblatt R, Whitcup SM, Palestine A, eds. *Uveitis*. 2nd Ed. St Louis: Mosby, 1996: 334-53.
- 48 Kim H, Choi K, Song Y. Arthropathy in Behçet's disease. *Scand J Rheumatol* 1997;26:125-9.
- 49 Yurdakul S, Yazici H, Tüzün Y, et al. The arthritis of Behçet's disease: a prospective study. *Ann Rheum Dis* 1983; 42:505-1.
- 50 Prokaeva T, Alekberova Z. Fatigue in Behçet's disease (abstract). *8th International congress on Behçet's disease*. Reggio Emilia: Prex srl, 1998: 268.
- 51 Koç Y, Güllü Y, Akpek G, et al. Vascular involvement in Behçet's disease. *J Rheumatol* 1992;19:402-10.
- 52 Müftüoğlu A, Yurdakul S, Yazici H, et al. Vascular involvement in Behçet's disease—a review of 129 cases. In: Lehner T, Barnes C, eds. *Recent advances in Behçet's disease*. London: Royal Society of Medicine Services, 1986: 255-60.
- 53 Bayraktar Y, Balkanci F, Bayraktar M, et al. Budd-Chiari syndrome: a common complication of Behçet's disease. *Am J Gastroenterol* 1997;92:858-62.
- 54 Kansu E, Sahin G, Sahin F, et al. Impaired prostacyclin synthesis by vessels wall in Behçet's disease (letter). *Lancet* 1986;ii:1154.
- 55 Aitchison R, Chu P, Cater G, et al. Defective fibrinolysis in Behçet's syndrome: significance and possible mechanisms. *Ann Rheum Dis* 1989;48:590-3.
- 56 Uslu T, Erem C, Tosun M, et al. Plasma endothelin-1 levels in Behçet's disease. *Clin Rheumatol* 1997;16:59-61.
- 57 Hamuryudan V, Yurdakul S, Moral F, et al. Pulmonary arterial aneurysms in Behçet's syndrome: a report of 24 cases. *Br J Rheumatol* 1994;33:48-51.
- 58 Serdaroglu P. Behçet's disease and the nervous system. *J Neurol* 1998;245:197-205.
- 59 Siva A. Clinical manifestations and prognosis in neuro-Behçet's syndrome. *8th International congress on Behçet's disease* (abstract). Reggio Emilia: Prex srl, 1998: 78.
- 60 Luxon L, Pollac L, Haskard D. Neuro-otological findings in Behçet's syndrome. *8th International congress on Behçet's disease* (abstract). Reggio Emilia: Prex srl, 1998: 223.
- 61 Hemmen T, Perez-Canto A, Distler A, et al. IgA nephropathy in a patient with Behçet's syndrome—case report and review of the literature. *Br J Rheumatol* 1997;36:696-9.
- 62 Akutsu Y, Itami N, Tanaka M, et al. IgA nephritis in Behçet's disease: a case report and review of the literature. *Clin Nephrol* 1990;34:52-5.
- 63 Ben Moussa F, Turki S, Ben Taarit C, et al. Renal involvement in Behçet's disease. In: Hamza M, ed. *7th International conference on Behçet's disease*. Tunis: PUB ADHOUA, 1996: 371-6.
- 64 Akpolat I, Akpolat T, Danaci M, et al. Behçet's disease and amyloidosis. Review of the literature. *Scand J Rheumatol* 1997;26:477-9.
- 65 Karma F, Kochbati S, Ksontini N, et al. Pericarditis in Behçet's disease (abstract). *8th International congress on Behçet's disease*. Reggio Emilia: Prex srl, 1998: 190.
- 66 Chikamori T, Doi Y, Yonezawa Y, et al. Aortic regurgitation secondary to Behçet's disease. A case report and review of the literature. *Eur Heart J* 1990;11:572-6.
- 67 Ioakimidis D, Georganas C, Panagoulis C, et al. A case of Adamantiades-Behçet's syndrome presenting as myocardial infarction. *Clin Exp Rheumatol* 1993;11:183-6.
- 68 Siepmann M, Kirch W. Coronary anomaly in Behçet's syndrome. *Rheumatol Int* 1997;17:39-42.
- 69 Huong D, Wechler B, Papo T, et al. Endomyocardial fibrosis in Behçet's disease. *Ann Rheum Dis* 1997;56:205-8.
- 70 Morelli S, Perrone C, Ferrante L, et al. Cardiac involvement in Behçet's disease. *Cardiology* 1997;88:513-7.
- 71 Shafaie N, Shahram, F, Nadji A. Iran's aspects of Behçet's disease in children. The 1996 survey. In: Hamza M, ed. *7th International conference on Behçet's disease*. Tunis: PUB ADHOUA 1996: 125-9.
- 72 Krause I, Uziel Y, Guedj D, et al. Childhood Behçet's disease: clinical features and comparison with adult-onset disease. *Rheumatology* 1999;38:457-62.
- 73 Marsal S, Falga C, Simeon C, et al. Behçet's disease and pregnancy relationship study. *Br J Rheumatol* 1997;36:234-8.
- 74 Pfrommer C, Hadlisch S, Kohl P, et al. Bipolar aphthosis Neumann: a report of two cases (abstract). *8th International congress on Behçet's disease*. Reggio Emilia: Prex srl, 1998: 124.
- 75 Moorthy R, Inomata H, Rao N. Vogt-Koyanagi-Harada syndrome. *Surv Ophthalmol* 1995;39:265-92.
- 76 Schibler A, Birrer P, Vella S. FPAPA syndrome: periodic fever, adenitis, pharyngitis and aphthous stomatitis. *Journal Suisse de Medecine* 1997;127:1280-4.
- 77 Marshall G, Edwards K, Lawton A. PFAPA syndrome. *Pediatr Infect Dis J* 1989;8:186-7.
- 78 Imai H, Motegi M, Mizuki N. Mouth and genital ulcers with inflamed cartilage (MAGIC syndrome): a case report and review of the literature. *Am J Med Sci* 1997;314:330-2.
- 79 Ohno S, Ohguchi M, Hirose S, et al. Close association of HLA Bw51 in Behçet's disease. *Arch Ophthalmol* 1982;100: 1455-8.
- 80 Zervas J, Vayopoulos G, Sakellaropoulos N, et al. HLA antigens and Adamantiades Behçet's disease (A-BD) in Greece. *Clin Exp Rheumatol* 1988;6:277-80.
- 81 Arber N, Klein T, Meiner Z, et al. Close association of HLA-B51 and B52 in Israeli patients with Behçet's syndrome. *Ann Rheum Dis* 1991;50:351-3.
- 82 Lehner T, Batchelor J. Classification and immunogenetic basis of Behçet's syndrome. In: Lehner T, Barnes C, eds. *Behçet's syndrome. Clinical and immunological features*. London: Academic Press, 1979: 13-32.
- 83 Bird Stewart J. Genetic analysis of families of patients with Behçet's syndrome: data incompatible with autosomal recessive inheritance. *Ann Rheum Dis* 1986;45:265-8.
- 84 Mizuki N, Inoko H, Ando H, et al. Behçet's disease associated with one of the HLA-B51 subantigens, HLA-B*5101. *Am J Ophthalmol* 1993;116:406-9.
- 85 Mizuki N, Ohno S, Ando H, et al. A strong association between HLA-B*5101 and Behçet's disease in Greek patients. *Tissue Antigens* 1997;50:57-60.
- 86 Kötter I, Steiert I, Günaydin L, et al. Frequent detection of HLA-B*5101 and B*5108 in patients of European origin with Behçet's disease (abstract). *8th International congress on Behçet's disease*. Reggio Emilia: Prex srl, 1998: 110.
- 87 Mizuki N, Inoko H, Ohno S. Molecular genetics (HLA) in Behçet's disease. *Yonsei Med J* 1997;38:333-49.
- 88 Amoura Z, Caillat-Zucman S, Wechler B, et al. Strong association between MICA 6 allele and Behçet's disease in caucasoids (abstract). *8th International congress on Behçet's disease*. Reggio Emilia: Prex srl, 1998: 107.
- 89 Verity D, Delamaine L, Vaughan R, et al. MHC class I related gene A9 (MICA 9) is associated with Behçet's disease (BD) in middle eastern patients (abstract). *8th International congress on Behçet's disease*. Reggio Emilia: Prex srl, 1998: 115.
- 90 Ohno S, Goto K. HLA association in Behçet's disease (abstract). *8th International congress on Behçet's disease*. Reggio Emilia: Prex srl, 1998: 44.
- 91 Sensi A, Gavioli R, Spisani S, et al. HLA B51 antigen associated with neutrophil hyper-reactivity. *Dis Markers* 1991;9: 327-31.
- 92 Takeno M, Kariyone A, Yamashita N, et al. Excessive function of peripheral blood neutrophils from patients with Behçet's disease and from HLA-B51 transgenic mice. *Arthritis Rheum* 1995;38:426-33.
- 93 Eglin R, Lehner T, Suback-Sharpe J. Detection of RNA complementary herpes-simplex virus in mononuclear cells from patients with Behçet's syndrome and recurrent oral ulceration. *Lancet* 1982;ii:1356-60.
- 94 Bonass W, Bird-Stewart J, Chamberlain MA, et al. Molecular studies in Behçet's syndrome. In: Lehner T, Barnes CG, eds. *Recent advances in Behçet's disease*. London: Royal Society of Medical Services, 1986: 37-41.
- 95 Studd M, McCance D, Lehner T. Detection of HSV-1 DNA in patients with Behçet's syndrome and in patients with recurrent oral ulcers by the polymerase chain reaction. *J Med Microbiol* 1991;34:39-43.
- 96 Bang D, Cho Y, Choi H-J, et al. Detection of herpes simplex virus DNA by polymerase chain reaction in genital ulcer of patients with Behçet's disease. In: Hamza M, ed. *7th International conference on Behçet's disease*. Tunis: PUB ADHOUA, 1996: 74-75.
- 97 Lee E-S, Lee S, Bang D, et al. Herpes simplex virus detection by polymerase chain reaction in intestinal ulcer of patients with Behçet's disease. In: Hamza M, ed. *7th International conference on Behçet's disease*. Tunis: PUB ADHOUA, 1996: 71-3.
- 98 Yoshikawa K, Kotake S, Matsuda H. Behçet's disease and streptococcal antigens. *Acta Societatis Ophthalmologicae Japonicae* 1996;100:173-80.
- 99 Mizushima Y, Matsuda T, Hoshi K, et al. Induction of Behçet's disease symptoms after dental treatment and streptococcal antigen skin test. *J Rheumatol* 1988;15:1029-30.
- 100 Kaneko F, Kaneda T, Ohnishi O, et al. Infection allergy in Behçet's disease. *Japanese Journal of Allergy* 1978;27: 440-50.
- 101 Tsuchida M, Mineshita S, Okonogi H, et al. The role of an uncommon type of *Streptococcus sanguis* in the aetiology of Behçet's disease. *Environmental Health and Preventive Medicine* 1997;2:59-63.
- 102 Fresko Y, Yazici H, Bayramiçli M, et al. Effect of surgical cleaning of the skin on the pathergy phenomenon in Behçet's syndrome. *Ann Rheum Dis* 1993;52:619-20.
- 103 Hirohata S, Oka H, Mizushima Y. Streptococcal related antigens stimulate production of IL-6 and interferon-gamma by T cells from patients with Behçet's disease. *Cell Immunol* 1992; 140:410-19.
- 104 Kaneko F, Oyama N, Nishibu A. Streptococcal infection in the pathogenesis of Behçet's disease and clinical effects of minocycline on the disease symptoms. *Yonsei Med J* 1997;38:444-54.
- 105 Lehner T, Lavery E, Smith R, et al. Association between the 65-kilodalton heat shock protein, *Streptococcus sanguis* and the corresponding antibodies in Behçet's syndrome. *Infect Immun* 1991;59:1434-41.
- 106 Pervin K, Childerstone A, Shinnick T, et al. T cell epitope expression of mycobacterial and homologous human 65-kilodalton heat shock protein peptides in short term cell lines from patients with Behçet's disease. *J Immunol* 1993;151:2273-82.

- 107 Stanford M, Kasp E, Whiston R, *et al.* Heat shock protein peptides reactive in patients with Behçet's disease are uveitogenic in Lewis rats. *Clin Exp Immunol* 1994;**97**:226–31.
- 108 Hasan A, Fortune F, Wilson A, *et al.* Role of $\gamma\delta$ T cells in the pathogenesis and diagnosis of Behçet's disease. *Lancet* 1996;**347**:789–94.
- 109 Yamashita N, Kaneoka H, Kaneko S, *et al.* Role of $\gamma\delta$ T lymphocytes in the development of Behçet's disease. *Clin Exp Immunol* 1997;**107**:241–7.
- 110 Levinsky R, Lehner T. Circulating soluble immune complexes in recurrent oral ulceration and Behçet's syndrome. *Clin Exp Immunol* 1978;**32**:193–8.
- 111 Powell R, Dunstan S. Immunopathology of Behçet's disease. *Postgrad Med J* 1991;**67**:503–5.
- 112 Hamzaoui K, Ayed K, Hamza M, *et al.* Natural killer cells in Behçet's disease. *Clin Exp Immunol* 1988;**71**:126–31.
- 113 Akoglu T, Direskeneli H, Yazici H, *et al.* TNF, soluble IL-2R and soluble CD-8 in Behçet's disease. *J Rheumatol* 1990;**17**:1107–8.
- 114 Turan B, Gallati H, Erdi H, *et al.* Systemic levels of the T cell regulatory cytokines IL-10 and IL-12 in Behçet's disease: soluble TNFR-75 as a biological marker of disease activity. *J Rheumatol* 1997;**24**:128–32.
- 115 Aktulga A, Altaç M, Müftüoğlu A, *et al.* A double blind study of colchicine in Behçet's disease. *Haematologica* 1980;**65**:399–402.
- 116 Kotake S, Aoyagi M, Watanabe K, *et al.* Combined cyclosporin and colchicine therapy for uveitis in Behçet's disease (abstract). *8th International congress on Behçet's disease*. Reggio Emilia: Prex srl, 1998: 239.
- 117 Hamuryudan V, Ozyazgan V, Hizli N. Azathioprine in Behçet's syndrome: effects on long term prognosis. *Arthritis Rheum* 1997;**40**:769–74.
- 118 Hirohata S, Suda H, Hashimoto T. Low-dose weekly methotrexate for progressive neuropsychiatric manifestations in Behçet's disease. *J Neurol Sci* 1998;**159**:181–5.
- 119 Jorizzo J, White W, Wise C, *et al.* Low-dose weekly methotrexate for unusual neutrophilic vascular reactions: cutaneous polyarteritis nodosa and Behçet's syndrome. *J Am Acad Dermatol* 1991;**24**:973–8.
- 120 Binder A, Graham E, Sanders M, *et al.* Cyclosporin A in the treatment of severe Behçet's uveitis. *Br J Rheumatol* 1987;**26**:285–91.
- 121 Masuda K, Nakajima A, Urayama A, *et al.* Double-masked trial of cyclosporin versus colchicine and long-term open study of cyclosporin in Behçet's disease. *Lancet* 1989;**i**:1093–6.
- 122 Elidan J, Levi H, Cohen E, *et al.* Effect of cyclosporin A on the hearing loss in Behçet's disease. *Ann Otol Rhinol Laryngol* 1991;**100**:464–8.
- 123 Sakane T, Mochizuki M, Inaba G, *et al.* A phase II study of FK506 (tacrolimus) on refractory uveitis associated with Behçet's disease and allied conditions (Japanese). *Ryumachi* 1995;**35**:802–13.
- 124 Sloper C, Powell RJ, Dua H. Tacrolimus (FK506) in the treatment of posterior uveitis refractory to cyclosporin. *Ophthalmology* 1999;**106**:723–8.
- 125 Ozyazgan V, Yurdakul S, Yazici H, *et al.* Low dose cyclosporin A versus pulsed cyclophosphamide in Behçet's syndrome: a single masked trial. *Br J Ophthalmol* 1992;**76**:241–3.
- 126 Du LT, Fain O, Wechsler B, *et al.* Value of "bolus" cyclophosphamide injections in Behçet's disease. Experience of 17 cases. *Presse Med* 1990;**19**:1355–8.
- 127 O'Duffy J, Robertson D, Goldstein M. Chlorambucil in the treatment of uveitis and meningoencephalitis of Behçet's disease. *Am J Med* 1984;**76**:75–84.
- 128 Schilling H, Bornfeld N, Windeck R, *et al.* Cytostatic and immunosuppressive treatment of ocular Behçet's syndrome. *Klinische Monatsblätter für Augenheilkunde* 1990;**196**:62–9.
- 129 Whitcup S, Salvo E, Nussenblatt RB. Combined cyclosporine and corticosteroid therapy for sight threatening uveitis in Behçet's disease. *Am J Ophthalmol* 1994;**118**:39–45.
- 130 Manzi S, Meilahn E, Rairie J, *et al.* Age-specific incidence rates of myocardial infarction and angina in women with systemic lupus erythematosus: comparison with the Framingham study. *Am J Epidemiol* 1997;**145**:408–15.
- 131 Hamuryudan V, Mat C, Saip S, *et al.* Thalidomide in the treatment of the mucocutaneous lesions of the Behçet syndrome. A randomised, double-blind, placebo-controlled trial. *Ann Intern Med* 1998;**128**:443–50.
- 132 Lilford R, Tindall V, Batchelor A. Post-surgical pyoderma gangrenosum of the vaginal vault associated with ulcerative colitis and Behçet's disease; a case report. *Eur J Obstet Gynecol Reprod Biol* 1989;**31**:93–4.
- 133 Powell R, Gardner-Medwin J. Guidelines for the clinical use and dispensing of thalidomide. *Postgrad Med J* 1994;**70**:901–4.
- 134 Calguneri M, Ertenli I, Kiraz S, *et al.* Effect of prophylactic benzathine penicillin on mucocutaneous symptoms of Behçet's disease. *Dermatology* 1996;**192**:125–8.
- 135 Calguneri M, Kiraz S, Ertenli I, *et al.* The effect of prophylactic penicillin treatment on the course of arthritis episodes in patients with Behçet's disease: a randomized clinical trial. *Arthritis Rheum* 1996;**39**:2062–5.
- 136 Tüzün H. Vascular surgery. *8th International congress on Behçet's disease* (abstract). Reggio Emilia: Prex srl, 1998: 89.
- 137 Tanaka C, Haramoto S, Matsuda T, *et al.* Studies on the clinical course of Behçet's disease. In: Hamza M, ed. *7th International conference on Behçet's disease*. Tunis: PUB ADHOUA, 1996: 217–8.
- 138 Yazici H, Basaran G, Hamuryudan V, *et al.* The ten year mortality in Behçet's syndrome. *Br J Rheumatol* 1996;**35**:139–41.