

ADVERSE DRUG REACTION

Colchicine induced rhabdomyolysis

I Chattopadhyay, H G M Shetty, P A Routledge, J Jeffery

Abstract

A case of colchicine induced rhabdomyolysis is reported. A 73 year old man with ischaemic heart disease, atrial fibrillation, chronic congestive cardiac failure, and chronic gout presented with diffuse muscle pain. He had been taking an increased dose of colchicine (1.5 mg daily) for an exacerbation of gout for six weeks before the presentation. Investigations confirmed the diagnosis of rhabdomyolysis and discontinuation of colchicine resulted in resolution of clinical and biochemical features of rhabdomyolysis. Although neuromuscular adverse effects of colchicine are well recognised, rhabdomyolysis is rare and this is only the fourth reported case of colchicine induced rhabdomyolysis in the literature.

(*Postgrad Med J* 2001;77:191-192)

Keywords: colchicine; rhabdomyolysis; gout

Colchicine is a unique anti-inflammatory agent that has been therapeutically used in acute gout for over 230 years. The adverse effects of the drug range from nausea, vomiting, diarrhoea, and abdominal pain to agranulocytosis, aplastic anaemia, and alopecia.¹ Colchicine has been reported to cause myoneuropathy² and myotonia³ especially in the presence of renal impairment. Rhabdomyolysis induced by colchicine is however rare. Herein we report a case of rhabdomyolysis associated with colchicine use in a patient suffering from gout.

Case report

A 73 year old man presented with a three week history of increasing shortness of breath, nausea, and diffuse muscle aches and pains. He had had ischaemic heart disease and atrial

Key points

- Colchicine may cause myoneuropathy, myotonia and, rarely, rhabdomyolysis.
- Colchicine induced myotoxicity may occur in presence of normal renal function.
- Cautious dosing of colchicine is important especially in presence of renal impairment.
- Any patient on colchicine should be monitored for neuromuscular adverse effects.

fibrillation for six years and chronic gout for five years. For six weeks before presentation he had been taking an increased dose of colchicine (1.5 mg daily) for an exacerbation of gouty arthritis. He had taken the drug in a lower dose (0.5-1 mg a day) on an occasional basis since the onset of his gout for a previous exacerbation. Other medications (with duration of ingestion) included digoxin 125 µg (six years), allopurinol 300 mg (four years), frusemide (furosemide) 160 mg (three years), lisinopril 20mg (one year), isosorbide mononitrate 60 mg (one year), and warfarin 3 mg (six months) all once daily and metolazone 2.5 mg twice a week (six months). He had no known muscle or renal diseases and consumed fewer than 10 units of alcohol a week.

Clinically, he was in controlled atrial fibrillation with moderate congestive cardiac failure. He had tender deltoid and thigh muscles, proximal muscle weakness (grade 4/5 power) in both the upper and lower limbs, and generalised hyporeflexia. The sensory system and coordination were intact. There was no rash or lymphadenopathy.

He had a grossly raised serum creatine kinase (36 200 U/l, normal 10-195 U/l) and serum myoglobin (>5000 µg/l, normal <98 µg/l) with a normal troponin-T concentration (0.16 µg/l, normal <0.2 µg/l). His blood urea and serum creatinine were 46.5 mmol/l (normal 2.5-7.5 mmol/l) and 208 µmol/l (normal 70-120 µmol/l) respectively on admission compared with 27.9 mmol/l and 201 µmol/l four weeks previously and 6.1 mmol/l and 107 µmol/l five months before, indicating a recent deterioration of his renal function. Urine tests were consistent with myoglobinuria. There was a normochromic normocytic anaemia (haemoglobin 105 g/l), a raised C reactive protein (28 mg/l, normal <6 mg/l), but normal thyroid and liver function tests and a negative autoimmune screen. The electrocardiogram did not show any evidence of a recent

Department of Geriatric Medicine, Ysbyty Gwynedd Hospital, Bangor, UK
I Chattopadhyay

Department of Integrated Medicine, University Hospital of Wales, Cardiff CF4 4XW, UK
H G M Shetty

Therapeutics and Toxicology Group, University Hospital of Wales College of Medicine, Cardiff, UK
P A Routledge

Department of Medical Biochemistry, University Hospital of Wales, Cardiff, UK
J Jeffery

Correspondence to: Dr Shetty
HLSHETTY@aol.com

Submitted 19 April 2000
Accepted 4 July 2000

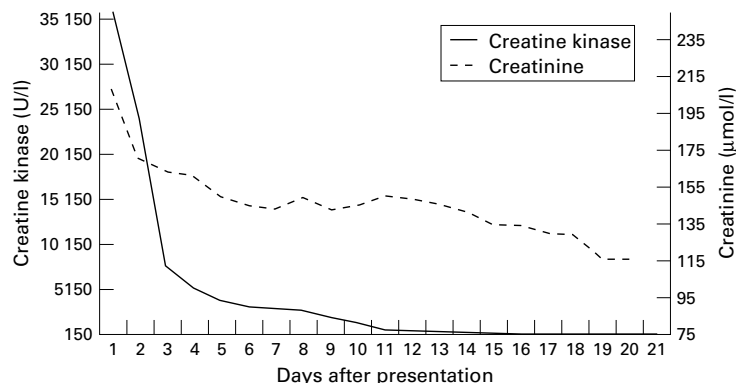


Figure 1 Plasma creatine kinase and creatinine concentrations after withdrawal of colchicine.

myocardial infarction and the echocardiogram confirmed moderate left ventricular dysfunction. Ultrasound scan of the kidneys was normal. A muscle biopsy was not performed as the patient was on warfarin and had an international normalised ratio of 2.5. Rhabdomyolysis was diagnosed on clinical and biochemical grounds. Colchicine was thought to be a factor in the genesis of the rhabdomyolysis because of the rapid onset of symptoms shortly after an increase in the dose of the drug and the lack of any alternative explanations for myotoxicity.

Colchicine was withdrawn and frusemide and lisinopril doses were reduced because of the renal impairment. By day 3, his muscle pain and tenderness had improved but he required assistance to walk. By day 4, his renal functions began to improve and the creatine kinase had fallen to 5294 U/l. By day 7 his muscle power had improved significantly and by day 20, his renal function had improved further and creatine kinase was normal (urea 6.5 mmol/l, creatinine 116 µmol/l, creatine kinase 161U/l) (fig 1). Fourteen days after colchicine withdrawal, his muscle power had returned to normal and he was mobilising independently.

Discussion

Neuromuscular adverse effects of colchicine in the form of myoneuropathy² and myotonia³ are well recognised. Rhabdomyolysis induced by colchicine is, however, rare with only three reports in the literature.⁴⁻⁶ One case each of myositis and polymyositis had previously been reported to the Committee on Safety of Medicine (CSM). This is the first case of colchicine induced rhabdomyolysis reported to the CSM. Although patients with impaired renal function appear to be at a higher risk for colchicine induced neuromuscular adverse effects,² the drug can be myotoxic even in presence of normal renal function⁵ as in our case. In some renal and cardiac transplant cases drug interaction with cyclosporin has been suggested to be the precipitating factor for colchicine myopathy.^{7,8}

The dosage and duration of colchicine ingestion does not seem to be clearly related to the risk of developing muscle toxicity.⁵ On an average most patients reported with myopathy

consumed 1 mg or more of the drug for more than six months.^{2,4} Rhabdomyolysis has been reported in a case of familial Mediterranean fever after ingestion of 1 mg of colchicine daily for one year.⁴ Our patient had consumed 1.5 mg of the drug daily for six weeks, similar to a previously described case of rhabdomyolysis.⁵

The pathogenesis of colchicine myopathy may be related to disruption of a cytoskeletal microtubular network that interacts with lysosomes.² Although an electromyogram in colchicine myopathy shows non-specific myopathic changes, a muscle biopsy specimen shows a characteristic vacuolar myopathy in the absence of necrosis.² Complete recovery is the rule and occurs, as in our case, within weeks of stopping colchicine. Corticosteroids have been used to hasten recovery in certain cases.⁵

This case highlights a rare but serious and potentially life threatening neuromuscular adverse effect of colchicine. Since pre-existent renal impairment is a predisposing factor for neuromuscular toxicity, cautious dosing of colchicine is warranted in the presence of abnormal baseline renal function. It is important to note, however, that colchicine may be myotoxic even in presence of normal renal function, as illustrated in our case. Hence any patient on the drug should be carefully monitored for symptoms of myotoxicity with measurement of creatine kinase when clinically indicated.

- 1 Insel P A. Analgesic-antipyretic and anti inflammatory agents and drugs employed in the treatment of gout. In: Hardman JG, Limbird LE, Molinoff PB, et al, eds. *The pharmacological basis of therapeutics*. 9th Ed. New York: McGraw Hill, 1996: 647-49.
- 2 Kuncel RW, Duncan G, Watson D, et al. Colchicine myopathy and neuropathy. *N Engl J Med* 1987;316:1562-8.
- 3 Rutkove SB, Girolami U, Preston DC, et al. Myotonia in colchicine myoneuropathy. *Muscle Nerve* 1996;19:870-5.
- 4 Stefanidis I, Bohm R, Hagel J, et al. Toxic myopathy with kidney failure as a colchicine side effect in familial Mediterranean fever. *Dtsch Med Wochenschr* 1992;117:1237-40.
- 5 Dawson TM, Starkebaum G. Colchicine induced rhabdomyolysis. *J Rheumatol* 1997;24:2045-6.
- 6 Del Favero A. Anti-inflammatory analgesics and drugs used in rheumatism and gout. In: Dukes MNG, ed. *Side effects of drugs*. Annual 5. New York: Excerpta Medica, 1981: 109.
- 7 Lee BI, Shin SJ, Yoon SN, et al. Acute myopathy induced by colchicine in a cyclosporine-treated renal transplant recipient—a case report and review of the literature. *J Korean Med Sci* 1997;12:160-1.
- 8 Rana SS, Giuliani MJ, Oddis CV, et al. Acute onset of colchicine myoneuropathy in cardiac transplant recipients: case studies of three patients. *Clin Neurol Neurosurg* 1997;99:266-70.