

ORIGINAL ARTICLES

Management of the impalpable testis: a six year review together with a national experience

E V Williams, T Appanna, M E Foster

Abstract

The management of undescended testes remains variable, and the use of laparoscopy for localisation is controversial. This study reviews the need for laparoscopy and also assesses the current practice among a cohort of surgeons.

A retrospective review of all patients undergoing orchidopexy was performed, together with a postal survey of all members of the Welsh Surgical Society.

Of the 139 orchidopexies performed, the testis was deemed impalpable in 39 (28%) cases. All patients were treated with groin exploration, and only in two (5%) patients was the testis not located. From the survey, replies were received from 90 (81%) surgeons, of whom 65 (72%) were still performing orchidopexy. Forty eight (74%) surgeons performed orchidopexy between the age of 2 and 3, and only 32 (36%) performed preoperative investigations. The follow up period was variable with the majority of patients seen at six weeks.

Laparoscopy for the impalpable testis is not initially warranted. An inguinal exploration is regarded as the definitive investigation. This has the advantage of providing the diagnosis and treatment in the majority of cases.

(*Postgrad Med J* 2001;77:320-322)

Keywords: cryptorchidism; impalpable testis; orchidopexy; laparoscopy

Cryptorchidism means hidden or obscure testis, and is generally synonymous with an undescended testis. Of newborn boys, between 1% and 3% have an empty scrotum,¹ thus making cryptorchidism one of the most common surgical disorders in childhood. Although its aetiology is unclear, the definitive treatment for true undescended testes is surgical placement into the scrotum, thereby improving fertility and decreasing the malignant potential.

The majority of cryptorchid testes are palpable but incompletely descended into the scrotum. As many as a third of these testes will likely be retractile when examined.² However, the non-palpable gonad constitutes 20% of all cases.³ It may be located anywhere between the upper scrotum and abdomen, or may even be absent. Accurate preoperative localisation of the non-palpable testes has been difficult, and

its need disputed. We conducted a study to answer the question: was groin exploration a correct method for diagnosis and treatment of the impalpable testis, or is laparoscopy indicated? We set out to look at our own experience and also to evaluate the current practice within a cohort of surgeons.

Subjects and methods

The first part of this study was a retrospective review of a single consultant's (MEF) experience of all patients who underwent orchidopexy between June 1991 and August 1997. The surgeon was a general surgeon who had a special interest in paediatric surgery, and worked in a district general hospital. These patients were identified from clinical coding and theatre registers. Orchidopexy for reasons other than undescended testes were excluded. Case notes were reviewed for details of age, side of undescended testis, preoperative palpability, and the type of operation performed.

The second part was a survey comprising a single sheet questionnaire (appendix) which was sent to all practising surgeons in Wales between August and October 1997. The list with surgeons' names and addresses was obtained from the computer based Welsh Surgical Society database, and included consultant surgeons in general, paediatric, and urological surgery based in two teaching and 15 district general hospitals. The questionnaires were dispatched with a covering letter explaining the purpose of the survey, and a stamped addressed envelope for a speedy return. All replies were anonymous.

Results

A total of 113 boys with a median age of 3 (range 2-9) years were identified with 139 undescended testes. Of these 139, the testes were deemed impalpable in 39 (28%) cases. All patients were treated primarily with groin exploration, and in only two (5%) cases was the testicle not located. These two children subsequently underwent laparoscopy. In the first boy the testis was found on the posterior abdominal wall, and thus an orchidectomy was therefore performed. In the other boy the testis was absent.

From the survey, replies were received from 90 surgeons, a response rate of 81%. Of the respondents, 65 (72%) surgeons were still performing orchidopexy, of which 53 (82%) were general surgeons, 10 (15%) were urologists, and two (3%) were paediatric surgeons (fig 1).

Department of
Surgery, Royal
Glamorgan Hospital,
Llantrisant CF72 8XR,
UK
E V Williams
T Appanna
M E Foster

Correspondence to:
Mr Foster

Submitted 15 March 2000
Accepted 20 September 2000

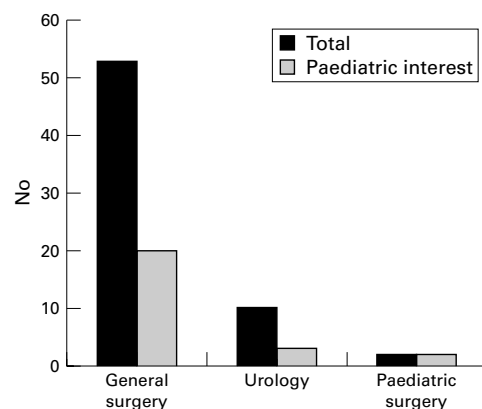


Figure 1 Subspecialties of the respondents.

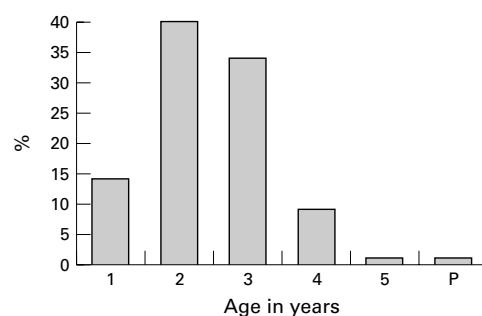


Figure 2 Age of operation.

The age of operation by Welsh surgeons is shown in fig 2, with only 35 (54%) surgeons operating in patients younger than 2 years old. One surgeon operated at the age of presentation. Under half (45%) of the surgeons stated that they would not perform any investigations for the impalpable testes. Of the investigations performed 24 (37%) surgeons would utilise ultrasound, five (8%) would use computed tomography, and three (5%) magnetic resonance imaging (MRI). Only three (5%) surgeons, however, would perform laparoscopy as their primary investigation. One surgeon did not specify a preference.

The operation of orchidopexy was performed by 48 (74%) surgeons as a day case. The follow up was variable, with 32 (64%) surgeons seeing their patients between six and 26 weeks. However, 20 (26%) would follow their patients up for a year or more.

Discussion

The major indications for surgically placing a cryptorchid testis into the scrotum are to enhance fertility, to repair a concomitant hernia, and to reduce the incidence of trauma and pain. Orchidopexy further reduces the likelihood of torsion, produces psychological and cosmetic benefits, and provides easier examination for testicular tumour. Management of the impalpable testis is however more complex. Consideration must be given as to whether the testis is absent or not. In our series there is only one patient with an absent testis. This is lower than the reported incidence, where reports of up to 59% of unilateral non-palpability are due to testicular absence, and 5% of bilateral non-palpable testis are due to anorchia.⁴⁻⁵ In these patients with bilateral

impalpable testis, some clinicians would proceed with a challenge of β -human chorionic gonadotropin (HCG stimulation test), in order to see if a response in the serum testosterone is noted.

In the last decade there has been an increasing emphasis aimed at preoperative localisation of the impalpable testis. The inference is that when the testis is impalpable preoperatively, a fruitless groin exploration may herald a frustrating search for an elusive gonad. Selective gonadal arteriography or venography has been proposed, but these procedures are invasive, require radiation, and may need additional anaesthesia.⁶ Computed tomography, on the other hand, is non-invasive, but is unreliable and also carries the risk of radiation. Other means available that are non-invasive, without exposure to radiation, are ultrasonography and MRI.⁷ Ultrasonography, however, is poor in localising the non-palpable testes, and the value of MRI has not yet been determined.⁶ In contrast, laparoscopy has been found to demonstrate intra-abdominal testes accurately.⁸⁻¹⁰ Laparoscopy can reveal blind ending vessels within the abdomen, and may also visualise the spermatic vessels and vas entering the inguinal ring. These latter findings, however, indicate that inguinal exploration is still needed because often in these cases a testis will be found.

When the undescended testes are palpable then we perform orchidopexy. For those "impalpable testis" (28%), we feel that the majority are palpable but are not found when the child is seen in clinic, as examination of this area is difficult even in the hands of experts. When assessment is made in the outpatient setting it is important that the room is warm and that the child is relaxed and cooperative. Another important examination carried out on a patient with an impalpable testis is an examination under anaesthesia. The cremasteric reflex is dampened during general anaesthesia, so a retractile testis may be palpable under anaesthesia, which is not palpable in the outpatient department. In our practice we noted discrepancies in the palpability of testes referred by the paediatricians (consultants, registrars, senior house officers) and the general practitioners. As most (95%) of these testes were located in the groin on inguinal exploration, we feel that other preoperative investigations (ultrasonography, MRI, computed tomography, and laparoscopy) are not necessary.

Godbole *et al* in a recent study reviewed the place of laparoscopy for the impalpable testis.¹¹ They found that by performing a laparoscopy they would have avoided a negative exploration in 42% of cases. In contrast, the results of our study has shown that performing a laparoscopy routinely in all cases of impalpable testes leads to a number of unnecessary laparoscopies, because most of the impalpable testes (95%) can be localised through an inguinal incision with or without extension. Several recently published studies support our findings.¹²⁻¹⁴

The results of the all Wales survey have shown that orchidopexy is still performed by a

majority of general surgeons, with 38% expressing a special interest in paediatric surgery. Surgeons from all general surgical subspecialties responded, the majority of whom were working in a district general hospital. The age to operate among Welsh surgeons is, however, variable, with over 96% operating on or before the age of 4. This complies with current evidence, which indicates that the optimal time for performing orchidopexy is before the age of 4, and probably as early as 1 year.¹⁵ The problem with early operation is the risk of injury to the spermatic vessels, but this must be weighed against the benefits of early placement of the testis into the scrotum.

There were considerable differences for investigation of the impalpable testis. Forty five per cent of surgeons disregarded any preoperative investigations, and only 5% routinely performed laparoscopy. This is in keeping with our findings that operative exploration is the ultimate definitive study. It is difficult to assess who performed laparoscopy. This is a specialist procedure that requires special equipment (paediatric laparoscope, etc). Not many centres have the technology or the surgical ability to perform such procedures. We suspect it was the paediatric surgeons based at the teaching hospital in Cardiff who stated in our survey that they performed laparoscopy. We must add that a paediatric laproscope was available at our institution but we reserved this procedure for those testes not found on exploration (that is, two cases).

It can be seen that the majority of Welsh surgeons (64%) reviewed their patients for only six months or less. The treatment of patients with undescended testes should not end with their first postoperative visit. These children should be re-evaluated one year after surgery for testis location, size, and viability. Parents must also be made aware of the potential issues of infertility and tumorigenesis.

Conclusion

We conclude that the management of the impalpable testis by groin exploration has the advantage of providing the diagnosis and treatment in the majority of cases. This procedure alone is adequate and very reliable, and thus obviates the need for routine laparoscopy.

We thank the participating consultant surgeons from the Welsh Surgical Society who took their time to complete and return the questionnaire, and for all the comments received. We are also grateful to Miss Nicola Richardson for her assistance in the despatch and collection of the questionnaires.

- 1 Fonkalsrud EW. Current management of the undescended testis. *Semin Pediatr Surg* 1996;5:2-7.
- 2 Scorer CG, Farrington GH. *Congenital deformities of the testis and epididymis*. New York: Appleton Century Crofts, 1971: 136.
- 3 Levitt SB, Kogan SJ, Engel RM, *et al*. The impalpable testis: a rational approach to the management. *J Urol* 1978;120: 515-20.
- 4 Cendron M, Huff DS, Keating MA, *et al*. Anatomical, morphological and volumetric analysis: a review of 759 cases of testicular maldescent. *J Urol* 1993;49:570-3.

Appendix: Paediatric orchidopexy questionnaire

(1) Do you perform orchidopexys for undescended testes in children?

If yes go to question 2

If no go to end of questionnaire

(2) Are you a:

General surgeon/paediatric surgeon/urologist

Have you a special interest in paediatric surgery?

Yes/no

(3) At what age would you perform the operation?

1, 2, 3, 4, 5, 6, 7

(4) What preoperative investigations do you perform for the impalpable testis?

None, ultrasonography, computed tomography, other (please specify)

(5) How long do you follow them up?

6 weeks, 6 months, 1 year, >1 year

(6) Do you perform orchidopexy as a day case?

Never, sometimes, always

(7) Any additional comments?

Thank you

- 5 Moore RG, Peters CA, Bauer SB, *et al*. Laparoscopic evaluation of the nonpalpable testis: a prospective assessment of accuracy. *J Urol* 1994;151:728-31.
- 6 Hinman F Jr. Localisation and operation for non-palpable testes. *Urology* 1987;30:193-8.
- 7 Atlas I, Stone N. Laparoscopic evaluation of cryptorchid testes. *Urology* 1992;40:256-8.
- 8 Lowe DH, Brock WA, Kaplan GW. Laparoscopy for localisation of nonpalpable testes. *J Urol* 1984;131:728-9.
- 9 Weiss RM, Seashore JH. Lararoscopy in the management of the nonpalpable testis. *J Urol* 1987;138:382-4.
- 10 Castilho LN. Laparoscopy for the nonpalpable testis: how to interpret the endoscopic findings. *J Urol* 1990;144:1215-18.
- 11 Godbole PP, Morecroft JA, Mackinnon AE. Laparoscopy for the impalpable testis. *Br J Surg* 1997;84:1430-2.
- 12 Hazebroek FWJ, Molenaar JC. The management of the impalpable testis by surgery alone. *J Urol* 1992;148:629-31.
- 13 Turek PJ, Ewalt DH, Snyder HM, *et al*. The absent cryptorchid testis: surgical findings and their implications for diagnosis and aetiology. *J Urol* 1994;151:718-21.
- 14 Kirsch AJ, Escala J, Duckett JW, *et al*. Surgical management of the nonpalpable testis: the children's hospital of Philadelphia experience. *J Urol* 1998;159:1340-3.
- 15 Mengel W, Zimmerman FA, Hecker WC. Timing of repair for undescended testes. In: Fonkalsrud EW, Mengel W, eds. *The undescended testis*. Chicago, IL: Year Book Medical, 1981: 170.