

REVIEW

Foreign body aspiration: clinical utility of flexible bronchoscopy

O Dikensoy, C Usalan, A Filiz

Postgrad Med J 2002;**78**:399–403

Foreign body aspiration is a worldwide health problem which often results in life threatening complications. More than two thirds of foreign body aspirations occur among children younger than 3 years. Organic materials such as nuts, seeds, and bones are most commonly aspirated. There is a wide range of clinical presentation, and often there is not a reliable witness to supply the clinical history, especially in children. Maintaining a high index of suspicion is therefore necessary for the diagnosis. None of the imaging methods employed in such cases are diagnostic, and bronchoscopy is frequently necessary for the diagnosis as well as the treatment. In adults, removal of the foreign body can be attempted during diagnostic examination with a fiberoptic bronchoscope under local anaesthesia, which may help to avoid any further invasive procedures with more complications. When diagnosis is delayed, complications of a retained foreign body such as unresolving pneumonia, lung abscess, recurrent haemoptysis, and bronchiectasis may necessitate a surgical resection. However, some of the late complications may resolve completely after the retrieval of the foreign body, therefore, a preoperative flexible bronchoscopy should always be considered in suitable cases.

PATHOGENESIS

FBA occurs most commonly among toddlers. There is a bimodal age distribution, with a second peak around age 10. The younger group is more vulnerable because of the lack of adequate dentition and immature swallowing coordination. Additionally, among children of this age, introducing objects into their mouths is their way of exploring the world.⁷ In adults, FBA is caused mostly by the failure of airway protective mechanisms, such as alcohol intoxication, poor dentition, sedative or hypnotic drug use, senility, mental retardation, primary neurological disorders with impairment of swallowing or mental status, trauma with loss of consciousness, seizure, and general anaesthesia.³ Less frequently, accidental aspiration of any material (food parts, small toy parts, etc) in the mouth during laughing, crying, or sneezing can occur in all age groups.

In adults, the right bronchial system is more likely to be obstructed by aspirated foreign bodies. However, the preponderant right sided location of the foreign body is not found in children because the left mainstem bronchus is closer in size to the right mainstem bronchus; in addition, the left mainstem bronchus does not branch at the same acute angle as in adults.⁵ Two thirds of aspirated objects lodge in main stem bronchi rather than in the distal bronchi.^{8,9}

When a foreign body is inhaled into the distal bronchial system without causing an acute obstruction, it may remain silent for a while depending on its nature. Organic materials cause a more severe mucosal inflammation, and granulation tissue may develop in a few hours. Furthermore, objects such as beans, seeds, and corn can absorb water, and with subsequent swelling, partial obstruction can change to total obstruction.¹⁰ However, grass inflorescences also are known to migrate distally and create a chronic inflammation that often requires lung resection.⁶ On the other hand, patients who have inhaled small inorganic materials usually remain asymptomatic for a longer period of time unless total obstruction of a distal airway is caused.¹⁰

CLINICAL PRESENTATION

The severity of the symptoms during the presentation of an aspirated foreign body can vary depending on the site of impact as well as the nature of the foreign body. Even though it is not common, occlusion of the larynx with an aspirated large object can cause an acute and dramatic presentation, and a brief period of choking and gagging may be associated with hoarseness, aphonia, and cyanosis. The Heimlich manoeuvre is recommended for these instances.¹¹ If the

Foreign body aspiration (FBA) is a common problem necessitating prompt recognition and early treatment to minimise the potentially serious and sometimes fatal consequences.¹⁻³ FBA accounted for 7% of all accidental deaths in children under 4 years of age in the US during the year 1986.⁴ About 75% to 85% of all FBAs occur in children younger than 15 years old; however, most are younger than 3 years of age.² Boys are affected more frequently than girls.⁵ Prevention of aspiration is most important and caregivers must be educated to keep small objects away from children. Most of the FBAs in adults are seen in the sixth or seventh decade of life when airway protective mechanisms function inadequately.³ When diagnosis is delayed because of an initially silent foreign body aspiration, complications ranging from recurrent haemoptysis to irreversible damage of the obstructed airways or parenchyma, which often necessitate surgical resection, may develop.⁶

See end of article for authors' affiliations

Correspondence to:
Dr Öner Dikensoy,
Department of Pulmonary
Diseases, Gaziantep
University, School of
Medicine, 27070
Gaziantep, Turkey;
dikensoy@yahoo.com

Submitted
20 November 2001
Accepted 26 March 2002

Box 1: Case report of a long retained tracheobronchial foreign body

A previously healthy, 15 year old boy was admitted to our hospital with a one year history of recurrent productive cough. He gave a history of weight loss (5 kg) for the previous month. For the three months before his admission he had been given several courses of antibiotics, including antituberculous drugs, by a private physician. However, the frequency of the exacerbations had increased without any radiological improvement. His vital signs upon admission were as follows: temperature, 38°C; blood pressure, 110/70 mm Hg; heart rate, 98 beats/min; and respiratory rate, 22 breaths/min. Physical examination revealed localised wheeze and coarse crackles at the right lung base. He had no finger clubbing and examination of the other systems were unremarkable. Haematological investigations revealed that blood cell count and chemical analysis were normal. Chest radiography showed right hilar enlargement, volume reduction of the right hemithorax, and non-homogeneous opacity on the right heart border (fig 1). Computed tomography of the lung demonstrated depletion of the right oblique fissure corresponding with middle lobe atelectasis, and bronchiectatic dilatations along with peribronchial thickness and segmental pneumonic consolidations on the right upper and lower lobes (fig 2). The spirometric tests revealed mild obstruction (forced expiratory volume in one second was 84% of predicted) without significant reversibility after 200 µg of salbutamol inhaler. His sputum was purulent and odourless. Gram stained smear of the sputum revealed numerous polymorphonuclear leucocytes, and a variety of Gram negative rods and Gram positive cocci. The sputum culture grew *Haemophilus influenzae*, pneumococci, and mix oral flora. Purified protein derivative with Mantoux test was 15 mm. Investigation of the sputum was negative for mycobacterial infections. Serum immunoglobulins including IgE and a sweat test performed with pilocarpin were normal. On the basis of the patient's history, physical examination, and radiological features, a retained foreign body was suspected as the cause of recurrent infections and bronchiectasis. Subsequent fiberoptic bronchoscopy revealed an endobronchial foreign body (0.5 × 0.5 × 1 cm, a plastic pen cap in a cylinder shape) obstructing the right intermediate bronchus, which was successfully removed during the same session. The patient's clinical condition improved within 10 days, and one month after the removal of the foreign body, control chest radiography (fig 3) and computed tomography (fig 4) showed complete resolution of the previous middle lobe atelectasis and right hilar enlargement, and also significant resolution of the bronchiectatic dilatations.

foreign body passes through the vocal cords into the subglottic or tracheal region, inspiratory stridor with bouts of coughing may be noted. However, further travelling of the foreign bodies into the bronchi leads to a resolution of these symptoms, and a relatively asymptomatic period may begin. Cough, wheezing, and decreased breath sounds are the most common acute symptoms of FBA, and such new symptoms, especially in children, should always suggest the possibility of a foreign body.¹² It has been reported that about 50% of patients with FBA do not have a contributing history, and 20% of all children are given medication for other disorders for longer than a month before diagnosis.¹³⁻¹⁵ In the presence of long standing aspirated foreign bodies, recurrent haemoptysis, and symptoms consistent with recurrent bronchitis, pneu-

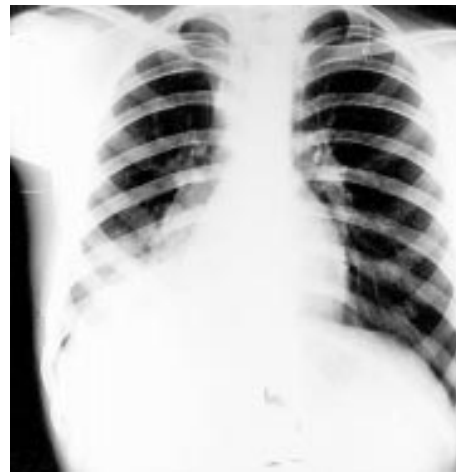

Figure 1 Chest radiograph showing right hilar enlargement, volume reduction of the right hemithorax, and non-homogeneous opacity on the right heart border.

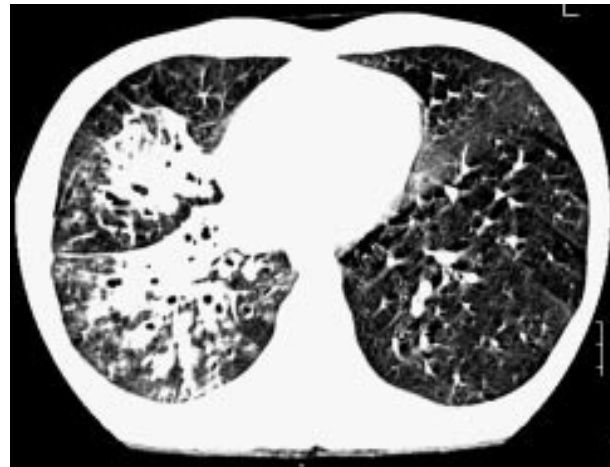


Figure 2 Computed tomogram of the thorax demonstrating depletion of the right oblique fissure corresponding with middle lobe atelectasis, and bronchiectatic dilatations along with peribronchial thickness and segmental pneumonic consolidations on the right upper and lower lobes.

monia, and bronchiectasis, such as chronic productive/unproductive cough, and wheezing, may exist.^{6 16 17}

The most common findings in physical examination of FBA cases include tachypnoea, stridor, unilateral or bilateral decreased breath sounds, localised wheezing and/or crackles, and sometimes fever.⁴ Unusual presentations consist of pneumomediastinum, subcutaneous emphysema, and/or pneumothorax.⁵ Tracheobronchitis, asthma, recurrent pneumonia, and tuberculosis are the most common diagnoses considered in the differential diagnosis.^{13 18}

TYPES OF FOREIGN BODIES

Aspirated foreign bodies can be classified into two categories, organic and inorganic. Most of the aspirated foreign bodies are organic materials, such as nuts and seeds in children, and food and bones in adults. The most common type of inorganic aspirated substances in children are beads, coins, pins, small parts of various toys, and small parts of school equipment such as pen caps. In adults, dental prostheses, pills, and tops from beverage cans are some of the reported inorganic substances that were extracted from airways.¹⁹ Aspiration of pills in all age groups is also common and can induce severe bronchial inflammation.²⁰ Lifestyle in adults may predispose to unusual

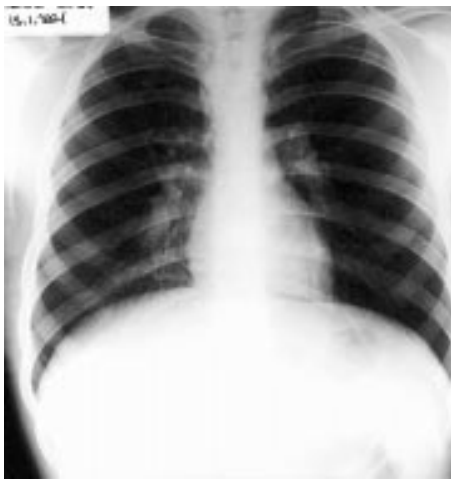

Figure 3 Control chest radiograph showing complete resolution of the previous middle lobe atelectasis, and also right hilar enlargement.

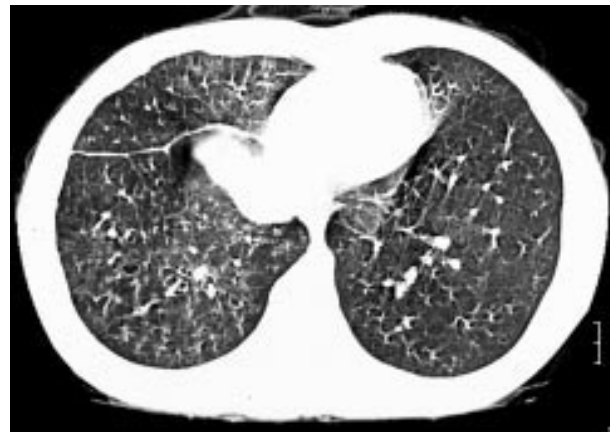

Figure 4 Control computed tomogram of the thorax demonstrating the complete resolution of the previous middle lobe atelectasis and pneumonic consolidation, as well as significant resolution of the bronchiectatic dilatations in the right lung.

Box 2: Epidemiology and pathogenesis

- FBA accounted for 7% of all accidental deaths in children under 4 years of age in the US.
- FBA occurs most commonly in toddlers; however, there is a bimodal age distribution with a second peak around age 10.
- In infants, the lack of adequate dentition and immature swallowing coordination makes them vulnerable.
- Prevention in children and toddlers is most important.
- In adults, FBA is mostly caused by the failure of airway protective mechanisms, such as alcohol intoxication, poor dentition, sedative or hypnotic drug use, senility, mental retardation, primary neurological disorders with impairment of swallowing or mental status, trauma with loss of consciousness, seizure, and general anaesthesia.
- In adults, the right bronchial system is more likely to be obstructed by aspirated foreign bodies; however, the preponderance of the right side is not found in children.
- Two thirds of the objects lodge in the main stem bronchi rather than the distal bronchi.
- Organic material cause a more severe mucosal inflammation, and granulation tissue may develop in a few hours.
- Objects, such as beans, seeds, and corn can absorb water, and with subsequent swelling partial obstruction can change to total obstruction.

types of aspiration. For instance, turban pin aspiration was reported in Muslim females who held the pin between their lips while attaching their head scarf.²¹

DIAGNOSTIC EVALUATION

Although most of the foreign bodies are radiolucent, a standard radiological work-up, including a posteroanterior and a lateral chest film, and a lateral soft tissue neck radiograph should be performed in cases with suspected FBA.¹⁹ One should remember that chest radiographs may be normal in the first 24 hours, and initial radiological findings which show unilateral or segmental hyperaeration can become visibly better on either expiratory radiographs or fluoroscopic examination of the lungs.²² Obstructive emphysema, especially when associated with ipsilateral decreased breath sounds, has a very high positive predictive value.⁷ Additionally, the presence of radiological findings including atelectasis, pulmonary infiltrates, and mediastinal shift, may be suggestive of a FBA.²² Other imaging tests are seldom reported to be of further help. Frequently, flexible/rigid bronchoscopy is required for the diagnosis of FBA.^{3-9 13}

Box 3: Clinical presentation

- The severity of symptoms due to an aspirated foreign body can vary depending on the site of the impaction.
- *Occlusion at larynx*—choking and gagging may be associated with hoarseness, aphonia, and cyanosis, and sudden death can occur.
- *Occlusion at trachea*—inspiratory stridor with bouts of coughing may be noted.
- *Occlusion at bronchi*—cough, wheezing, haemoptysis, dyspnoea, chest pain, and decreased breath sounds are the most common clinical presentation. These could be recurrent despite medical treatment.

Box 4: Diagnostic evaluation

- Although 90% of the foreign bodies are radiolucent, a standard radiological work-up including a posteroanterior and a lateral chest film, and a lateral soft tissue neck radiograph should be done.
- Chest radiographs may be normal in the first 24 hours.
- Initial radiological findings that are unilateral or segmental hyperaeration can be better seen on expiratory radiographs.
- The presence of atelectasis, air trapping, pulmonary infiltrates, and mediastinal shift on the chest radiographs may be suggestive of a FBA.
- Other imaging tests are seldom of further help.
- Flexible/rigid bronchoscopy is frequently required for diagnosis to be certain.

FOREIGN BODY REMOVAL AND UTILITY OF FLEXIBLE BRONCHOSCOPY

At present, foreign body removal usually relies on bronchoscopic techniques. The first report of foreign body removal with a rigid bronchoscope was published in 1897, and Chevalier Jackson in 1936 reported the successful removal of bronchial foreign bodies with his new bronchoscopic system.^{23 24} The flexible fiberoptic bronchoscope was developed in 1968 by Ikeda, and the initial reports of foreign body removal with flexible bronchoscope was published in the 1970s.^{5 25 26} Subsequently, animal studies showed the removal of various foreign bodies from the animals' bronchial system using newly developed grasping forceps through a fiberoptic bronchoscope.²⁷ Since then, a number of studies on the removal of foreign bodies with flexible bronchoscope have been published (table 1).^{3 28-32}

Table 1 Case series of bronchofibreoptic foreign body removal

	No	Success (%)
Cunanan ²⁸	300	89
Lan <i>et al</i> ²⁹	33	97
Limper and Prakash ³⁰	23	61
Chen <i>et al</i> ⁶	43	74
Debeljak <i>et al</i> ¹	58	97
Total	457	83.6

Despite the advances in optical technology, proper training and experience is crucial to optimise the outcome and minimise the risk of complications in tracheobronchial foreign body removal by a bronchoscope.

Although the rigid bronchoscope is still considered as the safest instrument in most paediatric centres, there is no doubt that the fibreoptic bronchoscope is the preferred tool for the initial diagnosis of a foreign body in adult patients.^{2 19 32} At present flexible bronchoscopes in different sizes are available for different age groups. The bronchoscopes with 4.9 mm outer diameter and a 2.2 mm diameter working channel are used in patients older than 12 years of age. Although bronchoscopes with 3.5 mm or 2.7 mm outer diameter with 1.2 mm diameter working channels are available for younger patients, using the flexible bronchoscope under local anaesthesia in a very young patient is a very difficult procedure. In such cases, rigid bronchoscopy under general anaesthesia is probably the safest procedure. Using a short acting agent such as propofol for general anaesthesia may increase the safety by allowing jet ventilation or manually assisted spontaneous ventilation since the procedure rarely exceeds 10 minutes. In fact, a rigid bronchoscope provides greater access to the subglottic airways, ensuring correct oxygenation and easy passage of the telescope and grasping forceps during the extraction of a large foreign body. Furthermore, a rigid bronchoscope allows a very efficient airway suctioning in case of a massive bleed.³

In adult patients, however, a flexible bronchoscope has many advantages over a rigid bronchoscope in the initial diagnosis of a foreign body. First, flexible bronchoscopy is a relatively easy and a safe procedure in experienced hands. Second, with the use of a flexible bronchoscope under local anaesthesia for the visualisation of airways, removal of the foreign body can be attempted and avoids the added cost, risk, and morbidity of a secondary invasive procedure such as rigid bronchoscopy under general anaesthesia. Third, fibreoptic bronchoscopy is superior to rigid bronchoscopy in cases of distally wedged foreign bodies, in mechanically ventilated patients or in cases of spine, jaw, or skull fractures preventing rigid bronchoscope manipulation.³⁰ The success rate of the flexible bronchoscope in removing foreign bodies can be as high as 100% in experienced hands when a careful case selection is made.^{5 33}

Another important advantage of fibreoptic bronchoscopy applies when severe complications occur due to a long retained foreign body. Delayed complications associated with a retained foreign body include unresolving pneumonia, lung abscess, recurrent haemoptysis, lung fibrosis, obstructive emphysema, and bronchiectasis.^{6 34} It is essential to consider FBA in the differential diagnosis of the above pathologies as removal of the foreign body by a flexible bronchoscope may provide a complete resolution without necessitating a more invasive procedure.^{34 35} Bronchiectasis, as in our case, is one of the most important complications of a long retained foreign body that may necessitate a surgical resection in cases with recurrent infections. Bronchiectasis may develop many years after unrecognised aspiration of a foreign body. Such postobstructive bronchiectasis is a localised rather than a diffuse process.³⁵ Obstructive emphysema, atelectasis, and infection precede the development

Box 5: Foreign body removal

- Bronchoscopy is the preferred tool in the further evaluation of a suspected foreign body.
- A rigid bronchoscopy is still considered the safest instrument in most paediatric centres.
- In adults, flexible bronchoscope is superior to rigid bronchoscope and should be the preferred instrument for the diagnosis and the removal of airway foreign bodies in suitable cases.
- Proper training and experience is crucial to optimising the outcome and minimising the risk of complications in tracheobronchial foreign body removal.

Box 6: Delayed complications and clinical utility of flexible bronchoscopy

- Obstructive emphysema, atelectasis, and infection due to a retained tracheobronchial foreign body precede the development of chronic inflammation and bronchiectasis.
- Bronchiectasis is one of the most important complication of a long retained foreign body and may necessitates a surgical resection in cases with recurrent infections.
- Such postobstructive bronchiectasis is a localised rather than a diffuse process.
- Bronchiectasis may develop many years after unrecognised aspiration of a foreign body.
- Although surgery is the only curative treatment of bronchiectasis, there are reports in the literature suggesting the resolution of bronchiectasis and/or bronchial dilatation secondary to FBA after extracting a long standing retained foreign body.
- Flexible bronchoscopy, therefore, should always be considered in cases with localised bronchiectasis or unresolving pneumonia for the possibility of a long retained foreign body to prevent patients from an unnecessary surgical procedure.

of chronic inflammation and ensuing bronchiectasis. Bronchiectasis can develop in animals two to eight weeks after introduction of sterile foreign bodies into the bronchial tree.³⁶ The exact duration required for the development of bronchiectasis after obstruction in humans is not known. Although medical treatment is sufficient in most of the cases, surgery is the only curative treatment of bronchiectasis. However, there are reports in the literature suggesting the resolution of bronchiectasis, scar changes, or atelectasis secondary to FBA after the extracting of a long standing retained foreign body. Ernst and Mahmud and subsequently Mansour *et al* described similar cases, with bronchiectasis due to FBA in which complete resolution were provided by the removal of foreign bodies.^{35 37} Pogorzelski and Zebra described a 13 year old girl with long lasting recurrent pneumonia the main cause of which was a foreign body lodged in the intermediate bronchus.³⁴ The authors reported that the bronchoscopy revealed scars narrowing the intermediate bronchus, and the scar changes resolved after forming removal of the foreign body. Khatibi *et al* reported a case of middle lobe syndrome due to FBA in whom removal of the foreign body provided a significant improvement in the patients condition.³⁸

CONCLUSION

FBA is a common problem occurring mostly in children under 3 years old. In adult patients fibreoptic bronchoscopy is a safe procedure for the initial diagnosis of foreign body, which avoids unnecessary general anaesthesia, and reduces the hospital costs. The success rate of the flexible bronchoscope in removing foreign bodies can be as high as 100% in experienced hands. Even just localisation of the foreign body

Questions (answers at end of paper)

1. Which age groups are the most vulnerable for the foreign body aspiration?
2. What a standard radiological work-up should be included for the diagnosis of a suspected foreign body?
3. What is the preferred procedure in the diagnosis of an aspirated foreign body?
4. What are the advantages of a flexible bronchoscope over a rigid bronchoscope in the diagnosis of an aspirated foreign body?
5. What are the late complications of a retained foreign body?

during the initial fiberoptic bronchoscopy allows subsequent rigid bronchoscopy to be shorter in duration with fewer complications. FBA should always be considered in the aetiology of recurrent pulmonary infections or haemoptysis, lung abscess, middle lobe syndrome, fibrotic changes such as scar formation, and bronchiectasis, all of which may necessitate a surgical resection. Removal of the foreign body in such cases can achieve the resolution of the parenchymal or bronchial pathology, and prevent unnecessary surgery. Therefore, bronchoscopy should always be considered in such cases before surgery.

Authors' affiliations

O Dikensoy, A Filiz, Department of Pulmonary Diseases, Gaziantep University, School of Medicine, Gaziantep, Turkey
C Usalan, Department of Medicine, Division of Nephrology

REFERENCES

- 1 **National safety council**. *Accident facts*. Chicago: National Safety Council Press, 1980: 7.
- 2 **Baharloo F**, Veyckemans F, Francis C, *et al*. Tracheobronchial foreign bodies: presentation and management in children and adults. *Chest* 1999;**115**:1357–62.
- 3 **Chen CH**, Lai CL, Tsai TT, *et al*. Foreign body aspiration into the lower airways in Chinese adults. *Chest* 1997;**112**:129–33.
- 4 **Manto PC**, Tuggle DW, Tunell WP. An appropriate negative bronchoscopy rate in suspected foreign body aspiration. *Am J Surg* 1989;**158**:622–4.
- 5 **Marquette CH**, Martinot A. Foreign body removal in adults and children. In: Bolliger CT, ed. *Interventional bronchoscopy*. Basel: S Karger AG, 2000: 96–107.
- 6 **Maayan C**, Avital A, Elpeleg ON, *et al*. Complications following out head aspiration. *Pediatr Pulmonol* 1993;**15**:52–4.
- 7 **Lemberg PS**, Darrow DH, Holinger LD. Aerodigestive tract foreign bodies in the older child and adolescent. *Ann Otol Rhinol Laryngol* 1996;**105**:267–71.
- 8 **Kosloske AM**. Bronchoscopic extraction of aspirated foreign bodies in children. *Am J Dis Child* 1982;**136**:924–7.
- 9 **Brkic F**, Delibegovic-Dedic S, Hajdarovic D. Bronchoscopic removal of foreign bodies from children in Bosnia and Herzegovina: experience with 230 patients. *Int J Pediatr Otorhinolaryngol* 2001;**28**:193–6.
- 10 **Freiman MA**, McMurray JS. Unique presentation of a bronchial foreign body in an asymptomatic child. *Ann Otol Rhinol Laryngol* 2001;**110**:495–7.
- 11 **Heimlich HJ**. A life-saving maneuver to prevent food-choking. *JAMA* 1975;**234**:398–401.
- 12 **Papsin B**, Friedberg J. Aerodigestive-tract foreign bodies in children: pitfalls in the management. *J Otolaryngol* 1994;**23**:102–8.
- 13 **Friedman EM**. Tracheobronchial foreign bodies. *Otolaryngol Clin North Am* 2000;**33**:179–85.
- 14 **Emir H**, Tekant G, Besik C, *et al*. Bronchoscopic removal of tracheobronchial foreign bodies: value of patient history. *Pediatr Surg Int* 2001;**17**:85–7.
- 15 **Cohen SR**, Lewis FH. The emergency management of caustic ingestions. *Emerg Med Clin North Am* 1984;**2**:77–86.
- 16 **Martinot A**, Closset M, Marquette CH, *et al*. Indications for flexible versus rigid bronchoscopy in children with suspected foreign body aspiration. *Am J Respir Crit Care Med* 1997;**155**:1676–9.
- 17 **Pasaoglu I**, Dogan R, Demircin M, *et al*. Bronchoscopic removal of foreign bodies in children: retrospective analysis of 822 cases. *Thorac Cardiovasc Surg* 1991;**39**:95–8.
- 18 **Kalyoncu F**, Baris B, Sahin AA, *et al*. Endobronchial tuberculosis. A report on 15 cases. *S Afr Med J* 1989;**15**:395–6.
- 19 **Salcedo L**. Foreign body aspiration. *Anesthesiol Clin North Am* 1998;**16**:885–92.
- 20 **Johnson DR**, Yew D. Aspiration of nortriptyline. *Am J Emerg Med* 1994;**12**:337–8.
- 21 **Kaptanoglu M**, Dogan K, Onen A, *et al*. Turban pin aspiration: a potential for young Islamic girls. *Int J Pediatr Otorhinolaryngol* 1999;**48**:131–5.
- 22 **Mu LC**, Sun DQ, He P. Radiological diagnosis of aspirated foreign bodies in children: review of 343 cases. *J Laryngol Otol* 1990;**104**:778–82.
- 23 **Killian G**. Meeting of the Society of Physicians of Freiburg Dec 17, 1897. *Munch Med Wochenschr* 1989;**45**:378.
- 24 **Jackson C**. *Diseases of the air and food passages of foreign body origin*. Philadelphia: W B Saunders, 1936.
- 25 **Barrett CR**, Vecchione JJ, Bell AL. Flexible fiberoptic bronchoscopy for airway management during acute respiratory failure. *Am Rev Respir Dis* 1974;**109**:429–34.
- 26 **Ikeda S**. *Atlas of flexible bronchofiberoscopy*. Baltimore: University Park Press, 1974: 220.
- 27 **Zavala DC**, Rhodes ML. Experimental removal of foreign bodies by fiberoptic bronchoscopy. *Am Rev Respir Dis* 1974;**110**:357–60.
- 28 **Cunanan OS**. The flexible fiberoptic bronchoscope in foreign body removal. Experience in 300 cases. *Chest* 1978;**73**:725–6.
- 29 **Lan RS**, Lee CH, Chiang YC, *et al*. Use of fiberoptic bronchoscopy to retrieve bronchial foreign bodies in adults. *Am Rev Respir Dis* 1989;**140**:1734–7.
- 30 **Limper AH**, Prakash UB. Tracheobronchial foreign bodies in adults. *Ann Intern Med* 1990;**112**:604–9.
- 31 **Debeljak A**, Sorli J, Music E, *et al*. Bronchoscopic removal of foreign bodies in adults: experience with 62 patients from 1974–1998. *Eur Respir J* 1999;**14**:792–5.
- 32 **Rafanan AL**, Mehta AC. Adult airway foreign body removal. What's new? *Clin Chest Med* 2001;**22**:319–30.
- 33 **Clark PT**, Williams TJ, Teichtahl H, *et al*. Removal of proximal and peripheral endobronchial foreign bodies with the flexible fiberoptic bronchoscope. *Anaesth Intensive Care* 1989;**17**:205–8.
- 34 **Pogorzelski A**, Zembrak J. Scar changes in the bronchus caused by a foreign body. *Wiad Lek* 1995;**48**:140–2.
- 35 **Mansour Y**, Beck R, Danino J, *et al*. Resolution of severe bronchiectasis after removal of long-standing retained foreign body. *Pediatr Pulmonol* 1998;**25**:130–2.
- 36 **Morton N**, Swartz MN. Bronchiectasis. In: Fishman AP, Elias JA, Fishman JA, *et al*, eds. *Fishman's pulmonary diseases and disorders*. 3rd ed. Philadelphia: McGraw-Hill, 1998: 2046–70.
- 37 **Ernst KD**, Mahmud F. Reversible cystic dilatation of distal airways due to foreign body. *South Med J* 1994;**87**:404–6.
- 38 **Khatibi S**, Rouzaud P, Lauque D, *et al*. Recurrent pneumopathy of the middle lobe. *Rev Pneumol Clin* 1999;**55**:187–8.

ANSWERS

1. About 75% to 85% of all FBAs occur in children younger than 15 years old; however, most of them are younger than 3 years. Failure of airway protective mechanisms is the most frequent reason of FBAs in adults which is seen mostly in the sixth or seventh decade of life.
2. A standard radiological work-up should include a posteroanterior and a lateral chest film, and a lateral soft tissue neck radiograph in cases with suspected FBA. One should also remember that chest radiographs may be normal in the first 24 hours, and initial radiological findings which show unilateral or segmental hyperaeration can be more visible on either expiratory radiographs or fluoroscopic examination of the lungs.
3. Visualisation of the tracheobronchial tree with flexible/rigid bronchoscopy is the preferred procedure in the diagnosis of FBA.
4. With the use of a flexible bronchoscope under local anaesthesia for the visualisation of airways, removal of the foreign body can be attempted to avoid the added cost, risk, and morbidity of a second procedure: rigid bronchoscopy under general anaesthesia. Furthermore, fiberoptic bronchoscopy is superior to rigid bronchoscopy in cases of distally wedged foreign bodies, in mechanically ventilated patients or in cases of spine, jaw, or skull fractures preventing rigid bronchoscope manipulation.
5. Unresolving pneumonia, lung abscess, recurrent haemoptysis, lung fibrosis, obstructive emphysema, middle lobe syndrome, and bronchiectasis are the reported late complications of a retained tracheobronchial foreign body.