

CASE REPORT

Thallium poisoning: emphasis on early diagnosis and response to haemodialysis

U K Misra, J Kalita, R K Yadav, P Ranjan

Postgrad Med J 2003;**79**:103–105

Thallium poisoning is known for its diverse manifestations and these can delay the diagnosis if a clear history of poisoning is not forthcoming. A 42 year old man presented on the third day of illness with flaccid quadriparesis and paresthesia, which were confused with Guillain-Barré syndrome. Because of associated loose motions, skin lesions, and liver and kidney dysfunction arsenic poisoning was considered. In the second week he developed ophthalmoplegia, nystagmus, and neck tremor and later developed alopecia, and thallium poisoning was suspected. His serum thallium level on the 18th day of illness was 40 980 µg/ml. He was subjected to haemodialysis, potassium supplementation, laxatives, and B complex supplementation. He showed significant improvement after haemodialysis and at three months he was able to walk with support. At six months of follow up he was independent for activities of daily living. Severe paresthesia, ophthalmoplegia, cerebellar and extrapyramidal signs, and alopecia are highly suggestive of thallium poisoning. Haemodialysis may be effective even in the third week of poisoning.

Thallium is highly reactive heavy metal, which exists as monovalent and trivalent ionic forms. It is used in rodenticides, for optical lenses, in green coloured fireworks, semiconductors, low temperature thermometers, and in imitation jewellery. Many thallium salts are colourless, odourless, and tasteless hence it is a favoured homicidal poison. Soluble thallium salts such as sulphate, acetate, and carbonate have higher toxicity and their fatal dose is 10–15 mg/kg. Thallium poisoning commonly occurs after oral ingestion but can also occur after inhalation of contaminated dust or after dermal absorption.¹ Thallium is a protoplasmic poison and may disrupt the sulphhydryl group on the mitochondrial membrane and interferes with the functioning of sodium-potassium ATPase for which thallium has 10 times greater affinity than potassium. The clinical picture of thallium poisoning is non-specific and variable, depending on the dose and route of administration. In the early stage, thallium poisoning is managed by gastric lavage, laxatives, forced diuresis, haemodialysis, and Prussian blue.^{1, 2} We report a patient with thallium poisoning who was referred to us with suspected Guillain-Barré syndrome; he responded well to haemodialysis in the third week. We highlight the distinguishing features of thallium poisoning, especially in the early stage of poisoning, and the utility of haemodialysis in management.

CASE REPORT

A 42 year old businessman was referred to our neurology unit recently with suspected Guillain-Barré syndrome. He had noticed severe paresthesia all over his body and abdominal cramps for three days. He also had pain in his abdomen and a

few loose stools. The next day he developed progressive walking difficulties and he was unable to stand on the day of admission to our institute. There was no history of preceding fever, vaccination, diabetes, or hypertension. He occasionally smoked and consumed alcohol. One day before these symptoms, he had been to a party and noted a peculiar taste in a sweet offered to him.

On the fourth day of illness, the patient appeared anxious and was rather slow in his responses. He had pronounced hyperaesthesia and the touch of a bedsheet and even a slight breeze would hurt him. His pulse was 90 beats/min, regular; blood pressure 140/90 mm Hg without any postural drop. Examination of his abdomen revealed diffuse tenderness. Respiratory and cardiovascular examinations gave normal results. On the fifth day, he developed severe constipation and swallowing difficulties because of severe stomatitis; this was associated with nausea and vomiting. On the sixth day, his paresthesiae worsened and he also complained of retrosternal chest pain and body ache and on eighth day he became apathetic and drowsy. On the 13th day of illness yellowish acneform lesions on his forehead and cheek were noted (fig 1). There were ichthyotic lesions on the dorsum of his feet and hand and hyperkeratotic lesions on soles and palms (fig 2). He also developed ptosis, visual impairment, and rotatory nystagmus. On the 18th day hair loss was noted and on 20th day he had prominent head and tongue tremor. On the 18th day, the diagnosis of thallium poisoning was suspected.

On admission (on the fourth day of illness) his haemoglobin was 161 g/l, blood counts were normal, blood glucose 5 mmol/l, serum sodium 135 mmol/l, serum potassium 4.3 mmol/l, serum bilirubin 44.2 µmol/l, alanine aminotransferase 348 U/l, aspartate aminotransferase 135 U/l, creatinine 221.66 µmol/l, and blood urea nitrogen 17.75 mmol/l. Cerebrospinal fluid showed protein of 0.6 g/l, 5 lymphocytes/µl, and glucose 3.3 mmol/l. The electroencephalogram was normal. A plain radiograph of the chest and cranial and spinal magnetic resonance imaging were also normal. Nerve conduction studies were normal except peroneal motor conduction which were unrecordable bilaterally. Sensory nerve action potential of median, ulnar, and sural nerves were normal bilaterally. Electromyography after three weeks of illness revealed fibrillations, sharp waves, and complex repetitive discharges in tibialis anterior, gastrocnemius, and peroneus longus with poor recruitment of motor unit potential. Electromyography of abductor pollicis brevis, biceps, deltoid, and vastus medialis was normal. On the 18th day of illness the results of the thallium analyses were received. Thallium level in his blood was 40 980 µg/ml (normal <10 µg/ml) and in urine was 608 µg/ml (normal 10 µg/ml). Sural nerve biopsy on the 40th day of illness revealed loss of axons and active axonal degradations. There was increased endoneurial collagen and endoneurial vessels were thickened. There was increased inflammatory cell infiltration. Kulchitsky Pal stain showed associated demyelination. A few remyelinating fibres were also seen.

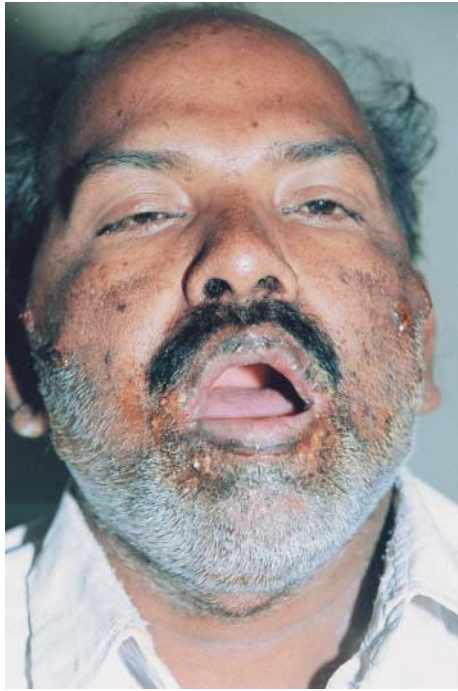

Figure 1 Patient with infected acneform lesions, lip oedema, and angular stomatitis on day 13th of illness.

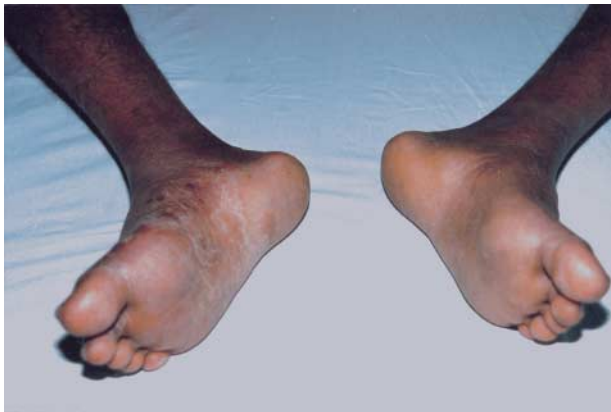

Figure 2 Keratosis of soles on day 13th of illness.

Treatment and course

After confirming the diagnosis of thallium poisoning, the patient was subjected to haemodialysis. He underwent seven dialysis sessions, each lasting for 4–5 hours daily. He also received 20 mmol potassium chloride thrice daily, laxatives, and intravenous vitamin B complex. After the first dialysis, his consciousness improved and he responded to verbal commands. After the third dialysis, ptosis and nystagmus improved and after the seventh dialysis he was fully conscious and neck and trunk tremor subsided. After the seventh dialysis on the 28th day of illness he developed high fever with leucocytosis ($17.0 \times 10^9/l$) hence the haemodialysis was stopped. By this time his skin lesions on face had improved and his serum bilirubin, transaminase, and serum creatinine also normalised. He had prominent Mee's lines. On the 36th day of illness the patient developed severe pain in his abdomen and constipation due to an obstructed inguinal hernia for which herniorrhaphy was done under general anaesthesia. After herniorrhaphy his abdominal symptoms improved. By day 45 he was almost completely bald (fig 3), withdrawn, and depressed but talked appropriately with a nasal twang. He had

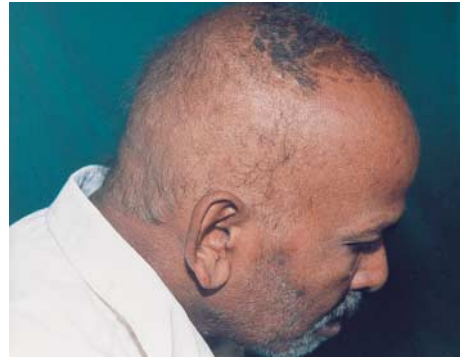


Figure 3 Alopecia on day 45th of illness.

flaccid quadriparesis with muscle power III–IV, which was more marked distally and in the lower limbs. He had loss of pinprick sensations in glove and stocking distribution; joint position and vibration sense were also absent in the lower limbs. Ankle reflex was lost bilaterally. He had profound dysautonomia. The blood pressure from supine to sitting declined by 30/20 mm Hg; sinus arrhythmia was absent. Blood pressure did not rise on handgrip or cold pressor test. The patient was discharged on the 50th day with alopecia and peripheral neuropathy as prominent sequelae. On three months of follow up the patient was able to walk with support. Hair had appeared on his scalp. The limb power was grade IV, sensations were normal and ankle reflex absent, although knee reflexes were normal and plantar response flexor. Skin appeared normal. The other sequelae at this stage were nasal speech and visual impairment (6/60 bilaterally), though fundus was normal. P100 visual evoked potential was 140 and 138 ms on right and left side respectively. At six months of follow up the patient was independent for daily activities, although his visual impairment and bilateral absence of ankle reflex persisted.

DISCUSSION

Thallium poisoning has a distinctive clinical picture comprising skin manifestations, alopecia, neuropathy, and other systemic manifestations. The typical clinical picture unfolds by 2–3 weeks of acute poisoning. By then, precious time for therapeutic intervention is lost. In the early stage, thallium poisoning simulates Guillain-Barré syndrome, porphyria, myocardial infarction, diabetic neuropathy, arsenic poisoning, lead poisoning, systemic lupus erythematosus, carbon monoxide poisoning, and organophosphate poisoning.¹ Our patient was also suspected of having Guillain-Barré syndrome but severe dysaesthesia, associated nausea, vomiting, severe constipation, and behavioural abnormalities raised doubt about this diagnosis.

Peripheral neuropathy is quite characteristic and an early feature of thallium poisoning. It is consistent with distal symmetrical axonopathy with secondary loss of myelin. In our patient the nerve conduction studies were normal except peroneal motor conduction velocity, which was unrecordable. In these patients, small fibre involvement cannot be excluded and this could account for preservation of sensory conduction velocity at the same time resulting in the severe dysaesthesia. Histopathological findings in thallium neuropathy have revealed axonal degeneration with secondary demyelination.³ Nerve biopsy in our patient also revealed axonal degenerations. In thallium poisoning cranial neuropathy resulting in ptosis, external ophthalmoplegia, dysautonomia due to vagal nerve involvement, facial weakness due to seventh cranial nerve palsy, and optic neuropathy have been reported. Our patient had severe visual impairment and prolonged P100 latency of visual evoked potential due to retrobulbar neuritis. In one study up to 25% of patients with severe thallium poisoning have been reported to develop optic neuropathy.⁴

Severe dermatitis, stomatitis, and neuropathy in our patient was consistent with riboflavin deficiency. Skin lesions similar to thallium poisoning have been reported in riboflavin deficiency.³ Thallium interferes with riboflavin homeostasis, forming an insoluble complex and intravascular sequestration of riboflavin.⁶ In our patient hyperkeratotic lesions on palms and soles, ichthyotic lesions on his legs, and acneform lesions on his face were apparent by the end of the second week and alopecia appeared on the 18th day. Interaction between the sulphhydryl group and thallium result in abnormality in form and function of structural proteins; this accounts for disturbances of hair growth, alopecia, growth of nails, and Mee's lines.⁷

The presence of gastrointestinal, skin, liver, kidney, and peripheral nerve dysfunction in our patient at one stage simulated arsenic poisoning. Alopecia is quite characteristic of thallium poisoning and manifests during the second to third week but can also occur in arsenic poisoning.⁸ Mee's lines, keratosis, axonal neuropathy, and a variable degree of encephalopathy can occur in both thallium and arsenic poisoning but the presence of severe constipation, ptosis, nystagmus, and variety of movement disorders such as masking of the face and tremor of head and trunk were suggestive of thallium poisoning in our patient. The involvement of basal ganglia in thallium poisoning can result in tremor, chorea, and extrapyramidal motor disturbances and rigidity.⁷ Such central nervous system abnormalities are not reported in arsenic poisoning.

In our patient, the diagnosis of thallium poisoning was possible in the third week. By this time the initial therapeutic measures such as gastric lavage by activated charcoal, forced diuresis, and Prussian blue are not helpful in eliminating thallium. In thallium poisoning three phases have been described: first is the phase of intravascular distribution which lasts for four hours. The second phase of central nervous system distribution lasts for 4–48 hours and the third phase is the elimination phase, which begins 24 hours after poisoning. Thallium elimination mainly occurs through large and small bowel, although there is some enteric absorption as well.⁹ Renal excretion also mirrors total body thallium and can be enhanced by forced diuresis. Prussian blue is considered as specific antidote and chelates the intestinal thallium. Potassium supplementation, B complex administration, and haemodialysis are also useful measures. We started haemodialysis in the third week. Although some improvement in consciousness occurred after the first dialysis, after seven cycles of haemodialysis there was further clinical improvement in consciousness, skin, neurological manifestations, liver and kidney function parameters. Haemodialysis has been described to be more effective than forced diuresis and has been found to be useful up to 12 days after poisoning.¹⁰ Non-availability of Prussian blue and lack of Food and Drug Administration approval have been problems in certain countries.¹¹ Haemodialysis in critically ill patients, especially those with renal and cardiac dysfunction, may be effective in the third week even though benefit has been reported in the first 48 hours only.¹

Learning points

- In a patient with neuropathy severe dysaesthesia, constipation and alopecia point towards thallium poisoning.
- Haemodialysis is useful even in the third week of illness.

Our patient also showed remarkable improvement after haemodialysis.

The wide clinical spectrum of thallium poisoning makes it difficult to suspect in its early stage especially in the absence of a reliable history. Dysaesthesiae, neuropathies, and cranial nerve palsy (ptosis, ophthalmoplegia, nasal speech, dysautonomia) and extrapyramidal features are highly suggestive of thallium poisoning. The characteristic alopecia manifests later. Haemodialysis, forced diuresis, laxatives, B complex, and potassium supplementation are invaluable in the management of thallium poisoning.

ACKNOWLEDGEMENT

We acknowledge Rakesh Kumar Nigam for secretarial help.

Authors' affiliations

U K Misra, J Kalita, R K Yadav, P Ranjan, Department of Neurology, Sanjay Gandhi Post Graduate Institute of Medical Sciences, Lucknow, India,

Correspondence to: Dr J Kalita, Department of Neurology, Sanjay Gandhi PGIMS, Raebareilly Road, Lucknow 226014, India; jkalita@sgpgi.ac.in

Submitted 12 July 2002
Accepted 16 October 2002

REFERENCES

- 1 Moore D, House I, Dixon A. Thallium poisoning. Diagnosis may be elusive but alopecia is the clue. *BMJ* 1993;**306**:1527–9.
- 2 Wainwright AP, Kux WJ, House IM, et al. Clinical features and therapy of acute thallium poisoning. *Q J Med* 1988;**69**:939–44.
- 3 Dumitru D, Kalantri A. Electrophysiologic investigation of thallium poisoning. *Muscle Nerve* 1990;**13**:433–7.
- 4 Bohringer HR. Thallium poisoning. (*Praxis* 1952: 1092; quoted by Moeschlin S.) *Toxicology* 1980;**17**:133–46.
- 5 Grisham CM, Gupta RK, Barnett RE, et al. Thallium-205 nuclear relation and kinetic studies of sodium and potassium ion activated triphosphatase. *J Biol Chem* 1974;**294**:6738–44.
- 6 Hughes MN, Man WK, Whaler BC. The toxicity of thallium (II) to cardiac and skeletal muscle. *Chem Biol Interact* 1978;**23**:85–97.
- 7 Prick JJG. Thallium poisoning. Vinken PJ, Bruyn GW, eds. *Handbook of clinical neurology*. Vol 36. Amsterdam: North Holland Publishing, 1979: 239–79.
- 8 Chhutani PN, Chopra JS. Arsenic poisoning. In: Vinken PJ, Bruyn GW, Choan MM, et al, eds. *Intoxications of the nervous system*. New York: North Holland Publishing, 1979: 199–216.
- 9 Cavanagh JB. What have we learnt from Frederick Young? Reflections in the mechanism of thallium neurotoxicity. *Neuropathol Appl Neurobiol* 1991;**17**:3–9.
- 10 Nogue S, Mas A, Pares A, et al. Acute thallium poisoning: an evaluation of different forms of treatment. *J Toxicol Clin Toxicol* 1982;**19**:1015–21.
- 11 Hoffman RS, Shringer JA, Feinberg RS, et al. Comparative efficacy of thallium adsorption by activated charcoal Prussian blue and sodium polystyrene sulfonate. *J Toxicol Clin Toxicol* 1999;**37**:833–7.