

Empyema

## A rare cause of empyema in a non-immunocompromised case and successful combined treatment

D Karnak, D Köksal, S Beder, O Kayacan

Answers on p 185.

A 36 year old man was admitted to our hospital with a one month history of pleuritic chest pain on the left hemithorax, productive cough, and fever. He had no known medical problems or drug addiction except a smoking history of 20 pack years.

On physical examination, his temperature was 37.6°C with pulse rate 104 beats/min, and blood pressure 100/60 mm Hg. His dental hygiene was poor and he had an odontogenic infection. Chest examination revealed dullness to percussion and decreased breath

sounds on auscultation on the left lung base.

On laboratory analysis his white blood cell count was  $20.2 \times 10^9/l$  with 79% neutrophils. Haemoglobin concentration was 111 g/l and erythrocyte sedimentation rate was 68 mm/hour. Immunoglobulins were in the normal range except for a slightly raised IgG. HIV seropositivity was not found. Chest radiography revealed left pleural effusion. Based on the radiological appearances of the lesion on chest radiography and computed tomography of his thorax (fig 1), a diagnostic procedure was performed.

### QUESTIONS

- (1) What abnormality was seen on the thoracic computed tomogram?
- (2) What was the diagnostic procedure?
- (3) What additional tests were/should be performed?
- (4) What is the treatment?

*Postgrad Med J* 2004;**80**:184.  
doi: 10.1136/pgmj.2003.005355q

### Authors' affiliations

D Karnak, D Köksal, S Beder, O Kayacan,  
Department of Chest Diseases and  
Tuberculosis, Ankara University Medical  
School, Ankara, Turkey

Correspondence to: Associate Professor Demet  
Karnak, Department of Chest Diseases and  
Tuberculosis, Ankara University Medical  
School, 06100 Cebeci, Ankara, Turkey;  
karnak@medicine.ankara.edu.tr

Submitted 14 January 2003  
Accepted 16 April 2003

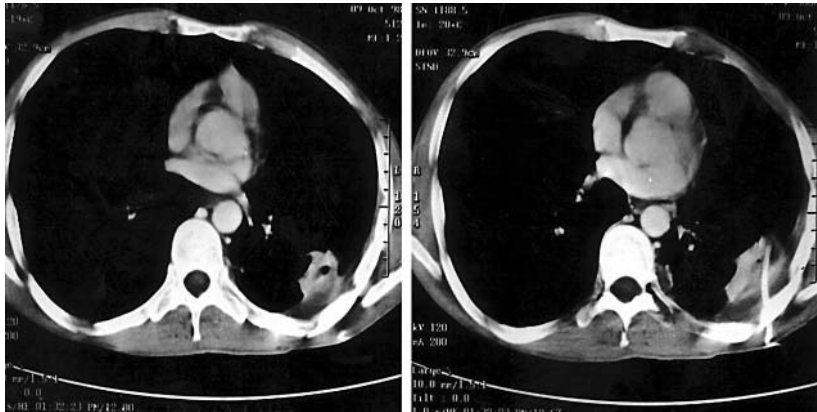


Figure 1 Computed tomograms of the thorax taken at different levels at the start of treatment.