

REVIEW

Diagnosis of tuberculous aetiology in pericardial effusions

G Cherian

Postgrad Med J 2004;80:262–266. doi: 10.1136/pgmj.2003.013664

The diagnosis of tuberculous aetiology in pericardial effusions is important since the prognosis is excellent with specific treatment. The clinical features may not be distinctive and the diagnosis could be missed particularly with tamponade. With the spread of HIV infection the incidence has increased. The diagnosis largely depends on histopathology of the pericardial tissue or culture of *Mycobacterium tuberculosis* from this tissue or fluid, but patients without haemodynamic compromise do not require pericardiocentesis. Histopathology may, however, show non-specific findings in a significant number. This review is an update on the diagnostic difficulties, current research, and criteria for diagnosis.

even when tubercle bacilli have been cultured from the pericardial fluid.¹⁴

PATHOGENESIS OF TUBERCULOUS PERICARDITIS

There are many ways in which the pericardium may be involved in tuberculosis. In a rare case there may be direct spread from tuberculous pneumonia. The pericardium can be seeded in miliary tuberculosis and in such instances other organ systems dominate the presentation. Direct extension from an infected visceral pleura or rib is rare. Most often the spread is from the breakdown of infection in mediastinal nodes directly into the pericardium and particularly those at the tracheobronchial bifurcation.¹⁵ The spread is over lymph channels that merge at points where the parietal pericardium and the pleura separate.

Tuberculous pericardial effusion (TPE) is still common in African and Asian countries,^{1 2} but with migrant populations and the spread of AIDS³ there are now more frequent reports from other parts of the world like Europe and the Western hemisphere.^{4 5} TPE usually presents as a slowly progressive febrile illness. When it presents as an acute pericarditis, which is uncommon, or as cardiac tamponade,² which is frequent, the diagnosis is more likely to be delayed or missed. The delay from hospital admission to diagnosis was 5.2 weeks in a report from Spain⁶ and in another from the USA the diagnosis was first made only at necropsy in 17% of patients.⁷ Malignant, viral, and chronic idiopathic effusions are some of the other causes of large effusions. Effusions associated with malignancy are usually but not always apparent at presentation. Chronic idiopathic effusions in which no aetiology could be established are a common cause of tamponade even in countries like the UK, France, and the USA with a reported incidence varying from 11%–32%.^{8–10}

LYMPHATIC DRAINAGE OF THE PERICARDIUM

Studies in human cadavers,¹⁶ in the macaque monkey,¹⁷ and in the dog¹⁸ show that the lymphatic drainage of the pericardium is mainly to the anterior mediastinal, tracheobronchial, lateropericardial, and posterior mediastinal (juxta oesophageal) lymph nodes and *not into the hilar nodes*. This has an important bearing on the groups of mediastinal lymph nodes that are enlarged in TPE. *The mediastinal node enlargement in TPE does not show up on routine chest radiographs (fig 1) but can be seen only on chest computed tomography or magnetic resonance imaging (MRI) studies.*¹² In other conditions associated with pericardial effusion and mediastinal adenopathy like lymphomas, malignancy, and sarcoid hilar node involvement is prominent even though in sarcoidosis the pericardium is involved in fewer than 3% of patients.¹⁹

The diagnosis of tuberculosis as the aetiological cause is important. Without specific treatment the average survival was 3.7 months in a report from Africa and only 4/20 (20%) were alive at six months.¹ On the other hand the prognosis with appropriate medical treatment is excellent as seen in recent reports.^{11 12} The confirmation of tuberculous aetiology currently depends on histopathological study of the pericardium, the demonstration of tubercle bacilli in the pericardial tissue or pericardial fluid, the presence of proved tuberculosis elsewhere in the body, or the response to specific treatment.¹³ Histopathological examination, however, can at times give non-specific findings

MEDIASTINAL LYMPH NODES IN TPE

Sir William Osler from his review of consecutive necropsies found 275 with tuberculosis of whom seven had pericarditis. He concluded that caseous mediastinal lymph nodes were the usual focus of pericardial involvement.²⁰ In another report, at necropsy all patients with TPE had mediastinal adenopathy.⁷ The groups of glands involved were not described. In another study, right scalene node biopsy was performed in six patients with TPE and even though the node was not enlarged, all six had evidence of tuberculosis.²¹

Abbreviations: MRI, magnetic resonance imaging; PCR, polymerase chain reaction; TPE, tuberculous pericardial effusion

Correspondence to:
Professor George Cherian,
Narayana Hrudayalaya,
258/A-Bommasandra
Industrial Area, Anekal
Taluk, Bangalore 562 158,
India; gcherian@vsnl.net

Submitted 18 August 2003
Accepted 26 October 2003

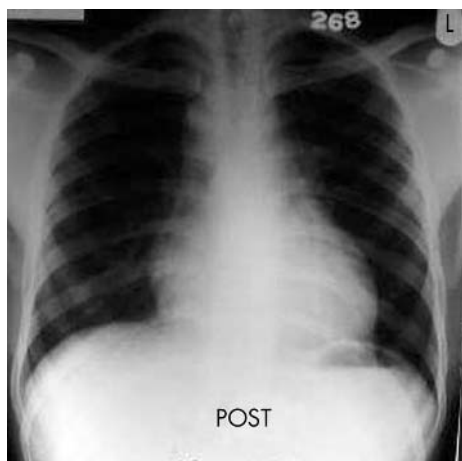


Figure 1 Chest radiograph after aspiration of same patient as in fig 4 taken at time of chest computed tomography. Nodes not seen on chest radiograph but seen only on chest computed tomogram.

PLEURA AND PERIPHERAL LYMPH NODES IN TUBERCULOSIS

Pleural effusion and peripheral lymphadenitis are two common forms of non-pulmonary tuberculosis.²² Rooney *et al* found that 50% of patients with TPE who were necropsied had pleural effusion due to tuberculous pleuritis.⁷ Tuberculous lymphadenopathy is characterised by caseation, which shows on computed tomographic studies as hypodense central areas,²³ and “matting” on palpation, which is seen on the computed tomogram as coalescing of adjacent glands. The adenopathy clears or regresses on specific therapy.^{12 24}

RECENT DEVELOPMENTS IN THE DIAGNOSIS OF TPE Polymerase chain reaction (PCR)

PCR technology has been used for nucleic acid amplification in the diagnosis of tuberculosis.²⁵ Cegielski *et al* compared PCR, culture, and histopathology in the diagnosis of TPE.²⁶ PCR was performed with both pericardial fluid and tissue with IS6110 based primers specific for the *Mycobacterium tuberculosis* complex. They concluded that the overall accuracy of PCR approached the results of conventional methods, although PCR was faster. The sensitivity for pericardial fluid was poor and false positive results with PCR remain a concern.²⁷

Serodiagnosis

The potential for serodiagnosis of TPE has been reported by Ng *et al* who tested a solid phase antibody competition sandwich ELISA (SACT-CE) method.²⁸ A monoclonal antibody (CDC/WHO reference number IT39) which was raised against a specific epitope on the *M tuberculosis* 30 kDa antigen was used. All but one of the patients had negative sputum microscopy for acid fast bacilli. A sensitivity of 61% (at 96% specificity) was achieved. It is unlikely that this technology will be widely applied. A more recent report suggests that there is a broad clonal heterogeneity of antigen specific CD4+T-cells localising at the site of disease during tuberculosis.²⁹

Adenosine deaminase and other markers

Adenosine deaminase levels are believed to reflect T-cell activity. The levels with TPE have varied from 10–303 U/l in one report,³⁰ and with a cut off level of 30 U/l the sensitivity was 94% and specificity 68% with a positive predictive accuracy of 80%. In this study the median interferon-gamma concentration in TPE was >1000 pg/l and significantly higher than malignancy or non-tuberculous effusions ($p < 0.0005$). A

cut off value of 200 pg/l for interferon-gamma resulted in a sensitivity and specificity of 100% for the diagnosis of TPE. In another report the adenosine deaminase values were a mean (SD) of 126 (16.68) U/l and significantly higher than neoplastic, idiopathic, purulent bacterial, and radiotherapy groups.³¹ On the other hand it has been suggested adenosine deaminase and lysozyme levels have to be taken into account in attempting an early diagnosis of TPE.³²

Nuclear imaging

Gallium-67 and indium-111 scintigraphy have been used in the diagnosis of TPE. The results are, however, non-specific and there are other cardiac causes of gallium-67 uptake.^{33 34}

Chest computed tomography

Recent observations on chest computed tomography regarding the detection of mediastinal lymph nodes in TPE and their value in diagnosis of TPE are discussed later.¹² Computed tomography also allows study of the pericardium and the pleural changes (fig 2).

EVALUATION OF TUBERCULOUS PERICARDIAL EFFUSION

Clinical features

Asymptomatic presentation or small effusions are infrequent unless picked up during screening during the course of an illness like AIDS. The onset is most often insidious with loss of weight and fatigue,^{1 7} but could be more acute and occasionally explosive with tamponade.^{2 12} The presenting symptoms appear to be similar all over the world. Fever (73%–97%) and dyspnoea (80%–88%) are the most frequent symptoms while precordial pain (39%–59%) is seen less often.^{1 7 12 15} Pericardial rub is present in (37%–84%)^{1 7} and rarely can even be triphasic.¹² Raised jugular venous pressure is frequent and pulsus paradoxus is present in (23%–71%) with tamponade (box 1).¹⁵

Peripheral lymphadenopathy with matting which most often affects the cervical glands has been reported in 13%–28% with TPE¹ and biopsy of the gland is diagnostic. This is unlikely to be seen in Western countries as it is a late manifestation.

Cardiac tamponade

Cardiac tamponade is a common complication of TPE. Jain *et al* found that 60% of patients with tamponade had tuberculosis.² In another study of 44 children with TPE, 90% had tamponade.³⁵ In a recent report from the USA both patients reported had tamponade³⁶ and in an earlier report 6/11 deaths were due to tamponade.⁷ Since tamponade may

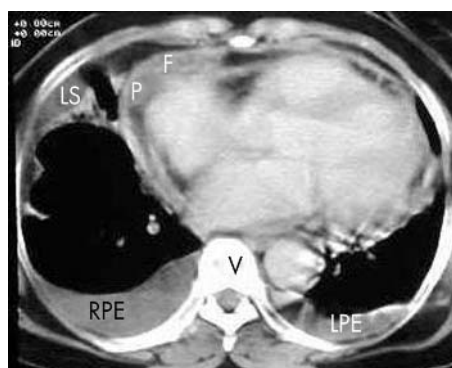


Figure 2 Pre-treatment chest computed tomogram after aspiration showing irregular pericardial thickening (P) and some fluid (F). Right (RPE) and left (LPE) pleural effusion with strands and loculation (LS) in pleural space.

Box 1: Non-specific features in tuberculous pericardial effusion

- Fever.
- Dyspnoea.
- Precordial pain.
- Loss of weight.
- Pericardial rub.
- Raised jugular venous pressure.
- Tamponade.
- Close contact with tuberculosis.

in part be due to late presentation, the incidence is likely to be higher in Afro-Asian countries.^{1, 2}

HIV infection

Tuberculosis has been reported as the predominant cause of large pericardial effusions in HIV infected patients in Tanzania.³⁷ These patients were in an early stage of HIV infection and responded well to treatment. In an inner city hospital in the USA, out of 122 patients with pericardial effusion of varying sizes, 40 were HIV related and accounted for 20% with tamponade.³

Chest radiography

Apart from the signs of pericardial effusion, radiological evidence of pulmonary tuberculosis may be present.^{1, 7} Pleural effusions are present in about 50% because of tuberculous pleuritis,⁷ and a tuberculous granuloma on pleural biopsy can help in a specific diagnosis.

Chest computed tomography

Chest computed tomography can yield valuable information in addition to the pleural changes (fig 2). The pericardium is irregular, not calcified, and is thickened measuring a mean (SD) of 4.4 (1.9) mm.¹² Normal mediastinal lymph nodes are <10 mm and do not change in size on follow up.^{38, 39} Enlarged mediastinal lymph nodes >10 mm detected on chest computed tomography have been reported recently (figs 3 and 4) and for the first time in virtually 100% of patients with

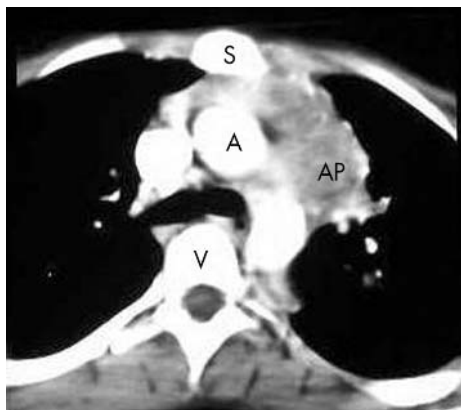

Figure 3 Pre-treatment chest computed tomogram after aspiration showing coalescing aortopulmonary (AP) nodes with matting and hypodense centre. S, sternum; A, aorta; V, vertebra. (Reprinted from Cherian G, Habashy AG, Uthaman B, *et al.* Detection and follow-up of mediastinal lymph node enlargement in tuberculous effusions using computed tomography. *Am J Med* 2003;114:319–22 with permission from Excerpta Medica, Inc).

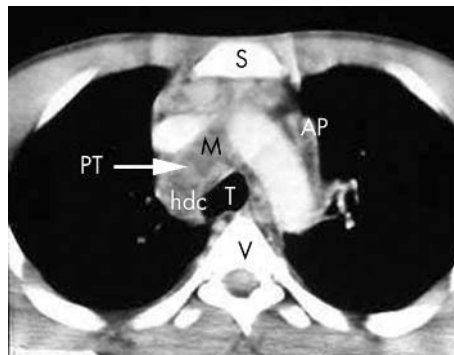


Figure 4 Pre-treatment chest computed tomogram of same patient as in fig 1 showing coalescing aortopulmonary (AP) and paratracheal (PT) nodes with matting (M) and hypodense centre (hdc). S, sternum; T, trachea; V, vertebra.

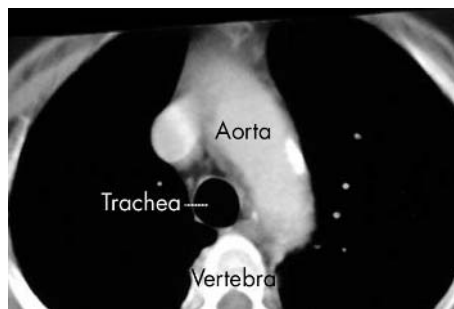


Figure 5 Chest computed tomogram in viral pericardial effusion after aspiration. No lymph nodes seen.

Box 2: Features of mediastinal nodes in tuberculous pericardial effusion

- Aortopulmonary, paratracheal, and carinal nodes most often involved.
- Typically coalesced (matted) with hypodense centre.
- Hilar nodes rare and inconspicuous.
- Hence nodes not seen on routine chest radiograph.
- Nodes seen only on chest computed tomography or MRI.
- Nodes disappear or regress on specific treatment.

TPE.¹² They were found in all 22 patients with TPE and none of a control group with large viral/idiopathic or postoperative pericardial effusion (fig 5). The gland size varied from 10–50 mm, mean (SD) 19.5 (8.6), and the number of anatomical gland areas from 1–5, mean (SD) 2.5 (1.22), with varying combinations. The aortopulmonary glands were most frequently enlarged (63%) followed by the paratracheal (51.8%), carinal (40.7%), pretracheal (25.9%), and hilar (14.8%). The glands showed a hypodense centre in 52%. Matting of adjacent glands was seen in 57.7%. The hilar glands were least frequently enlarged which can be explained from the lymphatic drainage of the pericardium. The enlarged nodes could not be seen on the plain chest radiograph (fig 1) and only on chest computed tomography and disappeared or regressed with specific anti tuberculous therapy.¹² Features of mediastinal lymph nodes in TPE are shown in box 2.

Echocardiography

The pericardial exudate is thick and fibrinous with a tendency to form adhesions and in some instances constriction. On echocardiography there are patchy deposits 4–8 mm in thickness with “fibrinous” strands criss crossing the pericardial space.⁴⁰ The appearance is quite characteristic.

Tuberculin skin test

The tuberculin skin test is done using the purified protein derivative. A positive skin reaction is an induration ≥ 10 mm and a strongly positive response is defined as one ≥ 15 mm with or without excoriation of the skin. A positive tuberculin skin test has been found in all patients with TPE in one report⁷ and in 239/240 in another.¹⁴ In the latter it was >15 mm in 78%. In a recent publication the induration measured 16.4 (3) mm.¹² A strongly positive tuberculin skin test is of value when associated with tissue granuloma without acid fast bacilli or when typical non-hilar mediastinal adenopathy is detected on chest computed tomography.

Pericardial fluid

The greatest value of the pericardial fluid is when *M tuberculosis* can be cultured as it is rare to find acid fast bacilli in a spun smear. The raised protein and lactic dehydrogenase values speak for an exudate. Lymphocytosis has been found in some studies⁴¹ but not in others. All these non-specific findings can be found in chronic idiopathic pericardial effusion as well.⁴² The value of adenosine deaminase and other markers has been discussed earlier.

Culture of mycobacterium tuberculosis

M tuberculosis may be cultured from the sputum, tissue like the pericardium, pleura, scalene node, or other accessible enlarged nodes but such information is patchy. Recovery from the pericardial fluid has varied from 30%–100%. Strang using special techniques was able to culture *M tuberculosis* from all patients.⁴³ The specimens were cultured in double strength Kirchner culture medium after bedside inoculation and also conventional culture in Stonebrink medium. *M tuberculosis* was cultured in all 10 patients, in Kirchner medium in nine and conventional in one.

Box 3: Criteria for diagnosis of tuberculous aetiology

Any of the following:

Invasive

- (1) Culture of *M tuberculosis* from pericardial fluid or tissue.
- (2) Pericardial tuberculous granuloma with acid fast bacilli.
- (3) Pericardial tuberculous granuloma + positive tuberculin skin test.
- (4) Pleural tuberculous granuloma with acid fast bacilli.
- (5) Pleural tuberculous granuloma + positive tuberculin skin test.
- (6) Tuberculous granuloma in scalene node or peripheral lymph node.

Non-invasive

- (1) Active tuberculosis elsewhere in the body.
- (2) Mediastinal (non-hilar) lymph nodes on chest computed tomography with hypodense centre and matting + positive tuberculin skin test (matting = coalescing of adjacent lymph nodes).
- (3) Response to specific antituberculous therapy.

Box 4: Questions (answers at end of references)

- (1) What are three common causes of large pericardial effusions which can pose difficulties in differential diagnosis?
- (2) What is the most frequent route by which the pericardium is affected in tuberculosis?
- (3) Which group of mediastinal nodes are least often enlarged in tuberculous pericardial effusion?
- (4) Can mediastinal lymph nodes be detected both on a plain chest radiograph as well as a chest computed tomogram?
- (5) Non-specific findings on histopathology of the pericardium may be found in around 30% of patients with proven tuberculous pericarditis. True or false?
- (6) What is the prognosis of tuberculous pericardial effusion with specific treatment?
- (7) Cardiac tamponade is a frequent mode of presentation with tuberculous pericardial effusion. True or false?

Histological evidence

Like recovery of *M tuberculosis* from the pericardial tissue or fluid, histological evidence of a tuberculous granuloma with the demonstration of acid fast bacilli would be a definite diagnostic criterion. The typical granuloma is however not always found and the pericardial biopsy may show non-specific findings even when *M tuberculosis* is found in the pericardial fluid. Strang *et al* reporting on patients with TPE found that out of 49 patients in whom *M tuberculosis* was recovered from the pericardial fluid the pericardial histological changes “characteristic of tuberculosis” was present only in 35/49 and 14/49 (29%) had non-specific findings.¹⁴ In another study 2/19 biopsies showed non specific findings.¹² This difference may be due to the number of samples obtained at biopsy.

Scalene node biopsy

The report on scalene node biopsy has been discussed earlier.²¹ This would be a safe and relatively easy route to a specific diagnosis but so far there has been only one report.

CONCLUSIONS

Tuberculosis is an important cause of pericardial effusion in Afro-Asian countries and with the spread of HIV infection there is an increased incidence all over the world. Significant recent developments have been the use of PCR technology,²⁶ improved techniques for the recovery of *M tuberculosis*,⁴³ observations on mediastinal lymph nodes on chest computed tomography,¹² and more clearly defined observations on echocardiography.⁴⁰ The diagnosis of tuberculous aetiology in pericardial effusions can be based on the criteria shown in box 3.

REFERENCES

- 1 Desai HN. Tuberculous pericarditis. A review of 100 cases. *S Afr Med J* 1979;55:877–80.
- 2 Jain S, Sharma N, Varma S, *et al*. Profile of cardiac tamponade in the medical emergency ward of a North Indian hospital. *Can J Cardiol* 1999;15:671–5.
- 3 Chen Y, Brennessel D, Walters J, *et al*. Human immunodeficiency virus-associated pericardial effusion. A report of 40 cases and review of the literature. *Am Heart J* 1999;137:516–21.
- 4 Strang JI. Tuberculous pericarditis. *J Infect* 1997;35:215–19.
- 5 Trautner BW, Darouiche RO. Tuberculous pericarditis: optimal diagnosis and management. *Clin Infect Dis* 2001;33:954–61.
- 6 Sagrista-Sauleda J, Permanyer-Miralda G, Soler-Soler J. Tuberculous pericarditis: ten year experience with a prospective protocol for diagnosis and treatment. *J Am Coll Cardiol* 1988;2:724–8.
- 7 Rooney JJ, Crocco JA, Lyons HA. Tuberculous pericarditis. *Ann Intern Med* 1970;72:73–8.

- 8 **Gibbs CR**, Watson RD, Singh SP, *et al*. Management of pericardial effusion by drainage: a survey of 10 years' experience in a city centre general hospital serving a multiracial population. *Postgrad Med J* 2000;**76**:809-13.
- 9 **Colombo A**, Olson HG, Egan J, *et al*. Etiology and prognostic implications of a large pericardial effusion in men. *Clin Cardiol* 1988;**11**:389-94.
- 10 **Loire R**, Goineau P, Fareh S, *et al*. Apparently idiopathic chronic pericardial effusion. Long-term outcome in 71 cases. *Arch Mal Coeur Vaiss* 1996;**89**:835-41.
- 11 **Long R**, Younes M, Patton N, *et al*. Tuberculous pericarditis: long term outcome in patients who received medical therapy alone. *Am Heart J* 1989;**117**:1133-9.
- 12 **Cherian G**, Habashy AG, Uthaman B, *et al*. Detection and follow-up of mediastinal lymph node enlargement in tuberculous effusions using computed tomography. *Am J Med* 2003;**114**:319-22.
- 13 **Fowler NO**. Tuberculous pericarditis. *JAMA* 1991;**266**:99-103.
- 14 **Strang JIG**, Kakaza HHS, Gibson DG, *et al*. Controlled clinical trial of complete open surgical drainage and of prednisolone treatment of tuberculous pericardial effusion in the Transkei. *Lancet* 1988;ii:759-64.
- 15 **Orbals DW**. Tuberculous pericarditis. *Arch Intern Med* 1979;**139**:231-4.
- 16 **Eliskova M**, Eliska O, Miller AJ. The lymphatic drainage of the parietal pericardium in man. *Lymphology* 1995;**28**:208-17.
- 17 **Eliskova M**, Eliska O, Miller AJ, *et al*. The efferent cardiac lymphatic pathways in the macaque monkey. *Lymphology* 1992;**25**:69-74.
- 18 **Miller AJ**, DeBoer A, Pick R, *et al*. The lymphatic drainage of the pericardial space in the dog. *Lymphology* 1988;**21**:227-33.
- 19 **Pesola G**, Teirstein AS, Goldman M. Sarcoidosis presenting with pericardial effusion. *Sarcoidosis* 1987;**4**:42-4.
- 20 **Spodick DH**. Tuberculous pericarditis. *Arch Intern Med* 1956;**98**:737-49.
- 21 **Chitnis AS**, Joshi VR, Cherian A, *et al*. Utility of scalene node biopsy in the diagnosis of pleuro-pericardial tuberculosis. *J Assoc Physicians India* 1974;**22**:805-8.
- 22 **Light RW**. Disorders of pleura mediastinum diaphragm. In: Isselbacher KJ, Braunwald E, Wilson JD, *et al*. *Harrison's principles of internal medicine*. New York: McGraw-Hill, 1994:1229-34.
- 23 **Klein JS**. The hila. In: Brant WE, Helms CA, eds. *Fundamentals of diagnostic radiology*. Baltimore: Williams and Wilkins, 1994:390-411.
- 24 **Kobzik L**. The lung. In: Cotran RS, Kumar V, Collins T, eds. *Robbins pathologic basis of disease*. Philadelphia: WB Saunders, 1999, 351, 697-755.
- 25 **Rana BS**, Jones RA, Simpson IA. Recurrent pericardial effusion: the value of polymerase chain reaction in the diagnosis of tuberculosis. *Heart* 1999;**82**:246-7.
- 26 **Cegielski JP**, Devlin BH, Morris AJ, *et al*. Comparison of PCR, culture, and histopathology for diagnosis of tuberculous pericarditis. *J Clin Microbiol* 1997;**35**:3254-7.
- 27 **Lee JH**, Lee CW, Lee SG, *et al*. Comparison of polymerase chain reaction with adenosine deaminase activity in pericardial fluid for the diagnosis of tuberculous pericarditis. *Am J Med* 2002;**113**:519-21.
- 28 **Ng TT**, Strang JI, Wilkins EG. Serodiagnosis of pericardial tuberculosis. *Q J Med* 1995;**88**:317-20.
- 29 **Dieli F**, Sireci G, Ivanyi J, *et al*. Broad clonal heterogeneity of antigen-specific CD4+T cells localizing at the site of disease during tuberculosis. *Immunol Lett* 1999;**69**:311-15.
- 30 **Burgess LJ**, Reuter H, Carstens ME, *et al*. The use of adenosine deaminase and interferon gamma as diagnostic tools for tuberculous pericarditis. *Chest* 2002;**122**:900-5.
- 31 **Komsuoglu B**, Goldeli O, Kulan K, *et al*. The diagnostic and prognostic value of adenosine deaminase in tuberculous pericarditis. *Eur Heart J* 1995;**16**:1126-30.
- 32 **Aggeli C**, Pitsavos C, Brili S, *et al*. Relevance of adenosine deaminase and lysozyme measurements in the diagnosis of tuberculous pericarditis. *Cardiology* 2000;**94**:81-5.
- 33 **Lin DS**, Tipton RE. Ga-67 cardiac uptake. *Clin Nucl Med* 1983;**8**:603-4.
- 34 **Schmidt U**, Rebarber IF. Tuberculous pericarditis identified with gallium-67 and indium-111 leukocyte imaging. *Clin Nucl Med* 1994;**19**:146-7.
- 35 **Hugo-Hamman CT**, Scher H, De Moor MM. Tuberculous pericarditis in children: a review of 44 cases. *Pediatr Infect Dis* 1994;**13**:13-18.
- 36 **Gladych E**, Goland S, Attali M, *et al*. Cardiac tamponade as a manifestation of tuberculosis. *South Med J* 2001;**94**:525-8.
- 37 **Cegielski JP**, Lwakatere J, Dukas CS, *et al*. Tuberculous pericarditis in Tanzanian patients with and without HIV infection. *Tuber Lung Dis* 1994;**75**:429-34.
- 38 **Glazer GM**, Gross BH, Quint LE, *et al*. Normal mediastinal lymph nodes: number and size according to American Thoracic Society mapping. *Am J Roentgenol* 1985;**144**:261-5.
- 39 **Ingram CE**, Belli AM, Lewars MD, *et al*. Normal lymph node size in the mediastinum: a retrospective study in two patient groups. *Clin Radiol* 1989;**40**:35-9.
- 40 **Liu PY**, Li YH, Tsai WC, *et al*. Usefulness of echocardiographic intrapericardial abnormalities in the diagnosis of tuberculous pericardial effusion. *Am J Cardiol* 2001;**87**:1133-5.
- 41 **Strang JI**. Tuberculous pericarditis in Transkei. *Clin Cardiol* 1984;**7**:667-70.
- 42 **Agner RC**, Gallis HA. Pericarditis. Differential diagnostic considerations. *Arch Intern Med* 1979;**139**:407-12.
- 43 **Strang JIG**. Rapid resolution of tuberculous pericardial effusions with high dose prednisone and anti-tuberculous drugs. *J Infect* 1994;**28**:251-4.

ANSWERS

- (1) Tuberculosis, viral, and chronic idiopathic.^{8-10 12 42} (2) From infected mediastinal lymph nodes.^{7 15} (3) Hilar group.¹² (4) No. Not seen on plain chest radiograph.¹² (5) True.¹⁴ (6) Excellent.^{11 12} (7) True.^{2 35}