

## CASE REPORT

# IgA multiple myeloma presenting as non-obstructive jaundice

N Arebi, B Patel, N M Aqel, M C L Pitcher

*Postgrad Med J* 2004;**80**:489–490. doi: 10.1136/pgmj.2002.002147

Multiple myeloma can occasionally present with jaundice. The underlying process may be pancreatic head myeloma infiltration causing obstructive jaundice or hepatic amyloid deposition resulting in cholestatic jaundice. A rare case of myeloma presenting as jaundice due to hepatic myeloma infiltration is reported.

A 66 year old Nigerian man presented in November 2001 with a one day history of jaundice with pale stools and dark urine. He also gave a four week history of lethargy, anorexia, and weight loss. There were no other gastrointestinal symptoms. He denied complaints of dysuria or haematuria.

In 1999 he underwent a right radical nephrectomy for a Robson's stage 1 renal cell carcinoma; extrarenal disease was not detected. After nephrectomy, a diagnosis of transitional cell carcinoma of the bladder was made at cystoscopy (grade 3 pTa), with a benign nodular prostate. He also had an episode of jaundice in 1950, an appendicectomy in 1979, and a fractured left neck of femur after a road traffic accident in 1989. There was no relevant family history. Although born in Nigeria, he had been a resident in the UK since 1960. He was a retired security guard, and denied intravenous drug use and sexual contacts. His medications on admission were co-codamol as required and he had no known drug allergies.

On examination he looked pale, dehydrated, and jaundiced. His temperature was 37.7°C but there were no stigmata of chronic liver disease. Cardiovascular, respiratory, and abdominal examinations were normal.

The results of the blood test performed on admission were as follows: haemoglobin 53 g/l, white cell count  $9.9 \times 10^9/l$ , platelets  $285 \times 10^{12}/l$ , C-reactive protein 330 mg/l, alanine aminotransferase (ALT) 64 IU/l, alkaline phosphatase (ALP) 406 IU/l, bilirubin 142  $\mu\text{mol}/l$ ,  $\gamma$ -glutamyltransferase 183 IU/l, albumin 22 g/l, corrected calcium 2.59 mmol/l, creatinine 126  $\mu\text{mol}/l$ , electrolytes normal, serum amylase 95 IU/l, prothrombin time 17.7 sec, activated partial thromboplastin time 47.3 sec, and fibrinogen 11.63 g/l. Blood and urine were collected for cultures studies before he was started on antibiotics and transfused six units of blood. Over the next 10 days his liver function deteriorated: ALT 201 IU/l, ALP 333 IU/l, bilirubin 416  $\mu\text{mol}/l$ , albumin 15 g/l, prothrombin time 18.9 sec. He also remained anaemic and this was accompanied by persistent swinging pyrexia despite antibiotic treatment. Other investigations were performed to investigate the anaemia, fever, and jaundice. Blood film showed marked rouleaux formations and target cells. The direct antiglobulin test was negative. Blood, stool, and urine cultures did not reveal any growths. Abdominal ultrasound scans were normal but computed tomography showed three small attenuation lesions in the liver. Gastroscopy and endoscopic retrograde cholangiopancreatography were

normal. Hepatitis A, B, C antibodies and autoantibodies were negative. Alpha-fetoprotein was 3 U/l. Serum ferritin was raised (5283  $\mu\text{g}/l$ ) with normal B12 and red cell folate levels. Immunoglobulins were as follows: IgG 2.6 g/l (7–16), IgM 0.4 g/l (0.4–2.3), and IgA 51.4 g/l (0.7–4.0). A liver biopsy was also performed: this showed dilated sinuses, which contained plasma cells, plasmablasts, and extramedullary haemopoietic cells. Myeloma cells also infiltrated portal tracts. In addition, bile canaliculi contained abundant bile. There was no evidence of amyloid deposition in the liver biopsy (fig 1). A bone marrow trephine (fig 2) showed heavy deposits of plasma cells. Most of these were immature plasmablasts with prominent nucleoli. Residual normal haemopoietic cells were markedly reduced in numbers. A diagnosis of multiple myeloma with liver involvement was made. Serum protein electrophoresis confirmed the presence of a broad monoclonal band seen in the  $\beta/\gamma$  globulin regions. The band type was identified as IgA lambda at a concentration of 75 g/l, 66.9% of the total protein.

Unfortunately the patient refused treatment for the myeloma and his condition deteriorated with the onset of renal failure. He died a few days later.

## DISCUSSION

This case describes a 66 year old man who presented with cholestatic jaundice secondary to IgA myeloma. Cholestatic jaundice is a recognised complication of myeloma. However, all cases reported to date have been due to hepatic amyloid deposition or extrahepatic biliary tract obstruction. There has been only one report in the literature of plasma cell infiltration presenting as jaundice.<sup>1</sup>

Liver involvement in multiple myeloma is uncommon. Perez-Soler *et al* reported on the liver histological abnormalities seen in 21 of 128 patients diagnosed with multiple

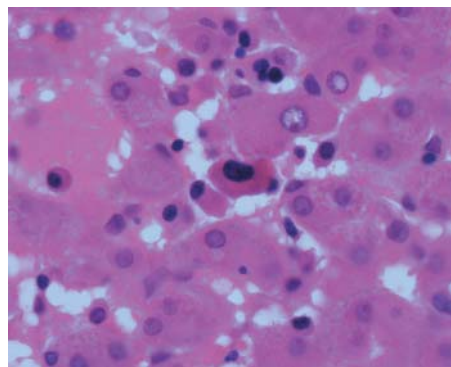
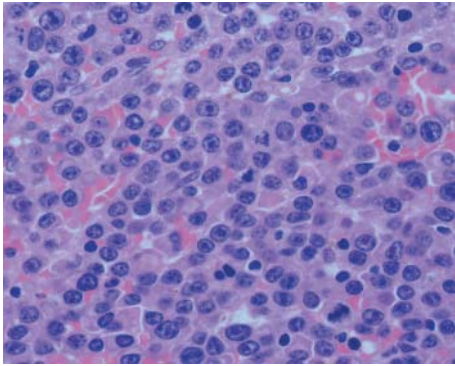


Figure 1 Liver biopsy specimen.

**Abbreviations:** ALP, alkaline phosphatase; ALT, alanine aminotransferase



**Figure 2** Bone marrow trephine.

myeloma.<sup>2</sup> Diffuse infiltration by plasma cells was observed in 10 patients, myeloid metaplasia in four, and amyloid deposits in two. Two patients showed evidence of toxic hepatitis and one had extrahepatic cholestasis secondary to infiltration of the pancreas. A clinical presentation of jaundice was only evident in patients with hepatitis or extrahepatic cholestasis. A more recent report on liver involvement in all haematological malignancies<sup>3</sup> supported the uncommon involvement of the liver in myeloma—32% of cases showed involvement, which presented with hepatomegaly. In these cases histology showed portal and sinusoidal tract infiltration or nodular infiltration, but none of these patients had jaundice.

Myeloma infiltration of the liver presents in the form of hepatomegaly or abnormalities of liver function tests due to amyloidosis. Jaundice has been reported in the context of extrahepatic obstructive jaundice due to pancreatic infiltration,<sup>4,5</sup> or due to hepatic amyloid deposition.<sup>6</sup> Hepatic failure due to myeloma-associated amyloidosis is rare; only four cases have been described in the literature.<sup>7</sup>

Radiologically, the nodular liver infiltration may be visible on ultrasound. Hepatic nodules have been reported on ultrasound<sup>8</sup> and these lesions have been shown to disappear after chemotherapy.<sup>9</sup> Kitazono *et al* have suggested that some

of these nodules may represent nodular regenerative hyperplasia of the liver rather than myeloma infiltration.<sup>10</sup>

The case described in this report is exceptional in that the picture was of cholestatic jaundice without evidence of extrahepatic obstruction, amyloid deposition, or pre-existing liver disease. Plasma cells infiltration was visible on liver biopsy; Congo red staining for amyloidosis was negative. The jaundice was secondary to intrahepatic cholestasis.

#### Authors' affiliations

**N Arebi, B Patel, N M Aqel, M C L Pitcher**, Departments of Gastroenterology and Cellular Pathology, Northwick Park and St Mark's Hospitals, Watford Road, Harrow, Middlesex, UK

Correspondence to: Dr Naila Arebi, Department of Gastroenterology, Northwick Park and St Mark's Hospitals, Watford Road, Harrow HA1 3UJ, UK; naila.arebi@ic.ac.uk

Submitted 8 October 2002

Accepted 24 March 2004

#### REFERENCES

- 1 **Pastor E**, Perella M, Gomez A, *et al*. Multiple myeloma of the liver presenting as non-obstructive jaundice. *Am J Hematol* 1996;**53**:205–6.
- 2 **Perez-Soler R**, Esteban R, Allende E, *et al*. Liver involvement in multiple myeloma. *Am J Hematol* 1985;**20**:25–9.
- 3 **Walz-Mattmuller R**, Horny HP, Ruck P, *et al*. Incidence and pattern of liver involvement in haematological malignancies. *Pathol Res Pract* 1998;**194**:781–9.
- 4 **Bell HG**, David R, Shamsuddin AM. Extrahepatic biliary obstruction and liver failure secondary to myeloma of the pancreas. *Hum Pathol* 1982;**3**:940–2.
- 5 **Abu-Hammour AM**, Venu RP, Etkorn KP, *et al*. Common bile duct obstruction caused by multiple myeloma of the pancreas. *Gastrointest Endosc* 1996;**44**:606–8.
- 6 **Segev A**, Manor Y, Bernheim J, *et al*. Light chain myeloma presenting as severe obstructive jaundice due to hepatic amyloidosis. *Eur J Haematol* 1999;**63**:364–5.
- 7 **Ales NC**, Daniels JT, Frizell ER, *et al*. Multiple myeloma-associated amyloidosis manifesting as fulminant hepatic failure. *South Med J* 2001;**30**:393–7.
- 8 **Thiruvengadam R**, Penetrante RB, Goolsby HJ, *et al*. Multiple myeloma presenting as space-occupying lesions of the liver. *Cancer* 1990;**65**:2784–6.
- 9 **Curtis JM**, Pellegrini V, Tappin JA. Case report: multiple myeloma—a rare presentation. *Clin Radiol* 1995;**50**:63–4.
- 10 **Kitazono M**, Saito Y, Kinoshita M, *et al*. Nodular regenerative hyperplasia of the liver in a patient with multiple myeloma and systemic amyloidosis. *Acta Pathologica Japonica* 1985;**35**:961–7.