

ORIGINAL ARTICLE

Aneurysmal subarachnoid haemorrhage: guidance in making the correct diagnosis

W A Liebenberg, R Worth, G B Firth, J Olney, J S Norris

Postgrad Med J 2005;81:470–473. doi: 10.1136/pgmj.2004.023788

See end of article for authors' affiliations

Correspondence to:
Mr W A Liebenberg,
Hurstwood Park
Neurological Centre,
Lewes Road, Haywards
Heath, West Sussex RH16
4EX, UK;
adriaanliebenberg@fiscalis.
co.uk

Submitted 4 May 2004
Accepted 10 August 2004

Background: The natural history of untreated aneurysmal subarachnoid haemorrhage carries a dismal prognosis. Case fatalities range between 32% and 67%. Treatment with either surgical clipping or endovascular coiling is highly successful at preventing re-bleeding and yet the diagnosis is still missed.

Methods: Based on the national guidelines for analysis of cerebrospinal fluid for bilirubin in suspected subarachnoid haemorrhage and a review of other available literature this study has compiled guidance in making the diagnosis.

Conclusion: In patients presenting with a suspected non-traumatic subarachnoid haemorrhage, computed tomography within 12 hours will reliably show 98% of subarachnoid haemorrhage. In patients who present after 12 hours with a negative computed tomogram, formal cerebrospinal fluid spectrophotometry will detect subarachnoid haemorrhage for the next two weeks with a reliability of 96%. Between the early diagnosis with the aid of computed tomography and the later diagnosis with the added benefit of spectrophotometry in the period where computed tomograms become less reliable, it should be possible to diagnose most cases of subarachnoid haemorrhage correctly.

In the UK the incidence of all types of strokes are 13.3 per 10 000.¹ The cost approaches £30 000 per patient per year.² Subarachnoid haemorrhage (SAH) affects 10 per 100 000 UK residents per year.³ Modern management has reduced morbidity and mortality by 15% over the past three decades.⁴ We are however still missing the diagnosis at first presentation.

Aneurysmal SAH is a devastating disease. The natural history of untreated aneurysmal SAH carries a dismal prognosis. Case fatalities range between 32% and 67%⁴ of which half die because of a re-bleed.⁵ The highest probability of a re-bleed is during the first month. Treatment with either surgical clipping or endovascular coiling is highly successful at preventing re-bleeding and a recent multicentre, prospective, randomised trial found that 23.7% of patients were dependent or dead at one year after endovascular coiling and so were 30.6% of patients that were allocated to surgical clipping of the aneurysm(s).⁶ If the diagnosis is missed and the aneurysm not treated, the results are frequently fatal.

Not all SAH is attributable to aneurysms and non-aneurysmal SAH resulting from trauma or perimesencephalic SAH needs to be investigated with angiography to exclude underlying vascular abnormalities that require treatment.

A recent retrospective study found that 51% of patients were misdiagnosed on first presentation.⁷ The fundamentals of investigating patients with sudden severe headaches and suspected SAH cannot be revisited enough.

METHODS

Our article was prepared from a review of the most recently published literature related to the diagnosis of SAH combined with input from clinicians experienced in the fields of neurosurgery, clinical chemistry section, and neuroradiology. The biochemistry was based in part on the national guidelines for analysis of cerebrospinal fluid for bilirubin in suspected subarachnoid haemorrhage,⁸ and in part on a review of other available literature. Our aim is to provide clinicians regularly seeing patients with suspected SAH, including general physicians and other emergency department staff, with a clear guide as to how to approach the

diagnosis of a patient with a suspected non-traumatic SAH. In addition we have provided three relevant case histories that serve to further highlight the pitfalls in making the correct diagnosis.

CLINICAL FEATURES

The clinical features of SAH vary, however the most important complaint of patients presenting with suspected SAH, is that of headache. Any patient who complains of a sudden severe thunderclap headache should be considered to have suffered a SAH until proved otherwise. It is extremely important to obtain a detailed history of the nature, onset, and intensity of the headache. A recent prospective study⁹ showed that 37% of patients presenting to family practitioners with acute, severe headaches had serious intracranial abnormality of which 25% had confirmed SAH.¹⁰ It has been further shown that 20%–40% of patients confirmed to have SAH, had experienced at least one "sentinel" headache in the preceding week to two months of presentation.^{10–12}

If the headache is associated with other symptoms then suspicion should rise even further. Nausea and vomiting (77%), loss of consciousness (53%), and neck stiffness (35%) have commonly been found in patients presenting with SAH. Photophobia is also a frequent finding. Important examination findings are a reduced conscious level and focal neurological deficit such as a hemiparesis or cranial nerve deficit. Examination findings can give clues about the location of aneurysms and the presence of a third cranial nerve palsy for instance is indicative of a posterior communicating artery aneurysm. Vitreous haemorrhage is occasionally noted and subhyaloid haemorrhage is indicative of SAH.

RADIOLOGICAL CONFIRMATION (MAY BE NEGATIVE)

Computed tomography (CT)

Modern CT scanners are very sensitive in detecting SAH. The sensitivity of CT scans in confirming SAH reduces over time.

Abbreviations: SAH, subarachnoid haemorrhage; CT, computed tomography; CSF, cerebrospinal fluid

It has been shown that 98% of CT scans are positive for SAH within 12 hours and 95% within 24 hours, the pick up rate then decreases to 73% on day three.^{13 14} In those patients with suspected SAH a non-contrasted CT scan of the brain must be done as a matter of urgency. Figure 1 shows examples of CT scans where SAH is present in identifiable anatomical areas. Sometimes, however changes are much subtler than this and require some experience to diagnose.

Magnetic resonance imaging (MRI)

MRI is increasingly available for the investigation of patients with an acute neurological presentation. MRI using gradient echo or FLAIR sequences is nearly as sensitive as CT acutely (less than four days, gradient echo has 94% sensitivity) but is especially useful in the subacute phase (after one to two weeks), and can help not only with the diagnosis but also localising the site of bleeding.¹⁵

CLINICAL CHEMISTRY

The term “xanthochromia” was first used in 1902 by Milian and Chiray to describe the discoloured CSF supernatant in SAH. It was not until 1955 when Barrows published a paper,¹⁶ describing a technique for evaluating CSF supernatant with “photo-electric spectrophotometry” (now called spectrophotometry), that the routine evaluation of CSF in patients with suspected SAH became possible. It has now become an excellent test for diagnosing SAH, particularly in cases where the clinical presentation is atypical, the CT scan equivocal, or when the patient presents at a late stage. It should be appreciated that visual inspection alone, which is still performed in a significant number of hospital laboratories, is not a sufficiently sensitive test as it cannot reliably distinguish between low levels of oxyhaemoglobin and bilirubin.¹⁷

Lumbar puncture

In patients where CT is negative or equivocal after evaluation by an experienced clinician or radiologist, the next stage in making the diagnosis should be to perform a lumbar puncture. This procedure should be carried out as a planned procedure by a suitably experienced clinician as a single atraumatic puncture is essential to avoid a “bloody tap”. It is not usually necessary to perform a lumbar puncture in the middle of the night. It has been established that lumbar puncture, in patients where SAH is suspected, is safe in the absence of focal neurological deficit or drowsiness.^{18 19}

Red cell physiology

To interpret the CSF results correctly, it is important that the clinician has some basic understanding of the physiology of red blood cell lysis and of haemoglobin breakdown. When a patient suffers a SAH, blood enters the CSF where it will haemolyse within two to four hours producing oxyhaemoglobin. It is vital to appreciate that this process occurs both in vivo and in vitro. Thus red blood cells introduced into a CSF sample as a consequence of a “traumatic tap” will also produce oxyhaemoglobin. Oxyhaemoglobin is then converted to bilirubin over a period of 12 hours (9–15 hours).

The conversion of oxyhaemoglobin takes place in the presence of the enzyme haemoxygenase, which is found only in macrophages, arachnoid membrane, and the choroid plexus and thus this process can only take place in vivo. Therefore the presence of bilirubin cannot be caused by a traumatic tap. (Unless the traumatic tap had been preceded by a previous traumatic tap more than 12 hours before).

Spectrophotometry

Spectrophotometry can detect both oxyhaemoglobin and bilirubin. Oxyhaemoglobin produces an absorption peak at

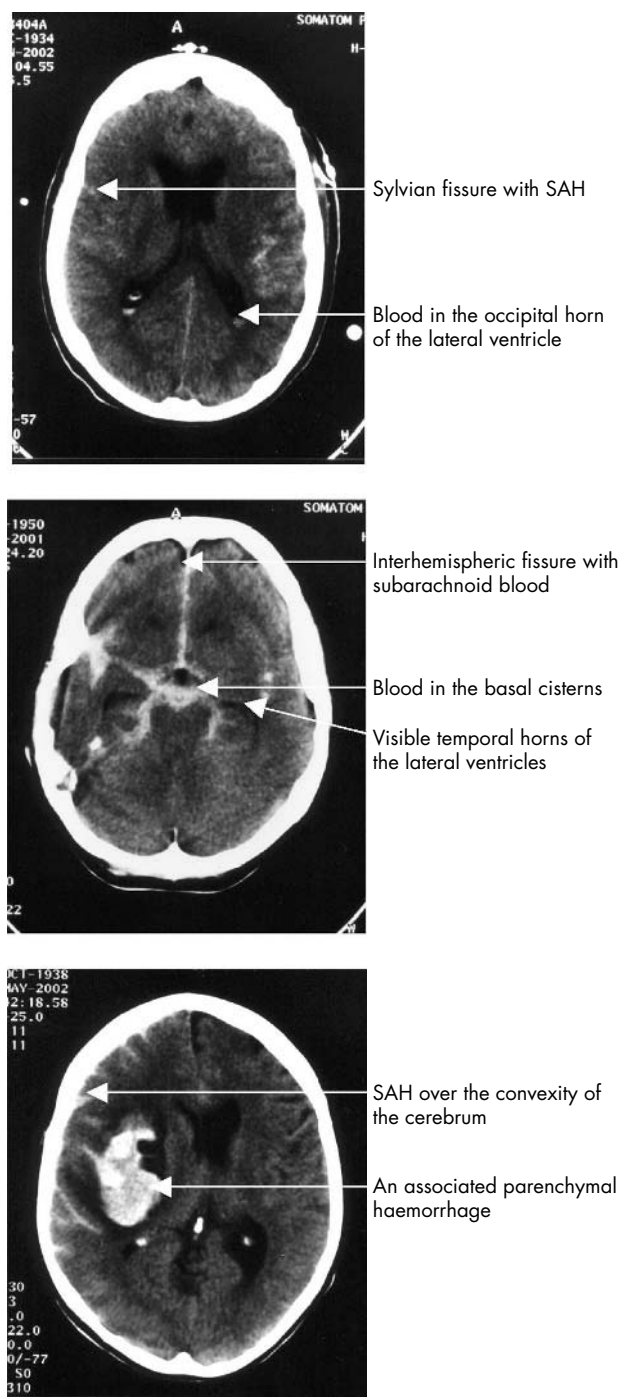


Figure 1 Examples of CT scans showing subarachnoid haemorrhage.

413–415 nm, bilirubin when detected alone produces a peak at 450–460 nm. When both bilirubin and oxyhaemoglobin are detected there is a bilirubin “shoulder” on the downward slope of the oxyhaemoglobin peak.

Oxyhaemoglobin can be detected as early as two hours after SAH. Bilirubin however needs longer to be detectable. It has been shown that at least 12 hours needs to have passed before bilirubin can be reliably detected on spectrophotometry.²⁰ The levels of bilirubin rise steadily for the first week after which they start to fall. A study in 1989²¹ found that patients with confirmed SAH evident by CT also had a confirmed bilirubin peak on spectrophotometry in 100% of cases, where CSF was examined 12 hours to two weeks after

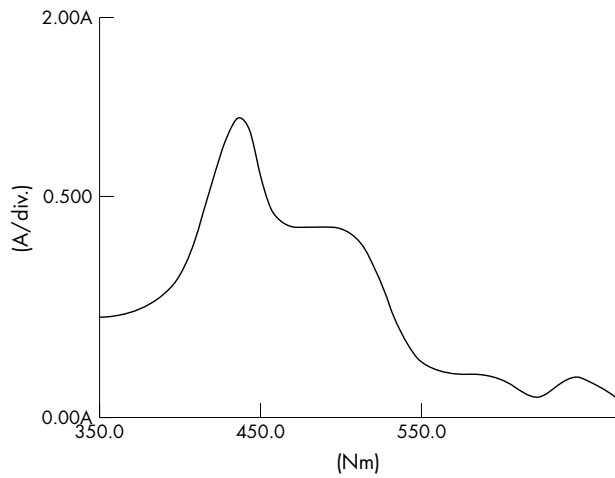


Figure 2 Diagram of spectrophotometric scan of lumbar cerebrospinal fluid showing the presence of both oxyhaemoglobin and bilirubin.

the ictus and after three weeks 70% of patients tested positive while after four weeks 40% still did.

Where lumbar punctures are performed at least 12 hours after SAH the sensitivity of bilirubin to diagnose a SAH has been shown to be 96%.²¹ It has also been suggested that cytological examination of CSF is important to look for erythrophages (macrophages with ingested red cells), which suggest a possible traumatic tap.²² If a lumbar puncture is performed 12 hours after presentation and bilirubin is detected, regardless of the presence or absence of oxyhaemoglobin, the diagnosis of SAH is confirmed. The exceptions to this are when serum bilirubin or CSF protein are significantly raised. Formulas are available to our laboratory personnel to correct for the contribution of a raised serum bilirubin concentration to the spectrophotometric scan. Where there is a raised CSF protein level this may either directly increase the CSF bilirubin or it may point to

meningeal inflammation, which if severe may cause micro haemorrhages and consequently result in a raised bilirubin. However, if spectrophotometry does not show a bilirubin peak and the clinical suspicion is high enough, formal angiography should be undertaken to exclude the presence of an underlying vascular abnormality.

Lumbar punctures performed incorrectly

The detection of only an oxyhaemoglobin peak in a sample taken at least 12 hours after SAH is most probably attributable to a traumatic lumbar puncture. If a CSF sample is very heavily bloodstained then spectroscopy results should be interpreted with caution as they show false positive oxyhaemoglobin and bilirubin peaks.²³

If a lumbar puncture is performed before 12 hours, spectrophotometry may be negative. Furthermore, blood may have been introduced into the CSF at the time of the procedure meaning that spectrophotometry performed on subsequent lumbar punctures samples may be misleading. In our own experience, patients presenting with sudden headaches and equivocal CT scans are commonly exposed to potentially dangerous angiography (morbidity and mortality less than 5%) to exclude cerebral aneurysms where improperly timed lumbar punctures have been performed.

Summary points

- All patients presenting with sudden severe headache warrant further investigation
- A CT scan within 12 hours of presentation is 98% sensitive for SAH
- Lumbar puncture must be performed more than 12 hours after presentation
- Visual analysis of CSF is not acceptable
- Spectrophotometric detection of bilirubin in CSF is indicative of SAH

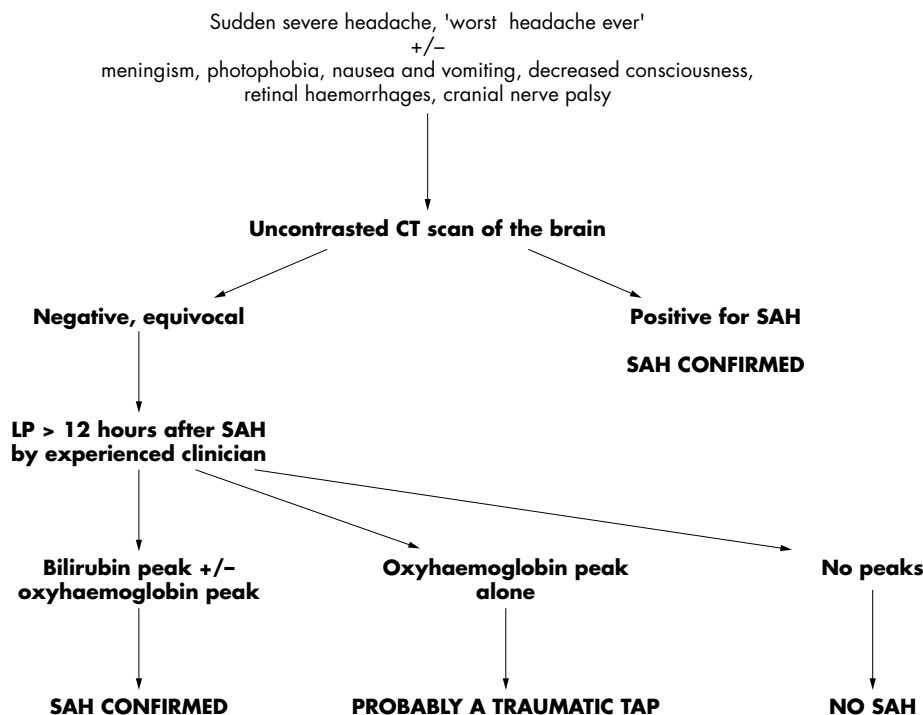


Figure 3 Suggested scheme for diagnosing patients with suspected SAH.

CASE STUDY 1 (OBVIOUS SAH)

A 58 year old woman presented with sudden, severe frontal headache to a local accident and emergency department. The patient was discharged with oral analgesia after a cursory physical examination and no investigations. The following day she was found collapsed in her garden with a GCS of 5/15, she was subsequently taken to the hospital where she was intubated, ventilated, and given supportive care. A CT scan showed blood widespread throughout the CSF and subarachnoid spaces, she then deteriorated and died later the same day.

CASE STUDY 2 (CT NEGATIVE SAH)

A 36 year old man presented to a local accident and emergency department with a severe, sudden occipital headache. He also had obvious associated neck stiffness. The patient was examined and was sent home with analgesia. Three days later he returned to hospital with a persisting headache. CT was performed and was negative. After overnight observation he was discharged again. The patient returned on a third occasion (six days after the ictus) and then underwent a lumbar puncture. Spectrophotometry showed a positive bilirubin peak. Angiography showed a left carotid aneurysm. This was successfully treated by surgery and he made an uneventful recovery.

CASE STUDY 3 (CT NEGATIVE AND A CONFOUNDING TRAUMATIC LUMBAR PUNCTURE)

A 29 year old woman presented with an ictus for a few minutes followed by a severe occipital headache and photophobia. She was also suffering from mild neck stiffness. CT performed immediately after arrival was not diagnostic of SAH. A traumatic lumbar puncture was performed about four hours after her neurological event. On referral to the neurosurgical unit 24 hours after the initial presentation, we performed cerebral angiography (after a repeat lumbar puncture showed a bilirubin peak) to exclude a cerebral aneurysm. The angiogram, which should have been avoided by correctly timed and executed lumbar puncture, was normal.

CONCLUSION

In patients presenting with a suspected non-traumatic SAH, CT within 12 hours will reliably show 98% of SAH. In patients who present after 12 hours with a negative CT scan, formal CSF spectrophotometry will detect SAH for the next two weeks with a reliability of 96%. Between the early diagnosis with the aid of CT and the later diagnosis with the added benefit of spectrophotometry in the period where CT scans become less reliable, we should be able to diagnose most cases of SAH correctly. Whenever clinicians feel uncertain about the possibility of SAH and the treatment, it is always advisable to consult the local neurosciences unit.

Authors' affiliations

W A Liebenberg, R Worth, J Olney, J S Norris, Hurstwood Park Neurological Centre, Haywards Heath, UK

G B Firth, Princess Royal Hospital, Haywards Heath, UK

Funding: none.

Conflicts of interest: none declared.

REFERENCES

- 1 **Wolfe CD**, Rudd AG, Howard R, *et al*. Incidence and case fatality rate of stroke subtypes in a multiethnic population: the South London Stroke Register. *J Neurol Neurosurg Psychiatry* 2002;**72**:211–16.
- 2 **Youman P**, Wilson K, Harraf F, *et al*. The economic burden of stroke in the United Kingdom. *Pharmacoeconomics* 2003;**21**(suppl 1):43–50.
- 3 **Mitchell P**, Hope T, Gregson BA, *et al*. Regional differences in outcome from subarachnoid haemorrhage: comparative audit. *BMJ* 2004;**328**:1234–5.
- 4 **Hop JW**, Rinkel JGE, Algra A, *et al*. Case fatality rates and functional outcome after subarachnoid hemorrhage: a systematic review. *Stroke* 1997;**28**:660–4.
- 5 **Pakarinen S**. Incidence, aetiology, and prognosis of primary subarachnoid haemorrhage. A study based on 589 cases diagnosed in a defined urban population during a defined period. *Acta Neurol Scand* 1967;**43**(suppl 29):1–28.
- 6 **Molyneux A**, Kerr R, Stratton I, *et al*. International subarachnoid aneurysm trial (ISAT) of neurosurgical clipping versus endovascular coiling in 2143 patients with ruptured intracranial aneurysms: a randomised trial. *Lancet* 2002;**360**:1267–74.
- 7 **Neil-Dwyer G**, Lang D. 'Brain attack'—aneurysmal subarachnoid haemorrhage: death due to delayed diagnosis. *J R Coll Physicians Lond* 1997;**31**:49–52.
- 8 **Working party**. The national guidelines for analysis of cerebrospinal fluid for bilirubin in suspected subarachnoid haemorrhage. *Ann Clin Biochem* 2003;**40**:481–8.
- 9 **Linn FHH**, Wijidicks EFM, van der Graaf Y, *et al*. Prospective study of sentinel headache in aneurysmal subarachnoid haemorrhage. *Lancet* 1994;**344**:590–3.
- 10 **Bassi P**, bandera R, Loiero M, *et al*. Warning signs in subarachnoid haemorrhage: a cooperative study. *Acta Neurol Scand* 1991;**84**:277–81.
- 11 **Verweij RD**, Wijidicks EFM, van Gijn J. Warning eadache in aneurysmal subarachnoid hemorrhage. *Arch Neurol* 1988;**45**:1019–20.
- 12 **Leblanc R**. The minor leak preceding subarachnoid hemorrhage. *J Neurosurg* 1987;**66**:35–9.
- 13 **van der Wee N**, Rinkel GJ, Hasan D, *et al*. Detection of subarachnoid haemorrhage on early CT: is lumbar puncture still needed after a negative scan? *J Neurol Neurosurg Psychiatry* 1995;**58**:357–9.
- 14 **Adams Jr HP**, Kassell NF, Torner JC, *et al*. CT and clinical correlations in recent aneurysmal subarachnoid hemorrhage: a preliminary report of the cooperative aneurysm study. *Neurology* 1983;**33**:981–8.
- 15 **Mitchell P**, Wilkinson I. D, Hoggard N, *et al*. Detection of subarachnoid haemorrhage with magnetic resonance imaging. *J Neurol Neurosurg and Psychiatry* 2001;**70**:205–11.
- 16 **Barrows Lj**, Hunter FT. The nature and clinical significance of pigments in the cerebrospinal fluid. *Brain* 1955;**78**:59–80.
- 17 **Griffiths W**, Crook M, Eldridge P, *et al*. A survey of routine biochemical investigations in South Thames. Proceedings ACB national meeting, Manchester, 2002:61–2.
- 18 **Patel MK**, Clarke MA. Lumbar puncture and subarachnoid haemorrhage. *Postgrad Med J* 1986;**62**:1021–4.
- 19 **French JK**, Glasgow GL. Lumbar Puncture in subarachnoid haemorrhage: yes or no? *N Z Med J* 1985;**98**:383–4.
- 20 **Walton JN**. *Subarachnoid haemorrhage*. Edinburgh: Livingstone, 1956.
- 21 **Vermeulen M**, Hasan D, Blijenberg BG, *et al*. Xanthochromia after subarachnoid haemorrhage needs no revisitation. *J Neurol Neurosurg Psychiatry* 1989;**52**:826–8.
- 22 **Buruma OJS**, Janson HLF, Den Bergh FAJTM, *et al*. Blood-stained cerebrospinal fluid: traumatic puncture or haemorrhage? *J Neurol Neurosurg Psychiatry* 1981;**44**:144–7.
- 23 **Cruikshank AM**. CSF spectrophotometry in the diagnosis of subarachnoid haemorrhage. *J Clin Pathol* 2001;**54**:827–30.