

CASE REPORT

A novel treatment for symptomatic carotid dissection

T Joseph, N Kandiyil, D Beale, C Tiivas, C H E Imray

Postgrad Med J 2005;81:e6 (<http://www.postgradmedj.com/cgi/content/full/81/958/e6>). doi: 10.1136/pgmj.2004.029421

Carotid dissection is a rare but significant cause of stroke. The neurological damage in such cases is mainly attributable to thromboembolism.¹ Current treatment includes supportive therapy and antiplatelet agent either alone or with anticoagulation. This is not supported by randomised trials² but it is logical. Presence of microemboli in cerebral circulation is a risk factor for ischaemic stroke after transient ischaemic attack (TIA)³ and transcranial Doppler examination (TCD) can detect them in middle cerebral artery circulation.⁴ Controlling microemboli improves the outcome in recurrent TIA and after carotid endarterectomy.^{5,6} We found this strategy effective in the treatment of a symptomatic carotid dissection unresponsive to anticoagulation.

We report a case of carotid artery dissection treated successfully by controlling microemboli from the dissected artery and discuss its validity.

CASE REPORT

A 45 year old, right handed man presented with a severe left sided headache, fluctuating weakness, and numbness in his right arm. He also had temporary loss of vision in his left eye and dysphasia. He reported a twisting movement of his neck eight days before this. In the past he had migraine and he was hypertensive.

Physical examination confirmed expressive dysphasia, mild weakness of his right arm muscles, and impaired sensation. His pulse was regular and his blood pressure was normal.

He had normal blood parameters including lipids. Aspirin and clopidogrel were started after confirming multiple low attenuation areas in the left frontoparietal cortex on a computed tomogram. A duplex scan of carotid arteries showed normal extracranial arteries but there was high resistance waveform, consistent with distal obstruction suggesting subintimal dissection (fig1). This was confirmed by magnetic resonance angiogram (figs 2 and 3). Therefore heparin infusion was started.

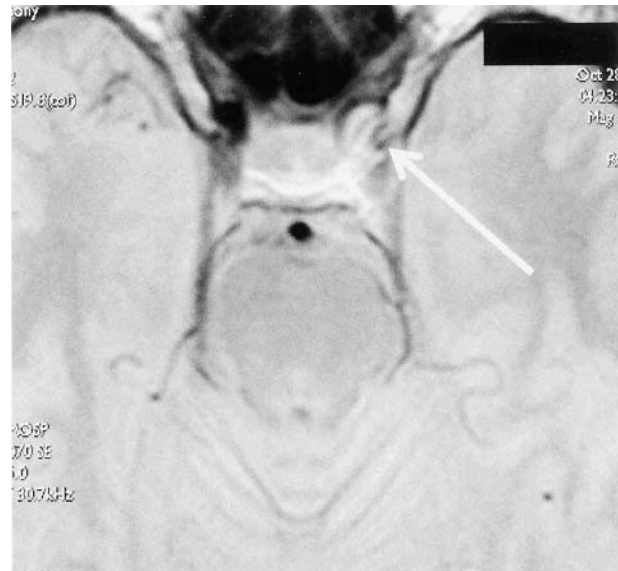


Figure 2 MRI of left internal carotid artery with the site of dissection at the base of skull.

He continued to have fluctuating neurological symptoms despite adequate anticoagulation. This prompted a TCD that showed microemboli in his left middle cerebral artery (MCA) circulation at a rate of 48 per hour. Thus a thromboembolic stroke secondary to carotid dissection was diagnosed.

Further treatment was discussed between radiologists, neurologists, and vascular surgeons. We decided to control microemboli with Dextran therapy based on local experience.

Abbreviations: TIA, transient ischaemic attack; TCD, transcranial Doppler examination; MCA, middle cerebral artery

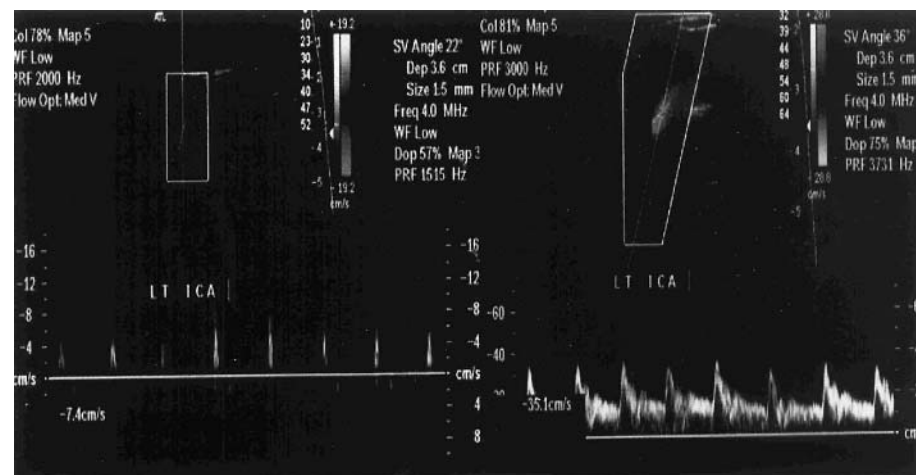


Figure 1 Wave forms from duplex scan of left carotid system. The left half shows the waveform on presentation, suggestive of distal obstruction. On the right half normal waveform from a repeat scan is shown and this suggests re-canalisation of the dissected segment.

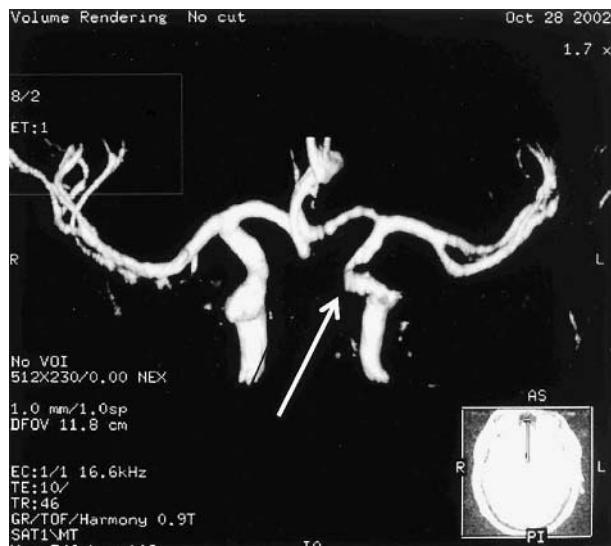


Figure 3 Reconstruction of the carotid system and the focal reduction in diameter of left internal carotid artery, suggestive of dissection.

He was given Dextran 40 as per the local protocol*. The fluctuating neurological symptoms settled and a repeat TCD showed no microemboli. Heparin infusion was stopped immediately. Dextran infusion was stopped after eight days. The patient recovered fully and was discharged receiving treatment with aspirin 150 mg and clopidogrel 75 mg. Coumarin was not given for fear of bleeding.

He was readmitted two weeks later with recurrent symptoms. Computed tomography showed no intracranial bleed and TCD scan detected microemboli in left the MCA. Dextran infusion improved his symptoms once again and stopped the microembolisation. He was given warfarin (target INR 2–3) on discharge. Repeat Duplex showed resolution of the high resistance waveform, indicating re-canalisation (fig 1).

DISCUSSION

The incidence of spontaneous carotid artery dissection is 2.5–3/100 000 per year.⁶ This accounts for 2% of ischaemic strokes⁷ but in young people carotid artery dissection causes up to 20% of strokes. The incidence is equal in both sexes and peaks in the fifth decade.

Factors such as severity of stenosis caused, site of the dissection, and extent of collaterals influence the clinical picture and prognosis. Within a month after the dissection up to 80% patients develop focal neurological deficit. The long term prognosis is good, with re-canalisation of the artery. Early pathogenesis of neurological deficit in carotid dissections is unclear but 90% of infarcts are attributable to thromboembolic events rather than reduced flow. Medical treatment includes anticoagulation with heparin followed by coumarin or solely antiplatelet agents.^{1,2} Surgery or endovascular approach is considered in unresponsive patients.

TCD assesses velocity of flow in MCA and detects transient microembolic signals in it. Mollina *et al* found microemboli in 13 of 28 acute dissections. Six of 13 with emboli showed neurological deterioration, whereas only 1 of 15 without emboli deteriorated.⁸ Microemboli are a frequent phenomenon after acute stroke, and continue for some days. These

* 20 ml bolus followed by a continuous infusion at a rate of 20 ml/h and increments of 20 ml/h until microemboli are controlled or to a maximum of 100 ml/h.

microemboli are a significant independent predictor of early ischaemic recurrence in patients with stroke or TIA.³ A similar association between stroke and microemboli is established from studies on patients with significant carotid stenosis and after carotid endarterectomy. Postoperative microemboli are usually platelet aggregates generated by the exposed thrombogenic vessel wall. These aggregates may develop into occlusive thromboemboli causing infarcts. A similar mechanism may explain symptoms after carotid dissection. TCD directed Dextran treatment to control microemboli after carotid endarterectomy and in patients with recurrent TIA is shown to be effective in preventing neurological events.^{4,5} Therefore the same treatment strategy was offered for this patient.

Dextran is a polysaccharide used mainly as a volume expander. Dextran with molecular weight below 60 000 inhibits erythrocyte aggregation by increasing the electro-negativity of the cells. It also changes the electrical potential of the endothelium. Dextran inhibits platelet aggregation in vitro and adenosine diphosphate induced aggregation in vivo. It is believed to suppress factor VIII activity by an effect on von Willibrand factor. Clots formed in the presence of dextran are lysed easily and Dextran increases the anti-plasmin activity. Dextran induced haemodilution leading to reduced viscosity and passive dilatation of microvessels attributable to the colloid osmotic effect adds to its effectiveness in thromboprophylaxis. The exact dosing and timing of administration are still not clear. A dose of 1.5 g/kg body weight is considered safe. Side effects include cardiac overload, haemorrhagic complications, anaphylactoid reactions, and renal dysfunction.⁹

The treatment of this patient was an act of desperation helped with background knowledge of TCD directed Dextran therapy to control microemboli. While we agree that the combination of antiplatelet agents together with the effect of already infused heparin before the introduction of intravenous Dextran does compound the temporal relation noted with the clinical improvement and disappearance of microemboli on the first occasion, it is worth noting that the improvement was maintained despite stopping the heparin and this temporal correlation was reproduced on re-admission. Because most infarcts in carotid dissections are attributable to thromboemboli it may well be reasonable to recommend TCD examination in symptomatic cases of internal carotid artery dissection to identify those patients who are at risk from microemboli. Controlling the microemboli with Dextran 40 infusion seems to give immediate protection, particularly when adequate heparinisation fails to control symptoms, as happened in this case.

Authors' affiliations

T Joseph, N Kandiyil, D Beale, C Tiivas, C H E Imray, University Hospitals of Coventry and Warwickshire, Walsgrave Hospital, Coventry, UK

Funding: none.

Competing interests: none.

Correspondence to: Mr T Joseph, 46 Unitt Drive, Liberty Walk, B64 6DB; TJo5366012@aol.com

Submitted 5 October 2004

Accepted 19 November 2004

REFERENCES

- Schievink WI. Spontaneous dissection of the carotid and vertebral arteries. *N Engl J Med* 2001;**344**:898–906.
- Lyrer P, Engelter S. Antithrombotic drugs for carotid artery dissection. *Cochrane Library*. Issue 4. Oxford: Update Software, 2000.

- 3 **Valton L**, Larrue V, Pavy le Traon A, *et al*. Microembolic signals and risk of early recurrence inpatients with stroke or transient ischemic attack. *Stroke* 1998;**29**:2125–8.
- 4 **Lennard NS**, Vijayasekar C, Tiivas, *et al*. Control of emboli in patients with recurrent or crescendo transient ischaemic attacks using preoperative transcranial Doppler-directed Dextran therapy. *Br J Surg* 2003;**90**:166–70.
- 5 **Naylor AR**, Hayes PD, Allroggen H, *et al*. Reducing the risk of carotid surgery: a 7-year audit of the role of monitoring and quality control assessment. *J Vasc Surg* 2000;**32**:750–9.
- 6 **Schievink WI**, Mokri B, Whisnant JP. Internal carotid artery dissection in a community: Rochester, Minnesota, 1987–1992. *Stroke* 1993;**24**:1678–80.
- 7 **Schievink WI**, Mokri B O'Fallon WM. Recurrent spontaneous cervical artery dissection. *N Engl J Med* 1994;**330**:393–7.
- 8 **Molina CA**, Alvarez-Sabin J, Schonewille W, *et al*. Cerebral microembolism in acute spontaneous internal carotid dissection. *Neuroimaging* 2001;**11**:63–6.
- 9 **Bergqvist D**. Dextran. In: Verstraete M, Fuster V, Topol EJ, eds. *Cardiovascular thrombosis: thrombocardiology and thromboneurology*. 2nd ed. Philadelphia: Lippincott-Raven, 1998:235–50.
- 10 **Consensus committee of the ninth international cerebral hemodynamic symposium**. Basic identification criteria of Doppler microembolic signals. *Stroke* 1995;**26**:1123.