

# British Thoracic Society guidelines for the management of suspected acute pulmonary embolism

British Thoracic Society Standards of Care Committee Pulmonary Embolism Guideline Development Group\*

*Thorax* 2003;58:470–484

## INTRODUCTION

In 1997 the British Thoracic Society (BTS) published advice entitled “Suspected acute pulmonary embolism: a practical approach”.<sup>1</sup> It was recognised that it would need updating within a few years. Subsequent publications in several areas (CT pulmonary angiography, D-dimer, clinical probability, low molecular weight heparin) now provide sufficient evidence to allow this advice to be updated as guidelines.

All the relevant literature published from January 1997 to December 2002 was located by searching the Medline and EmBase databases; some were meta-analyses and some were evidence based practice guidelines. Relevant papers published before 1997 not referenced in the earlier document were also retrieved.

As before, the text was compiled by members of the BTS on behalf of its Standards of Care Committee, with feedback from experts recommended by specialist societies and, as with the previous guideline, we approached international authorities who all readily agreed to comment on the drafts. We are indebted to these advisors.

These guidelines supersede the 1997 document, but many of the earlier concepts remain relevant. Where allusions are made to the previous document, this is shown as the page number in curly brackets {S18}. Papers from that document are not cited in the reference list, which therefore refers almost exclusively to publications from 1997 onwards. A similar structure to that in the previous guideline has been used, comprising a reference section, summary of recommendations, and a practical section for junior doctors.

It was decided that the updated guidelines would concentrate on suspected pulmonary embolism (PE) and only include deep vein thrombosis (DVT) where relevant, even though both are part of venous thromboembolism (VTE). Compared with DVT alone, PE is potentially more serious and has a differential diagnosis of other serious conditions; many hospitals have established local protocols for the diagnosis and treatment of DVT but not for suspected PE. Although VTE is common in hospitalised patients, recommendations on prophylaxis are beyond the scope of these guidelines.

Each section of these guidelines is followed by recommendations, graded according to standard criteria.<sup>2,3</sup> The Appendix contains charts (with notes) designed to be modified, according to local consensus and facilities, for inclusion in hospital handbooks.

Each acute hospital should consider implementing the recommendations summarised in the box. Suggested topics for local audit are:

- adherence to agreed hospital protocol
- appropriate use of D-dimer, particularly in the emergency department
- adequacy of clinical information provided with imaging requests
- patient outcomes.

## RISK FACTORS

Predisposing factors for VTE are summarised in table 1, derived from previous {S4} and subsequent information.<sup>4–15</sup> However, the previous association with cigarette smoking has not been confirmed.<sup>16</sup> The risk of VTE rises exponentially with age,<sup>10,13</sup> but it is unclear to what extent this is an independent risk factor. The widespread use of prophylaxis in orthopaedic<sup>17</sup> and general surgery has substantially reduced the incidence of post-operative VTE.

VTE associated with travel is a topical issue; while the case remains to be proved,<sup>18</sup> it is likely that air and road travel, particularly with longer journeys, is associated with a 2–4-fold increased risk.<sup>19–22</sup>

The increased risk with oestrogen therapy {S5} has been confirmed,<sup>23–25</sup> especially with “third generation” agents.<sup>8,26,27</sup> Three large studies<sup>28–30</sup> showed PE in 1–2 of 7000 pregnancies, less than previously supposed; the majority occurred post-partum, particularly with pre-eclampsia, Caesarean section, and multiple births.

Testing for thrombophilia (which may be inherited or acquired) will identify haemostatic abnormalities (especially antiphospholipid syndrome and deficiencies of antithrombin III, factor V Leiden, protein C, or protein S) in 25–50% of patients with VTE.<sup>24,31,32</sup> Usually these need to interact with acquired risk factors before thrombosis occurs,<sup>6</sup> being otherwise uncommonly associated with idiopathic VTE.<sup>33</sup> For example, the factor V (Leiden) defect, present in 5% of the population and 20% of patients presenting with thrombosis, in isolation increases the risk of VTE by 3–5-fold but, in conjunction with oestrogen therapy, this rises to 35-fold. However, the number to test to prevent an episode of VTE would be very high and, following such an event, oestrogens would be discontinued anyway. Secondly, screening for thrombophilia in pregnancy has been advocated, but even though factor V Leiden mutation is common in pregnant patients

\*Guideline Development Group: I A Campbell (also Royal College of Physicians), A Fennerty, A C Miller (Chairman)

UK advisors: T Baglin (Royal College of Pathologists & British Society for Haematology), S Gibbs (British Cardiac Society), H Gray (British Nuclear Medicine Society), D Hansell (Royal College of Radiologists), J Reid (Royal College of Radiologists)

International advisors: H Bounameaux (Switzerland), M Remy-Jardin (France), P Wells (Canada)

Correspondence to: Dr A C Miller, Mayday Hospital, Croydon CR7 7YE, UK; andrew.miller@mayday.nhs.uk

## Summary of recommendations

### Clinical

- All patients with possible PE should have clinical probability assessed and documented. [C]
- An alternative clinical explanation should always be considered at presentation and sought when PE is excluded. [C]

### D-dimer

- Blood D-dimer assay should only be considered following assessment of clinical probability. [B]
- D-dimer assay should not be performed in those with high clinical probability of PE. [B]
- A negative D-dimer test reliably excludes PE in patients with low (SimpliRED, Vidas, MDA) or intermediate (Vidas, MDA) clinical probability; such patients do not require imaging for VTE. [B]
- Each hospital should provide information on sensitivity and specificity of its D-dimer test. [C]

### Imaging

- CTPA is now the recommended initial lung imaging modality for non-massive PE. [B]
- Patients with a good quality negative CTPA do not require further investigation or treatment for PE. [A]
- Isotope lung scanning may be considered as the initial imaging investigation providing (a) facilities are available on site, and (b) chest radiograph is normal, and (c) there is no significant symptomatic concurrent cardiopulmonary disease, and (d) standardised reporting criteria are used, and (e) a non-diagnostic result is always followed by further imaging. [B]
- Where isotope lung scanning is normal, PE is reliably excluded [B] but a significant minority of high probability results are false positive. [B]
- In patients with coexisting clinical DVT, leg ultrasound as the initial imaging test is often sufficient to confirm VTE. [B]
- A single normal leg ultrasound should not be relied on for exclusion of subclinical DVT. [B]

### Massive PE

- CTPA or echocardiography will reliably diagnose clinically massive PE. [B]
- Thrombolysis is the first line treatment for massive PE [B] and may be instituted on clinical grounds alone if cardiac arrest is imminent [B]; a 50 mg bolus of alteplase is recommended. [C]
- Invasive approaches (thrombus fragmentation and IVC filter insertion) should be considered where facilities and expertise are readily available. [C]

### Treatment

- Thrombolysis should not be used as first line treatment in non-massive PE. [B]
- Heparin should be given to patients with intermediate or high clinical probability before imaging. [C]
- Unfractionated heparin (UFH) should be considered (a) as a first dose bolus, (b) in massive PE, or (c) where rapid reversal of effect may be needed. [C]
- Otherwise, low molecular weight heparin (LMWH) should be considered as preferable to UFH, having equal efficacy and safety and being easier to use. [A]
- Oral anticoagulation should only be commenced once VTE has been reliably confirmed. [C]
- The target INR should be 2.0–3.0; when this is achieved, heparin can be discontinued. [A]
- The standard duration of oral anticoagulation is: 4–6 weeks for temporary risk factors [A], 3 months for first idiopathic [A], and at least 6 months for other [C]; the risk of bleeding should be balanced with that of further VTE. [C]

### Other

- Imaging should be performed within 1 hour in massive PE, and ideally within 24 hours in non-massive PE. [C]
- Testing for thrombophilia should be considered in patients aged under 50 with recurrent PE or in those with a strong family history of proven VTE. [C]
- Investigations for occult cancer are only indicated in idiopathic VTE when it is suspected clinically, on chest radiography, or on routine blood tests. [C]
- Current organisation for outpatient management of DVT should be extended to include stable patients with PE. [C]

with VTE,<sup>34</sup> its presence leads to VTE in less than 1 in 400 pregnancies.<sup>28</sup> Thirdly, detecting one of the common thrombophilias does not predict a higher rate or earlier recurrence of VTE.<sup>35–37</sup> For these reasons there are few situations in which testing for thrombophilia can be clearly recommended<sup>38–39</sup>; however, it may be worthwhile in (a) patients aged under 50 years presenting with recurrent idiopathic PE since half will be positive,<sup>40</sup> and (b) where symptomatic VTE has been proved in several family members in more than one generation.

There is an increased risk of cancer being detected within 6–12 months of a first episode of VTE, particularly in those with no other risk factors and/or recurrent episodes.<sup>41–45</sup> Previously unrecognised cancer, present in 7–12% of those with idiopathic VTE, can usually be detected by a combination of careful clinical assessment, routine blood tests, and chest radiography<sup>41–46–47</sup> and, if these are satisfactory, the current consensus is that it is not appropriate to proceed to tests such as ultrasound, CT scanning, or endoscopy. Moreover, in one large study the 1 year survival of patients with occult cancer was only 12% because most had regional or distant spread at

diagnosis<sup>48</sup> (the occurrence of VTE in patients already known to have cancer is similarly a poor prognostic factor<sup>49</sup>).

- **Testing for thrombophilia should be considered in patients aged under 50 with recurrent PE or in those with a strong family history of proven VTE.** [C]
- **Investigations for occult cancer are only indicated in idiopathic VTE when it is suspected clinically, on chest radiography, or on routine blood tests.** [C]

### CLINICAL FEATURES

Large community studies show that the overall annual incidence of PE is 60–70 cases/100 000.<sup>10–50</sup> Half of these patients develop VTE while in hospital or in long term care, and the rest are equally divided between idiopathic cases and those with recognised risk factors.<sup>51</sup> In both these and in less representative series,<sup>52–56</sup> in-hospital mortality rates ranged from 6% to 15%. In the most comprehensive and representative cohort,<sup>57</sup> of the 814 who initially survived, 7% died within 1 week, 13% within 1 month, and 18% by 3 months. All found that a high proportion of early deaths are directly due to PE in spite of standard treatment. Adverse prognostic factors

**Table 1** Risk factors for venous thromboembolism

Major risk factors (relative risk 5–20):	
Surgery*	<ul style="list-style-type: none"> <li>• Major abdominal/pelvic surgery</li> <li>• Hip/knee replacement</li> <li>• Postoperative intensive care</li> </ul>
Obstetrics	<ul style="list-style-type: none"> <li>• Late pregnancy</li> <li>• Caesarian section</li> <li>• Puerperium</li> </ul>
Lower limb problems	<ul style="list-style-type: none"> <li>• Fracture</li> <li>• Varicose veins</li> </ul>
Malignancy	<ul style="list-style-type: none"> <li>• Abdominal/pelvic</li> <li>• Advanced/metastatic</li> </ul>
Reduced mobility	<ul style="list-style-type: none"> <li>• Hospitalisation</li> <li>• Institutional care</li> </ul>
Miscellaneous	<ul style="list-style-type: none"> <li>• Previous proven VTE</li> </ul>
Minor risk factors (relative risk 2–4):	
Cardiovascular	<ul style="list-style-type: none"> <li>• Congenital heart disease</li> <li>• Congestive cardiac failure</li> <li>• Hypertension</li> <li>• Superficial venous thrombosis</li> <li>• Indwelling central vein catheter</li> </ul>
Oestrogens	<ul style="list-style-type: none"> <li>• Oral contraceptive</li> <li>• Hormone replacement therapy</li> </ul>
Miscellaneous	<ul style="list-style-type: none"> <li>• COPD</li> <li>• Neurological disability</li> <li>• Occult malignancy</li> <li>• Thrombotic disorders</li> <li>• Long distance sedentary travel</li> <li>• Obesity</li> <li>• Other†</li> </ul>

\*Where appropriate prophylaxis is used, relative risk is much lower.  
 †Inflammatory bowel disease, nephrotic syndrome, chronic dialysis, myeloproliferative disorders, paroxysmal nocturnal haemoglobinuria, Behçet's disease.

include clinically major embolism, cancer, congestive cardiac failure, and previous or current DVT.<sup>57–58</sup> Non-fatal recurrence, particularly in the first year, is common in those with disabling neurological disease and cancer, and least likely in those with temporary risk factors.<sup>59</sup>

As reported before {S8}, the many abnormalities observed on clinical examination and routine investigations, particularly in the more severe cases, are of limited value in confirming a diagnosis of PE.<sup>60–70</sup> Even in those with confirmed proximal DVT, respiratory symptoms are a poor predictor of concurrent PE.<sup>71</sup>

A new observation is that acute right heart strain in major PE can be detected by the release of cardiac troponin<sup>72–78</sup> due to right ventricular muscle damage<sup>79–80</sup>; although such measurements may give prognostic information,<sup>77–78</sup> their role in decision making is limited and they are of no diagnostic value in non-massive PE.<sup>81</sup>

The value of making an assessment of clinical probability was highlighted previously {S7} because it encourages good clinical assessment and allows better interpretation of isotope scan results; a new advantage is that, in combination with D-dimer assay, it can substantially reduce the need for imaging. The PIOPED observation that PE is only present in 9% of those with low clinical probability has, with two exceptions,<sup>82–83</sup> been confirmed in several large studies,<sup>84–91</sup> giving a negative predictive value of 89–96%. All these surveys involved experienced clinicians using defined criteria for assessing clinical probability under a research protocol. This is very different from the emergency room situation where decisions are often made by junior doctors whose ability to make an accurate estimate of the likelihood of PE is much less than that of their seniors.<sup>92</sup> A simple and effective method of assigning clinical probability is therefore desirable. The method previously recommended {S17} has the advantage of simplicity. It was based on principles introduced successfully for DVT by a Canadian group who have since shown it to be equally valid and reproducible in PE,<sup>84–93–94</sup> and it has

independently been suggested elsewhere.<sup>95</sup> It requires that the patient has clinical features compatible with PE—namely, breathlessness and/or tachypnoea, with or without pleuritic chest pain and/or haemoptysis {S6}. Two other factors are sought: (a) the absence of another reasonable clinical explanation, and (b) the presence of a major risk factor. Where (a) and (b) are both true the probability is high; if only one is true the probability is intermediate; and if neither is true the probability is low. Some hospitals prefer a scoring system that places patients into one of only two categories—PE likely and PE unlikely. Several such attempts have been made,<sup>87–93–96–97</sup> but these are either inaccurate or require a complex scoring system that is difficult to remember, a criticism of other recent<sup>85–89–98</sup> and previous such approaches; their superiority over simpler clinical assessment may also be marginal.<sup>89–91</sup>

- **All patients with possible PE should have clinical probability assessed and documented. [C]**
- **An alternative clinical explanation should always be considered at presentation and sought when PE is excluded. [C]**

## INVESTIGATIONS

### D-dimer

Following previous uncertainty {S11}, evidence is accumulating that D-dimer assays may have an important role in accurately excluding PE. On the other hand, raised levels of D-dimer do not infer the presence of VTE because such results are commonly found in hospitalised patients,<sup>83–99</sup> obstetrics,<sup>100</sup> peripheral vascular disease, cancer, and many inflammatory diseases, as well as increasing age. Several new systems offer improved sensitivities and a low incidence of false negatives; not surprisingly, false negative results are more common in those with subsegmental than larger emboli.<sup>101</sup> A meta-analysis of studies looking at the newer second generation rapid D-dimer tests found sensitivities of 87–98%,<sup>102</sup> but all have poor specificity—that is, a substantial number of false positives.

Three systems have been studied in large clinical studies of PE. A qualitative red cell agglutination (SimpliRED) test was used in 1177 patients<sup>103</sup> with a test specificity of 68%. The overall negative predictive value (85%) was much higher (97%) in those with low clinical probability, and the combination of low clinical probability and negative SimpliRED D-dimer occurred in 44% of the cohort. Furthermore, a negative test also proved useful in patients with intermediate clinical probability and an indeterminate isotope lung scan. The value of combining clinical probability assessment and SimpliRED assay has been confirmed recently.<sup>104</sup> Although a rapid test, it should be performed in the laboratory and not by the bedside.<sup>105</sup>

A second investigation used the rapid quantitative ELISA (Vidas) test in 918 patients with suspected PE (n=444) or DVT.<sup>106</sup> Only those with a positive test were subsequently investigated, and treatment was withheld in the remaining 280; two had objectively confirmed VTE in the subsequent 3 months. This test, one of the most sensitive in head-to-head comparisons,<sup>107</sup> has the potential advantage over SimpliRED in that it is also useful in those with intermediate clinical probability, but its lower specificity meant that imaging became unnecessary in only 29%, similar to the results of another group.<sup>83</sup> As with all such tests, sensitivity and specificity need to be considered in conjunction with prevalence of disease in the population being studied<sup>108–109</sup> which, in studies of PE, varies between 15% and 40%. With a PE prevalence of 20%, it can be excluded by negative D-dimer in one patient for every 1.8 tested using SimpliRED (if low clinical probability) or 3.0 using Vidas (if low/intermediate clinical probability).

Unlike previous latex tests {S11}, the MDA D-dimer test seems promising because, as well as having a specificity of

45%, a negative test excludes VTE in those with both intermediate and low clinical probability.<sup>110</sup> Other tests appear potentially useful.<sup>83 111–113</sup> The Medical Devices Agency is currently comparing 10 D-dimer assays in patients with suspected VTE, and other studies in Europe and North America are likely to clarify which are the most useful and reliable in limiting the number of imaging tests needed to exclude PE and in avoiding unnecessary hospital admissions. The assay chosen must have a high negative predictive value, have been validated in a management study, and take into account pre-test probability.

A potentially important study found that, if D-dimer levels are normal following cessation of anticoagulation, recurrence of idiopathic VTE is very unlikely.<sup>114</sup>

- **Blood D-dimer assay should only be considered following assessment of clinical probability. [B]**
- **D-dimer assay should not be performed in those with high clinical probability of PE. [B]**
- **A negative D-dimer test reliably excludes PE in patients with low (SimpliRED, Vidas, MDA) or intermediate (Vidas, MDA) clinical probability; such patients do not require imaging for VTE. [B]**
- **Each hospital should provide information on sensitivity and specificity of its D-dimer test. [C]**

### Imaging

#### Isotope lung scanning

The PIOPED finding that PE can only be diagnosed or excluded reliably in a minority of patients by isotope lung scanning {S7} has been confirmed,<sup>115 116</sup> and continuing attempts to refine technology<sup>117</sup> and to redefine interpretative criteria<sup>118 119</sup> will not materially improve this. Hence, the proposition {S9, 14} that further imaging is mandatory in all those with either an indeterminate lung scan or discordant clinical and lung scan probability continues to be emphasised.<sup>120</sup> Nevertheless, clinicians frequently ignore such advice<sup>121–123</sup> and, where in doubt, consider that it is better to treat than not.<sup>116 124–128</sup> In a recent Dutch study PE was adequately confirmed or excluded in only 11% until an agreed national consensus was introduced but, even so, this figure then rose only to 55%.<sup>129</sup> and overall improvements nationally were also disappointing.<sup>122</sup>

It is still not universally realised that a normal scan reliably excludes PE.<sup>122 130–132</sup> On the other hand, it is commonly concluded that a high probability lung scan is diagnostic of PE, although the PIOPED investigation showed this to be incorrect {S7} (some false positives were found in those with previous rather than current PE) and this has recently been confirmed.<sup>132</sup> An indeterminate result is very common in those with symptomatic co-existing cardiopulmonary disease {S9}<sup>133</sup>—including acute or chronic airways disease and conditions causing intrapulmonary shadowing on the chest radiograph—and in the elderly<sup>87</sup>; it is also in these categories where interobserver variability is highest.<sup>134</sup> This partly accounts for the finding that half of patients with an abnormal chest radiograph need further imaging<sup>133 135</sup>; this is much less likely when the chest radiograph is normal, but this only applies to a small number of those investigated for possible PE.<sup>135 136</sup>

Although national guidelines have been published on technical aspects of isotope lung scanning,<sup>137</sup> there is no agreed consistent terminology for reporting, particularly in those of low and “intermediate” probability, and clinicians may reach erroneous conclusions.<sup>126 130 138</sup> A valid interpretation is only possible when the following principles are followed<sup>139</sup>:

- (1) a contemporaneous good quality erect chest radiograph should be available so that other clinical conditions that can cause ventilation/perfusion defects are not overlooked; and
- (2) in abnormal lung scans knowledge of clinical probability is essential in interpreting the report's *meaning* but must not influence its *description*.

The practice of 25 nuclear medicine departments in south-east England over a 1 year period (1999–2000) has been analysed<sup>140</sup>; there were 200 isotope lung scans per 100 000 population. In spite of a survey 5 years earlier which generated agreed guidelines, a third of units did not always have a current chest radiograph available, a third were unable to complete and report the test within 24 hours of request, three quarters did not have clinical probability included on the request form, and few had an out-of-hours emergency service. Similar variations are likely to be present nationally. Although most district general hospitals in the British Isles have access to isotope lung scanning, over a third do not have this available on site.<sup>121</sup>

- **Isotope lung scanning may be considered as the initial imaging investigation providing (a) facilities are available on site, and (b) chest radiograph is normal, and (c) there is no significant symptomatic concurrent cardiopulmonary disease, and (d) standardised reporting criteria are used, and (e) a non-diagnostic result is always followed by further imaging. [B]**
- **Where isotope lung scanning is normal, PE is reliably excluded [B] but a significant minority of high probability results are false positive. [B]**

#### Leg ultrasound

Because 70% of patients with proven PE have proximal DVT {S4}, leg ultrasound has been used in suspected PE (a) as an initial test in those with a clinical DVT, (b) as an initial test in all patients to reduce the need for lung imaging, and (c) after lung imaging, particularly isotope lung scanning, has given inconclusive information. Identification of DVT precludes the need for further tests. However, there seems to be insufficient awareness of the limited accuracy of compression ultrasound in detecting asymptomatic proximal DVT. In four recent studies proximal clot was found in only 23–52% of patients with confirmed PE.<sup>141–144</sup> This compares with a figure of 60% using venography,<sup>145</sup> with distal thrombus in a further 22%. A study of patients with non-diagnostic isotope lung scans and a single negative leg ultrasound scan found that one third did have PE on pulmonary angiography<sup>146</sup>; similar results were reported in those with a low probability lung scan.<sup>147</sup> Although it is safe to withhold anticoagulation in patients with suspected DVT and a single negative leg ultrasound scan, these results cannot yet be extrapolated to those presenting with possible PE.

An attractive justification for considering leg imaging in patients with suspected PE is that, if negative, anticoagulation to prevent recurrence might be unnecessary, as has been shown for patients presenting with suspected DVT and a single negative leg ultrasound scan.<sup>148</sup> In suspected PE, a 3 month VTE rate of only 0.5% has been found in such patients with negative leg imaging,<sup>84 149</sup> but the protocol required *serial* studies which has major resource implications. Using *one time* leg ultrasound scanning in those with low clinical probability and a non-diagnostic isotope lung scan, the recurrence rate in untreated patients was higher at 1.7%.<sup>86</sup> A negative *single* examination by ultrasound does not reliably exclude VTE in such patients, except in the few with no major risk factors and also no clinical DVT.<sup>150</sup> An alternative strategy is to perform both computed tomographic pulmonary angiography (CTPA) and leg ultrasound in all patients with suspected PE, as in a recent large French multicentre study where 7% of those without confirmed PE had proximal DVT only.<sup>91</sup> Such an approach has major resource implications.

- **In patients with co-existing clinical DVT, leg ultrasound as the initial imaging test is often sufficient to confirm VTE. [B]**
- **A single normal leg ultrasound should not be relied on for exclusion of subclinical DVT. [B]**

### Conventional pulmonary angiography

The above approaches were devised because of the very limited use of conventional pulmonary angiography due to a combination of patchy availability, limited radiological experience, and the perception of clinicians that this invasive test is potentially dangerous. It has been seen as the gold standard against which other imaging modalities have been historically evaluated, but it is not always recognised that, with subsegmental clot, interobserver disagreement {S10} occurs in up to one third of cases<sup>151</sup> and animal models that mimic this clinical situation have found sensitivity and positive predictive values of only 87–88% compared with necropsy.<sup>152</sup> A few centres have developed facilities and expertise for selective angiography and catheter fragmentation of large emboli.

### Computed tomographic pulmonary angiography (CTPA)

Our previous advice that conventional pulmonary angiography should be much more widely used {S14–15} has been rendered largely obsolete by the advent of CTPA. This has led to a revolution in diagnostic strategies and, in the UK, almost all hospitals currently lacking this technology<sup>121</sup> are being funded to acquire the latest generation of fast multi-slice scanners (in order to meet national targets for cancer diagnosis and staging). Technical aspects are fully described in recent textbooks.<sup>153–154</sup> CTPA is increasingly being used as an adjunct and, more recently, as an alternative to other imaging modalities, and is clearly superior in specificity to ventilation-perfusion isotope scanning.<sup>132–133–155–159</sup> It also allows a quantitative assessment which correlates well with clinical severity<sup>160–161</sup> and all investigators have found that, when PE is excluded, the true alternative diagnosis may be recognised. Interobserver agreement is good even with relatively inexperienced assessors,<sup>155–162–167</sup> and in patients with co-existing cardiorespiratory disease.<sup>168</sup>

Although studies comparing CTPA with conventional pulmonary angiography published before 2000 have been criticised on methodological grounds,<sup>169–171</sup> they are more numerous and robust than the studies which led to isotope lung scanning becoming an accepted diagnostic tool. Most early investigators used 5 mm collimation and single detector CT scanning which limited their accuracy,<sup>172</sup> but it is clear that results are better using defined protocols, thin section collimation, images being viewed at work stations, and familiarity with pitfalls in interpretation.<sup>165–173–174</sup> The main disadvantage of CTPA compared with conventional pulmonary angiography is that subsegmental clot is less likely to be seen. However, most patients also have more proximal clot that can be reliably identified—94–96% in four studies<sup>151–155–177</sup> although in a fifth it was only 78%.<sup>178</sup>—findings corroborated in an animal model.<sup>152</sup> Latest CT technology and techniques allow better identification of peripheral thrombus.<sup>177–179–180</sup> Meticulous attention to technique—for example, in the timing of contrast—is necessary to achieve results comparable to those in published series, in all of which a small proportion of examinations are technically unsatisfactory. As well as directly demonstrating intra-vascular thrombus, CTPA may show secondary effects such as wedge shaped opacities or characteristic right ventricular changes.<sup>181–182</sup>

There has been a recent trend to analyse the accuracy of CTPA using clinical outcome measures rather than comparison with conventional angiography, and data are accumulating that it is safe to withhold anticoagulation when PE is excluded on CTPA. Early evidence came from reports in which it was used in conjunction with other imaging modalities,<sup>183–186</sup> but three recent studies using CTPA alone found subsequent PE in only nine of 854 such patients (1.1%) by 3 months<sup>187–189</sup>; none of these studies used multi-slice scanners. This compares favourably with 3 month recurrence figures of 0.9% (7/796) for those with negative conventional

pulmonary angiograms<sup>190–193</sup> and 0.5% (6/1246) in patients with a normal isotope scan.<sup>149–150–187–193</sup> It is likely to be better with the latest generation of scanners and may approach the figure of 0.4% (4/993) found in a very large study using electron beam CT, a third of whom had PE.<sup>194</sup> In cancer patients with a high risk of PE, a negative CTPA is sufficient to exclude the diagnosis.<sup>195</sup>

In a large multicentre study in which all patients were investigated by both CTPA and leg ultrasound,<sup>91</sup> those with negative tests and low or intermediate clinical probability of PE were not anticoagulated and in the following 3 months only one of 507 (0.2%) had definite PE. The 76 patients with negative tests but high clinical probability of PE underwent further lung imaging which identified PE in four (5%), but none had major intrapulmonary clot, the effect of withholding anticoagulation was not assessed, and multi-slice CTPA was not used. Using the latter technology another French group reported only one recurrence by 3 months in 91 patients with a negative test who were not anticoagulated, and that was in an elderly patient known to have a DVT.<sup>177</sup>

Multi-slice scanners also allow the option of imaging leg veins during the same procedure. Comparison has mainly been made with ultrasound rather than venography and results have been mixed.<sup>196–204</sup> In a cohort of 541 patients with suspected PE the combined approach identified an additional 18% of patients where only the DVT could be identified,<sup>196</sup> whereas in two later studies this figure was under 8%.<sup>204–205</sup> Disadvantages include an increased radiation dose, particularly to the gonads,<sup>206</sup> and longer scanning time, and currently few UK radiology departments routinely perform such a combined examination.

Compared with isotope scanning, CTPA (a) is quicker to perform, (b) rarely needs to be followed by other imaging, (c) may provide the correct diagnosis when PE has been excluded, (d) is now available in most hospitals, and (e) is easier to arrange urgently out of hours. Although most clinicians and radiologists recognise that CTPA should be the preferred initial imaging modality in suspected PE, current resources make this impracticable. The pressure on CTPA examinations can be substantially alleviated by prior measurements of clinical probability and D-dimer and/or selective use of isotope scanning. In a recent British study of 779 patients with suspected PE (present in a quarter), perfusion lung scans were performed in those with both a normal chest radiograph and no significant chronic respiratory disease; since this was normal in 231, CTPA was unnecessary in 30% of the whole cohort and only 13% required both investigations.<sup>136</sup>

There are very few studies of imaging in patients with chronic cardiorespiratory disease, those who are already inpatients, and those with underlying critical illness. These pose a major diagnostic problem because few can be confidently classified as low clinical probability, D-dimer is often positive,<sup>83–168</sup> and isotope scans are usually non-diagnostic. Since isolated subsegmental thrombus could be dangerous in many of these patients, conventional angiography rather than CTPA has been advocated.<sup>207</sup> However, a recent report of patients with a high incidence of symptomatic cardiorespiratory conditions (one third with proven PE) showed that, of the 81 patients not anticoagulated following a negative CTPA, a proven non-fatal PE occurred within 3 months in only two and another two died of unknown causes.<sup>168</sup> In another similar study in 135 patients with chronic respiratory disease, two cases of presumed PE (both fatal) occurred by 3 months.<sup>208</sup> Neither group used multi-slice CTPA which gives good image quality in patients with chronic obstructive pulmonary disease, including down to the subsegmental level.<sup>177</sup>

- **CTPA is now the recommended initial lung imaging modality for non-massive PE. [B]**
- **Patients with a good quality negative CTPA do not require further investigation or treatment for PE. [A]**

## Other imaging modalities

### Echocardiography

Echocardiography is diagnostic in massive PE<sup>52 54 209 210</sup> but allows a firm diagnosis in only a minority of others.<sup>52 211 212</sup> Although it can give prognostic information, it is of less value in predicting mortality than clinical features or the presence of acidosis.<sup>213</sup> Use of the transoesophageal route improves diagnostic accuracy by more reliably demonstrating intrapulmonary and intracardiac thrombus and has been used during cardiopulmonary resuscitation,<sup>214</sup> but other advantages over the trans-thoracic approach are marginal<sup>215–218</sup> and availability is limited.

### Transthoracic ultrasound

Transthoracic ultrasound<sup>219–221</sup> accurately identifies peripheral wedge-shaped opacities due to focal pulmonary haemorrhage or infarction,<sup>222 223</sup> particularly in patients with pleuritic pain. This technique should be considered as an adjunct rather than an alternative to other imaging; it is not widely used.

### Magnetic resonance angiography

Magnetic resonance angiography appears promising both in human<sup>224 225</sup> and animal models.<sup>226–229</sup> It avoids ionising radiation but has poor sensitivity for subsegmental clot<sup>225 230</sup> and limited access is likely to continue for several years.

## Emergency imaging

Our previous recommendation that in “each acute hospital a strategy is developed for arranging urgent investigations in patients with life threatening PE” {S15} has been shown to be achievable.<sup>231</sup> We previously advocated transthoracic echocardiography {S18} which can be performed at the bedside. CTPA is now widely available and, in some hospitals, may be quicker to arrange out of hours. In major PE it reliably demonstrates both proximal thrombus and acute right ventricular dilatation<sup>181</sup> and, occasionally, interventricular septal displacement.<sup>232</sup> Should major PE be excluded, the correct diagnosis is usually evident with either test.

- **CTPA or echocardiography will reliably diagnose clinically massive PE. [B]**
- **Imaging should be performed within 1 hour in massive PE, and ideally within 24 hours in non-massive PE. [C]**

## TREATMENT

The pathophysiological processes occurring in acute PE have recently been described.<sup>233</sup> Supportive therapy {S12} includes oxygen and, in some patients, analgesia. In hypotensive patients it is common practice to use plasma expanders and inotropic support.<sup>213</sup> The effects of acute PE on right heart function due to arterial obstruction by thrombus are exacerbated by concomitant pulmonary vasoconstrictors, and animal studies on the effect of antagonists to these and of direct pulmonary vasodilators suggest that such agents have a potential future role in massive PE.<sup>234</sup>

### Thrombolysis and embolectomy

If there has been a massive PE—that is, one so severe as to cause circulatory collapse—recommended practice is to use thrombolysis, the earlier the better.<sup>235</sup> Evidence for reduction in mortality is sparse; two meta-analyses<sup>236 237</sup> found a single randomised controlled trial of thrombolysis versus heparin which was terminated when all four patients given thrombolysis survived while all four given heparin died.<sup>238</sup> Since massive non-fatal PE is uncommon and those who survive long enough to have imaging proof have a low mortality,<sup>56</sup> it is unlikely that robust evidence for reduced mortality with thrombolysis will materialise. In patients with right heart thrombus—in itself an ominous finding {S11}—mortality with thrombolysis is a third of that with heparin.<sup>239</sup>

In patients with non-massive PE opinions on thrombolysis still vary, particularly in patients with right ventricular

dysfunction.<sup>54 209 213 240–242</sup> In three multicentre registries 22–42% of patients without cardiogenic shock received thrombolysis.<sup>53–55</sup> One recent controlled study of patients with submassive PE found that emergency intervention was less likely in those given thrombolysis in addition to heparin, but there was no survival advantage.<sup>243</sup> Since the risk of major haemorrhage is twice that with heparin,<sup>237 244 245</sup> the current majority view remains {S14} that thrombolysis should be reserved for those with clinically massive PE. Thrombolysis is equally effective in the elderly,<sup>246</sup> although they have an increased risk of major bleeding, as do patients with intracranial disease or hypertension.<sup>247 248</sup>

Although expensive, alteplase has the advantages that it is widely available and, unlike streptokinase, does not worsen hypotension. The preparation of urokinase for unblocking vascular lines has a dose too low for use in PE. New synthetic compounds are being developed.<sup>249 250</sup> The dosage and administration of alteplase is the same as that familiar to junior doctors treating myocardial infarction. Streptokinase, which in PE used to be given over 12 hours, works better in PE if given in 2 hours.<sup>251 252</sup> Elegant experiments in dogs<sup>253</sup> have explained the clinical finding that thrombolysis is equally effective when given peripherally as when administered through a catheter positioned adjacent to the embolus<sup>254</sup>; the latter requires femoral artery cannulation with a high incidence of local bleeding.<sup>248 255</sup> Where there are absolute contraindications to thrombolysis—rarely an important consideration in a life threatening situation—or where it has failed and the patient is critically ill, large emboli can be successfully fragmented using mechanical techniques via a right heart catheter<sup>256–262</sup>; animal models have confirmed their efficacy.<sup>263</sup> Few centres can offer either this option or surgical embolectomy.<sup>264</sup>

The high mortality of PE in patients with acute right heart failure<sup>53 265</sup> is greatly increased when hypotension, acidosis, or cardiac arrest is also present.<sup>53 213 214 264 266</sup> PE accounts for 10% of patients admitted with non-traumatic sudden death and 50% of those arriving with electromechanical dissociation or asystole on ECG.<sup>267</sup> In spite of aggressive treatment, very few survive to discharge.<sup>268</sup> However, should cardiac arrest occur while in hospital and massive PE is strongly suspected clinically, an immediate intravenous bolus of 50 mg alteplase administered during cardiopulmonary resuscitation may be life saving, with the pulse returning within 3–30 minutes.<sup>269</sup> The value of extracorporeal membrane oxygenation in cardiac arrest due to PE is unclear.<sup>270</sup>

- **Thrombolysis is the first line treatment for massive PE [B] and may be instituted on clinical grounds alone if cardiac arrest is imminent [B]; a 50 mg bolus of alteplase is recommended. [C]**
- **Invasive approaches (thrombus fragmentation and IVC filter insertion) should be considered where facilities and expertise are readily available. [C]**
- **Thrombolysis should not be used as first line treatment in non-massive PE. [B]**

### Anticoagulation

In patients with PE, low molecular weight heparin (LMWH) compares as favourably with unfractionated heparin (UFH) as it does in those with DVT.<sup>271–273</sup> not only in efficacy and unwanted effects but also with respect to outpatient versus inpatient management.<sup>274–277</sup> It is likely that half of patients with PE could be managed without hospitalisation.<sup>274</sup> The frequency of major haemorrhage may be slightly higher in those managed as outpatients, but care with selection and risk factors should mitigate this possible difference in hazard.<sup>275</sup> Whereas the Cochrane review<sup>278</sup> concluded that “in patients with pulmonary embolism it might be prudent to await further results of new studies”, a more recent influential American consensus stated that “treatment of VTE with LMWH has come of age”.<sup>273</sup> Three questions remain:

(1) Can LMWH alone be given from the outset or should a bolus of UFH (with a quicker onset of action) also be given at the same time? In all but one of the PE studies LMWH has followed an initial period of UFH therapy; in the single exception, primarily a study of proximal DVT, only 15% of patients had symptoms and signs of PE but all had high probability lung scans.<sup>279</sup>

(2) Are the various LMWHs equivalent? There is no evidence to the contrary, but all agree that comparative studies are needed.<sup>273 275 278</sup> There is good evidence that once daily treatment is as effective as twice daily treatment regimens.<sup>280</sup>

(3) Does the equivalence of LMWH to UFH in the prevention of recurrence of PE extend beyond the period of anticoagulation?

Although LMWH allows outpatient treatment without the necessity for haematological monitoring, it has to be given parenterally. Preliminary work suggests that ximelagatran, a direct thrombin inhibitor, is a promising alternative, being effective in PE when given orally.<sup>281</sup>

There is little disagreement that anticoagulation with warfarin for 4–6 weeks is enough when PE has occurred in relation to a temporary risk factor.<sup>282–284</sup> Our previous advice {S12} that, for a first episode of idiopathic PE, treatment for 3 months is sufficient is consistent with recent findings<sup>285 286</sup>; a study recommending a longer period was somewhat atypical in design and in selection of patients.<sup>35</sup> However, the same evidence has been interpreted by North American authorities to advise treatment for 6 months.<sup>272 273</sup> This debate has stimulated an ongoing BTS multicentre study of a wide cross section of patients to compare anticoagulation for 3 and 6 months. In such patients decisions could be guided by a D-dimer assay after treatment.<sup>114</sup> There are insufficient data to recommend duration of treatment in recurrent idiopathic PE where clinical variables are likely to suggest appropriate decisions. In those with persisting risk factors current opinion advises indefinite anticoagulation, although there is an increased risk of bleeding and no reduction in mortality.<sup>40 273 287 288</sup> There are no data to suggest that duration of anticoagulation should be influenced by the severity of PE or the presence of DVT.

Bleeding on treatment is common in elderly patients with co-morbidity, particularly early in treatment.<sup>289 290</sup> A history of peptic ulcer disease is not, as previously thought {S13}, a risk factor although either a past history of gastrointestinal bleeding or concurrent use of aspirin is associated with higher bleeding rates.<sup>275 291</sup> Where there is a significant risk of major bleeding and proximal DVT has been excluded, withholding anticoagulation may be considered,<sup>292</sup> particularly in those with temporary risk factors. In all patients the risk of bleeding is related to both intensity and duration of anticoagulation.<sup>289 291 293</sup> With LMWH as initial treatment and oral anticoagulation delivering an international normalised ratio (INR) of 2.0–3.0, the rate of major bleeding at 3 months is  $\leq 3\%$ <sup>291</sup> and mortality is  $\leq 0.5\%$ .<sup>289 290</sup>

- **Heparin should be given to patients with intermediate or high clinical probability before imaging. [C]**
- **Unfractionated heparin (UFH) should be considered (a) as a first dose bolus, (b) in massive PE, or (c) where rapid reversal of effect may be needed. [C]**
- **Otherwise, low molecular weight heparin (LMWH) should be considered as preferable to UFH, having equal efficacy and safety and being easier to use. [A]**
- **Oral anticoagulation should only be commenced once VTE has been reliably confirmed. [C]**
- **The target INR should be 2.0–3.0; when this is achieved, heparin can be discontinued. [A]**
- **The standard duration of oral anticoagulation is: 4–6 weeks for temporary risk factors [A], 3 months for first idiopathic [A], and at least 6 months for other**

**[C]; the risk of bleeding should be balanced with that of further VTE. [C]**

- **Current organisation for outpatient management of DVT should be extended to include stable patients with PE. [C]**

### Inferior vena caval (IVC) filters

Inferior vena caval (IVC) filters are mainly used where anticoagulation is contraindicated or unsuccessful in preventing recurrence of PE from continuing DVT. Current opinion on their use to prevent PE displays less enthusiasm than previously.<sup>273 294</sup> The first randomised trial was published in 1998.<sup>295</sup> Filters were effective for the first 12 days but neither short nor long term mortality was improved and at 2 years the recurrence of DVT was greater in the filter groups. A large retrospective study<sup>296</sup> agreed that readmission for recurrent PE was unchanged and DVT was more common, as others have found.<sup>297</sup> The presumed advantages of removable filters remain to be proven.<sup>298</sup> If necessary—for example, in intensive care units—filters can be inserted at the bedside.<sup>299</sup>

### Special situations

#### Pregnancy

Current obstetric practice<sup>300–302</sup> is based on extrapolation from results in non-pregnant populations and on observational studies. Warfarin is teratogenic and should be avoided until after delivery; its use does not preclude breast feeding. Treatment during pregnancy should therefore be with therapeutic doses of LMWH<sup>303</sup> or subcutaneous calcium heparin. Approaching delivery, UFH should be substituted because its anticoagulant effect can more easily be reversed if necessary; there are different views about whether it should be discontinued or the dose reduced 4–6 hours before the expected time of delivery. It is advised that anticoagulation should continue for 6 weeks after delivery or for 3 months after the initial episode, whichever is the longer.

#### Cancer

In patients with cancer<sup>304–306</sup> initial treatment with heparin and warfarin is given in the standard manner, but the relative risk of recurrence is 3 and of bleeding is 6 compared with other patients.<sup>49 305</sup> In the absence of evidence from randomised trials in this population, duration of treatment is arbitrary. For those with recurrence in spite of adequate anticoagulation, options include: (a) aiming for a higher INR of 3.0–3.5 (which further increases the risks of bleeding), (b) switching to long term LMWH while continuing anticoagulation, or (c) inserting an IVC filter, the value of which is questionable.<sup>307</sup>

### REFERENCES

Where an article is published in a foreign language journal, this is identified in parentheses following the translated title; all have an English abstract.

- 1 **British Thoracic Society.** Suspected acute pulmonary embolism: a practical approach. *Thorax* 1997;**52**(Suppl 4):S1–24. Available from [http://www.brit-thoracic.org.uk/guide/download\\_guide.html#embolism](http://www.brit-thoracic.org.uk/guide/download_guide.html#embolism).
- 2 **Harbour R, Miller J.** A new system for grading recommendations in evidence based guidelines. *BMJ* 2001;**323**:334–6.
- 3 **Knottnerus JA, van Weel C, Muris JW.** Evaluation of diagnostic procedures. *BMJ* 2002;**324**:477–80.
- 4 **Goldhaber SZ, Grodstein F, Stampfer MJ, et al.** A prospective study of risk factors for pulmonary embolism in women. *JAMA* 1997;**277**:642–5.
- 5 **Hansson PO, Eriksson H, Welin L, et al.** Smoking and abdominal obesity: risk factors for venous thromboembolism among middle-aged men. *Arch Intern Med* 1999;**159**:1886–90.
- 6 **Rosendaal FR.** Venous thrombosis: a multifactorial disease. *Lancet* 1999;**353**:1167–73.
- 7 **Blaszzyk H, Björnsson J.** Factor V Leiden and morbid obesity in fatal postoperative pulmonary embolism. *Arch Surg* 2000;**135**:1410–3.
- 8 **Farmer R, Lawrenson R, Todd J, et al.** A comparison of the risks of venous thromboembolic disease in association with different combined oral contraceptives. *Br J Clin Pharmacol* 2000;**49**:580–90.
- 9 **Heit JA, Silverstein MD, Mohr DN, et al.** Risk factors for deep vein thrombosis and pulmonary embolism: a population-based case-control study. *Arch Intern Med* 2000;**160**:809–15.

- 10 Oger E. Incidence of venous thromboembolism: a community-based study in Western France. *Thromb Haemost* 2000;**83**:657–60.
- 11 Bernstein CN, Blanchard JF, Houston DS, et al. The incidence of deep venous thrombosis and pulmonary embolism among patients with inflammatory bowel disease: a population-based cohort study. *Thromb Haemost* 2001;**85**:430–4.
- 12 Danilenko-Dixon DR, Heit JA, Silverstein MD, et al. Risk factors for deep vein thrombosis and pulmonary embolism during pregnancy or post partum: a population-based, case-control study. *Am J Obstet Gynecol* 2001;**184**:104–10.
- 13 Heit JA, Silverstein MD, Mohr DN. The epidemiology of venous thromboembolism in the community. *Thromb Haemost* 2001;**86**:452–63.
- 14 Golin V, Sprovieri SR, Bedrikow R, et al. Pulmonary thromboembolism: retrospective study of necropsies performed over 24 years in a university hospital in Brazil. *Sao Paulo Med J* 2002;**120**:105–8.
- 15 Tveit DP, Hypolite IO, Hsieh P, et al. Chronic dialysis patients have high risk for pulmonary embolism. *Am J Kidney Dis* 2002;**39**:1011–7.
- 16 Tsai AW, Cushman M, Rosamond WD, et al. Cardiovascular risk factors and venous thromboembolism incidence: the longitudinal investigation of thromboembolism etiology. *Arch Intern Med* 2002;**162**:1182–9.
- 17 Khan A, Emberson J, Dowd GS. Standardized mortality ratios and fatal pulmonary embolism rates following total knee replacement: a cohort of 936 consecutive cases. *J Knee Surg* 2002;**15**:219–22.
- 18 Hirsh J, O'Donnell MJ. Venous thromboembolism after long flights: are airlines to blame? *Lancet* 2001;**357**:1461–2.
- 19 Ferrari E, Chevallier T, Chapelier A, et al. Travel as a risk factor for venous thromboembolic disease: a case-control study. *Chest* 1999;**115**:440–4.
- 20 Samama MM. An epidemiologic study of risk factors for deep vein thrombosis in medical outpatients: the Sirius study. *Arch Intern Med* 2000;**160**:3415–20.
- 21 Lapostolle F, Surget V, Borron SW, et al. Severe pulmonary embolism associated with air travel. *N Engl J Med* 2001;**345**:779–83.
- 22 Scurr JH, Machin SJ, Bailey-King S, et al. Frequency and prevention of symptomless deep-vein thrombosis in long-haul flights: a randomised trial. *Lancet* 2001;**357**:1485–9.
- 23 Oger E, Scarabin PY. Assessment of the risk for venous thromboembolism among users of hormone replacement therapy. *Drugs Aging* 1999;**14**:55–61.
- 24 Anonymous. Oral contraceptives and cardiovascular risk. *Drug Ther Bull* 2000;**38**:1–5.
- 25 Writing Group for the Women's Health Initiative Investigators. Risks and benefits of oestrogen plus progestin in healthy postmenopausal women. *JAMA* 2002;**288**:321–3.
- 26 Kemmeren JM, Algra A, Grobbee DE. Third generation oral contraceptives and risk of venous thrombosis: meta-analysis. *BMJ* 2001;**323**:131–9.
- 27 Lidegaard O, Edstrom B, Kreiner S. Oral contraceptives and venous thromboembolism: a five-year national case-control study. *Contraception* 2002;**65**:187–96.
- 28 McColl MD, Ramsay JE, Tait RC, et al. Risk factors for pregnancy associated venous thromboembolism. *Thromb Haemost* 1997;**78**:1183–8.
- 29 Gherman RB, Goodwin TM, Leung B, et al. Incidence, clinical characteristics, and timing of objectively diagnosed venous thromboembolism during pregnancy. *Obstet Gynecol* 1999;**94**:730–4.
- 30 Ros HS, Lichtenstein P, Bellocco R, et al. Pulmonary embolism and stroke in relation to pregnancy: how can high-risk women be identified? *Am J Obstet Gynecol* 2002;**186**:198–203.
- 31 Greaves M. Thrombophilia. *Clin Med* 2001;**1**:432–5.
- 32 Seligsohn U, Lubetsky A. Genetic susceptibility to venous thrombosis. *N Engl J Med* 2001;**344**:1222–31.
- 33 Folsom AR, Aleksic N, Wang L, et al. Protein C, antithrombin, and venous thromboembolism incidence: a prospective population-based study. *Arterioscl Thromb Vasc Biol* 2002;**22**:1018–22.
- 34 Martinelli I, De Stefano V, Taioli E, et al. Inherited thrombophilia and first venous thromboembolism during pregnancy and puerperium. *Thromb Haemost* 2002;**87**:791–5.
- 35 Keaton C, Gent M, Hirsh J, et al. A comparison of three months of anticoagulation with extended anticoagulation for a first episode of idiopathic venous thromboembolism. *N Engl J Med* 1999;**340**:901–7.
- 36 De Stefano V, Martinelli I, Mannucci PM, et al. The risk of recurrent venous thromboembolism among heterozygous carriers of the G20210A prothrombin gene mutation. *Br J Haematol* 2001;**113**:630–5.
- 37 Eichinger S, Weltermann A, Mannhalter C, et al. The risk of recurrent venous thromboembolism in heterozygous carriers of factor V Leiden and a first spontaneous venous thromboembolism. *Arch Intern Med* 2002;**162**:2357–60.
- 38 Greaves M, Baglin T. Laboratory testing for heritable thrombophilia: impact on clinical management of thrombotic disease. *Br J Haematol* 2000;**109**:699–703.
- 39 British Committee for Standards in Haematology. Investigation and management of heritable thrombophilia. *Br J Haematol* 2001;**114**:512–28.
- 40 Grau E, Real E, Medrano J, et al. Recurrent venous thromboembolism in a Spanish population: incidence, risk factors, and management in a hospital setting. *Thromb Res* 1999;**96**:335–41.
- 41 Prandoni P, Lensing A, Buller H, et al. Deep-vein thrombosis and the incidence of subsequent symptomatic cancer. *N Engl J Med* 1992;**327**:1128–33.
- 42 Monreal M, Casals A, Boix J, et al. Occult cancer in patients with acute pulmonary embolism. A prospective study. *Chest* 1993;**103**:816–9.
- 43 Bastounis EA, Karayiannakis AJ, Makri GG, et al. The incidence of occult cancer in patients with deep venous thrombosis: a prospective study. *J Intern Med* 1996;**239**:153–6.
- 44 Baron JA, Gridley G, Weiderpass E, et al. Venous thromboembolism and cancer. *Lancet* 1998;**351**:1077–80.
- 45 Sorensen HT, Mellekjaer L, Steffensen FH, et al. The risk of a diagnosis of cancer after primary deep venous thrombosis or pulmonary embolism. *N Engl J Med* 1998;**338**:1169–73.
- 46 Cornuz J, Pearson SD, Creager MA, et al. Importance of findings on the initial evaluation for cancer in patients with symptomatic idiopathic deep venous thrombosis. *Ann Intern Med* 1996;**125**:785–93.
- 47 Hettiarachchi RJ, Lok J, Prins MH, et al. Undiagnosed malignancy in patients with deep vein thrombosis: incidence, risk indicators, and diagnosis. *Cancer* 1998;**83**:180–5.
- 48 Sorensen HT, Mellekjaer L, Olsen JH, et al. Prognosis of cancers associated with venous thromboembolism. *N Engl J Med* 2000;**343**:1846–50.
- 49 Jung S, Robinson B. Venous thromboembolism in cancer patients in Christchurch, 1995–1999. *NZ Med J* 2002;**115**:257–60.
- 50 Heit JA, Melton LJ, Lohse CM, et al. Incidence of venous thromboembolism in hospitalised patients vs community residents. *Mayo Clin Proc* 2001;**76**:1102–10.
- 51 Heit JA, O'Fallon WM, Petterson TM, et al. Relative impact of risk factors for deep vein thrombosis and pulmonary embolism: a population-based study. *Arch Intern Med* 2002;**162**:1245–8.
- 52 Ferrari E, Baudouy M, Cerboni P, et al. Clinical epidemiology of venous thromboembolic disease. Results of a French Multicentre Registry. *Eur Heart J* 1997;**18**:685–91.
- 53 Kasper W, Konstantinides S, Geibel A, et al. Management strategies and determinants of outcome in acute major pulmonary embolism: results of a multicenter registry. *J Am Coll Cardiol* 1997;**30**:1165–71.
- 54 Goldhaber SZ, Visani L, De Rosa M. Acute pulmonary embolism: clinical outcomes in the International Cooperative Pulmonary Embolism Registry (ICOPE). *Lancet* 1999;**353**:1386–9.
- 55 Nakamura M, Fujioka H, Yamada N, et al. Clinical characteristics of acute pulmonary thromboembolism in Japan: results of a multicenter registry in the Japanese Society of Pulmonary Embolism Research. *Clin Cardiol* 2001;**24**:132–8.
- 56 Janata K, Holzer M, Domanovits H, et al. Mortality of patients with pulmonary embolism. *Wien Klin Wochenschr* 2002;**14**:766–72.
- 57 Heit JA, Silverstein MD, Mohr DN, et al. Predictors of survival after deep vein thrombosis and pulmonary embolism: a population-based cohort study. *Arch Intern Med* 1999;**159**:445–53.
- 58 Wicki J, Perrier A, Perneger T, et al. Predicting adverse outcome in patients with acute pulmonary embolism: a risk score. *Thromb Haemost* 2000;**84**:548–52.
- 59 Heit JA, Mohr DN, Silverstein MD, et al. Predictors of recurrence after deep vein thrombosis and pulmonary embolism: a population-based cohort study. *Arch Intern Med* 2000;**160**:761–8.
- 60 Ferrari E, Imbert A, Chevalier T, et al. The ECG in pulmonary embolism. Predictive value of negative T waves in precordial leads: 80 case reports. *Chest* 1997;**111**:537–43.
- 61 Jones JS, Neff TL, Carlson SA. Use of the alveolar-arterial oxygen gradient in the assessment of acute pulmonary embolism. *Am J Emerg Med* 1998;**16**:333–7.
- 62 Afzal A, Noor HA, Gill SA, et al. Leukocytosis in acute pulmonary embolism. *Chest* 1999;**115**:1329–32.
- 63 Prediletto R, Miniati M, Tonelli L, et al. Diagnostic value of gas exchange tests in patients with clinical suspicion of pulmonary embolism. *Crit Care* 1999;**3**:111–6.
- 64 Elliott CG, Goldhaber SZ, Visani L, et al. Chest radiographs in acute pulmonary embolism. Results from the International Cooperative Pulmonary Embolism Registry. *Chest* 2000;**118**:33–8.
- 65 Rodger M, Carrier M, Jones G, et al. Diagnostic value of arterial blood gas measurement in suspected pulmonary embolism. *Am J Respir Crit Care Med* 2000;**162**:2105–8.
- 66 Rodger M, Makropoulos D, Turek M, et al. Diagnostic value of the electrocardiogram in suspected pulmonary embolism. *Am J Cardiol* 2000;**86**:807–9.
- 67 Stein PD, Afzal A, Henry JW, et al. Fever in acute pulmonary embolism. *Chest* 2000;**117**:39–42.
- 68 Daniel KR, Courtney DM, Kline JA. Assessment of cardiac stress from massive pulmonary embolism with 12-lead ECG. *Chest* 2001;**120**:474–81.
- 69 Petrov DB. Appearance of right bundle branch block in electrocardiograms of patients with pulmonary embolism as a marker for obstruction of the main pulmonary trunk. *J Electrocardiol* 2001;**34**:185–8.
- 70 Ullman E, Brady WJ, Perron AD, et al. Electrocardiographic manifestations of pulmonary embolism. *Am J Emerg Med* 2001;**19**:514–9.
- 71 Girard P, Decousus M, Laporte S, et al. Diagnosis of pulmonary embolism in patients with proximal deep vein thrombosis: specificity of symptoms and perfusion defects at baseline and during anticoagulant therapy. *Am J Respir Crit Care Med* 2001;**164**:1033–7.
- 72 Pacouret G, Schellenberg F, Hamel E, et al. Troponin I in massive acute pulmonary embolism: results of a prospective series (French). *Presse Med* 1998;**27**:1627.
- 73 Peetz D, Post F, Voigtlander T, et al. Troponin I as a marker of right ventricular overload in acute pulmonary embolism (German). *Lab Med* 1998;**22**:553–8.
- 74 Giannitsis E, Muller-Bardorff M, Kuroski V, et al. Independent prognostic value of cardiac troponin T in patients with confirmed pulmonary embolism. *Circulation* 2000;**102**:211–7.



- 75 Meyer T, Binder L, Hruska N, *et al.* Cardiac troponin I elevation in acute pulmonary embolism is associated with right ventricular dysfunction. *J Am Coll Cardiol* 2000;**36**:1632–6.
- 76 Douketis JD. Elevated cardiac troponin levels in patients with submassive pulmonary embolism. *Arch Intern Med* 2002;**162**:79–81.
- 77 Konstantinides S, Geibel A, Olschewski M, *et al.* Importance of cardiac troponins I and T in risk stratification of patients with acute pulmonary embolism. *Circulation* 2002;**106**:1263–8.
- 78 Janata K, Holzer M, Laggner AN, *et al.* Cardiac troponin T in the severity assessment of patients with pulmonary embolism: cohort study. *BMJ* 2003;**326**:312–3.
- 79 Iwade K, Tanno K, Doi M, *et al.* Two cases of right ventricular ischemic injury due to massive pulmonary embolism. *Forens Sci Int* 2001;**116**:189–95.
- 80 Tverskaya MS, Karpova VV, Virganskii AO, *et al.* Structural and metabolic changes in cardiac conducting system during massive pulmonary embolism. *Bull Exp Biol Med* 2001;**130**:940–4.
- 81 Dieter RS, Ernst E, Ende DJ, *et al.* Diagnostic utility of cardiac troponin-I levels in patients with suspected pulmonary embolism. *Angiology* 2002;**53**:583–5.
- 82 Sanson BJ, Lijmer JG, Mac Gillavry MR, *et al.* Comparison of a clinical probability estimate and two clinical models in patients with suspected pulmonary embolism. *Thromb Haemost* 2000;**83**:199–203.
- 83 Leclercq MG, Lutsan JG, van Marwijk Kooy M, *et al.* Ruling out clinically suspected pulmonary embolism by assessment of clinical probability and D-dimer levels: a management study. *Thromb Haemost* 2003;**89**:97–103.
- 84 Wells PS, Ginsberg JS, Anderson DR, *et al.* Use of a clinical model for safe management of patients with suspected pulmonary embolism. *Ann Intern Med* 1998;**129**:997–1005.
- 85 Miniati M, Prediletto R, Formichi B, *et al.* Accuracy of clinical assessment in the diagnosis of pulmonary embolism. *Am J Respir Crit Care Med* 1999;**159**:864–71.
- 86 Perrier A, Miron MJ, Desmarais S, *et al.* Using clinical evaluation and lung scan to rule out suspected pulmonary embolism: is it a valid option in patients with normal results of lower-limb venous compression ultrasonography? *Arch Intern Med* 2000;**160**:512–6.
- 87 Righini M, Goehring C, Bounameaux H, *et al.* Effects of age on the performance of common diagnostic tests for pulmonary embolism. *Am J Med* 2000;**109**:357–61.
- 88 Lukaschek J, Schmid HR, Vorburget C, *et al.* Critical appraisal of the diagnostics of 270 consecutive cases of suspected venous thromboembolism and established consequences at a non-university centre. *Swiss Med Week* 2001;**131**:653–8.
- 89 Wicki J, Perneger TV, Junod AF, *et al.* Assessing clinical probability of pulmonary embolism in the emergency ward: a simple score. *Arch Intern Med* 2001;**161**:92–7.
- 90 Chagnon I, Bounameaux H, Aujesky D, *et al.* Comparison of two clinical prediction rules and implicit assessment among patients with suspected pulmonary embolism. *Am J Med* 2002;**113**:269–75.
- 91 Musset D, Parent F, Meyer G, *et al.* Diagnostic strategy for patients with suspected pulmonary embolism: a prospective multicentre outcome study. *Lancet* 2002;**360**:1914–20.
- 92 Rosen M, Sands D, Morris J, *et al.* Does a physician's ability to accurately assess the likelihood of pulmonary embolism increase with training? *Acad Med* 2000;**75**:1199–205.
- 93 Wells PS, Anderson DR, Rodger M, *et al.* Derivation of a simple clinical model to categorize patients probability of pulmonary embolism: increasing the models utility with the SimpliRED D-dimer. *Thromb Haemost* 2000;**83**:416–20.
- 94 Wells PS, Anderson DR, Rodger M, *et al.* Excluding pulmonary embolism at the bedside without diagnostic imaging: management of patients with suspected pulmonary embolism presenting to the emergency department by using a simple clinical model and D-dimer. *Ann Intern Med* 2001;**135**:98–107.
- 95 Bova C, Greco F, Ferrari A, *et al.* The usefulness of the association of clinical probability, rapid plasma measurement of D-dimer, compression echography of the lower limbs and echocardiography in the diagnosis of acute pulmonary embolism (Italian). *Ital Heart J* 2000;**1**:116–21.
- 96 Campo JF, Hernandez MJ, Anta M, *et al.* Concordance in the clinical diagnosis of pulmonary embolism (Spanish). *Med Clin (Barc)* 1998;**111**:121–4.
- 97 Egermayer P, Town GI, Turner JG, *et al.* Usefulness of D-dimer, blood gas, and respiratory rate measurements for excluding pulmonary embolism. *Thorax* 1998;**53**:830–4.
- 98 Kline JA, Nelson RD, Jackson RE, *et al.* Criteria for the safe use of D-dimer testing in emergency department patients with suspected pulmonary embolism: a multicenter US study. *Ann Emerg Med* 2002;**39**:144–52.
- 99 Miron MJ, Perrier A, Bounameaux H, *et al.* Contribution of noninvasive evaluation to the diagnosis of pulmonary embolism in hospitalised patients. *Eur Respir J* 1999;**13**:1365–70.
- 100 Ghirardini G, Battioni M, Bertellini C, *et al.* D-dimer after delivery in uncomplicated pregnancies. *Clin Exp Obstet Gynecol* 1999;**26**:211–2.
- 101 De Monye W, Sanson BJ, MacGillavry MR, *et al.* Embolus location affects the sensitivity of a rapid quantitative D-dimer assay in the diagnosis of pulmonary embolism. *Am J Respir Crit Care Med* 2002;**165**:345–8.
- 102 Kline JA, Johns KL, Colucciello SA, *et al.* New diagnostic tests for pulmonary embolism. *Ann Emerg Med* 2000;**35**:168–80.
- 103 Ginsberg JS, Wells PS, Kearon C, *et al.* Sensitivity and specificity of a rapid whole-blood assay for D-dimer in the diagnosis of pulmonary embolism. *Ann Intern Med* 1998;**129**:1006–11.
- 104 MacGillavry MR, Lijmer JG, Sanson BJ, *et al.* Diagnostic accuracy of triage tests to exclude pulmonary embolism. *Thromb Haemost* 2001;**85**:995–8.
- 105 Chunilal SD, Brill-Edwards PA, Stevens PB, *et al.* The sensitivity and specificity of a red blood cell agglutination D-dimer assay for venous thromboembolism when performed on venous blood. *Arch Intern Med* 2002;**162**:217–20.
- 106 Perrier A, Desmarais S, Miron MJ, *et al.* Non-invasive diagnosis of venous thromboembolism in outpatients. *Lancet* 1999;**353**:190–5.
- 107 Freyburger G, Trillaud H, Labrousse S, *et al.* D-dimer strategy in thrombosis exclusion: a gold standard study in 100 patients suspected of deep venous thrombosis or pulmonary embolism. *Thromb Haemost* 1998;**79**:32–7.
- 108 Anderson D, Wells P. D-dimer for the diagnosis of venous thromboembolism. *Curr Opin Hematol* 2000;**7**:296–301.
- 109 Pacouret G. Association between D-dimer and helical CT scanning in the diagnosis of pulmonary embolism: a prospective study of 106 ambulatory patients (French). *Presse Med* 2002;**31**:13–8.
- 110 Bates SM, Grand Maison A, Johnston M, *et al.* A latex D-dimer reliably excludes venous thromboembolism. *Arch Intern Med* 2001;**161**:447–53.
- 111 Kovacs MJ, MacKinnon KM, Anderson D, *et al.* A comparison of three rapid D-dimer methods for the diagnosis of venous thromboembolism. *Br J Haematol* 2001;**115**:140–4.
- 112 Reber G, Bounameaux H, Perrier A, *et al.* Performances of a new, automated latex assay for the exclusion of venous thromboembolism. *Blood Coag Fibrinol* 2001;**12**:217–20.
- 113 Burkill GJ, Bell JR, Chinn RJ, *et al.* The use of a D-dimer assay in patients undergoing CT pulmonary angiography for suspected pulmonary embolism. *Clin Radiol* 2002;**57**:41–6.
- 114 Palareti G, Legnani C, Cosmi B, *et al.* Risk of venous thromboembolism recurrence: high negative predictive value of D-dimer performed after oral anticoagulation is stopped. *Thromb Haemost* 2002;**87**:7–12.
- 115 Nilsson T, Mare K, Carlsson A. Value of structured clinical and scintigraphic protocols in acute pulmonary embolism. *J Intern Med* 2001;**250**:213–8.
- 116 Prologo JD, Glauser J. Variable diagnostic approach to suspected pulmonary embolism in the ED of a major academic tertiary care center. *Am J Emerg Med* 2002;**20**:5–9.
- 117 Lemb M, Pohlabein H. Pulmonary thromboembolism: a retrospective study on the examination of 991 patients by ventilation/perfusion SPECT using Technegas. *Nucl Med* 2001;**40**:179–86.
- 118 Gottschalk A. New criteria for ventilation-perfusion lung scan interpretation: a basis for optimal interaction with helical CT angiography. *Radiographics* 2000;1206–10.
- 119 Itti E, Nguyen S, Robin F, *et al.* Distribution of ventilation/perfusion ratios in pulmonary embolism: an adjunct to the interpretation of ventilation/perfusion lung scans. *J Nucl Med* 2002;**43**:1596–602.
- 120 Worsley DF, Alavi A. Radionuclide imaging of acute pulmonary embolism. *Radiol Clin N Am* 2001;**39**:1035–52.
- 121 Burkill GJ, Bell JR, Padley SP. Survey on the use of pulmonary scintigraphy, spiral CT and conventional pulmonary angiography for suspected pulmonary embolism in the British Isles. *Clin Radiol* 1999;**54**:807–10.
- 122 Hagen PJ, van Strijen MJ, Kieft GJ, *et al.* The application of a Dutch consensus diagnostic strategy for pulmonary embolism in clinical practice. *Neth J Med* 2001;**59**:161–9.
- 123 Chan WL, McLean R, Carolan MG. What happens after a lung scan? Management and outcome of patients in a regional hospital. *Australas Radiol* 2002;**46**:375–80.
- 124 Khorasani R, Gudas TF, Nikpoor N, *et al.* Treatment of patients with suspected pulmonary embolism and intermediate-probability lung scans: is diagnostic imaging underused? *Am J Roentgenol* 1997;**169**:1355–7.
- 125 Kuijper PM, Turksira F, van Beek EJ, *et al.* A survey of the diagnostic and therapeutic management of patients with suspected pulmonary embolism in the Netherlands. *Neth J Med* 1997;**50**:261–6.
- 126 Broekhuizen-de Gast HS, Tiel-van Buul MM, Ubink M, *et al.* The value of the 'non-diagnostic' lung scan - further classification as to the risk of pulmonary embolism is not reliable (Dutch). *Ned Tijdschr Geneesk* 2000;**144**:1537–42.
- 127 Rosen MP, Sands DZ, Kuntz KM. Physicians' attitudes toward misdiagnosis of pulmonary embolism: a utility analysis. *Acad Radiol* 2000;**7**:14–20.
- 128 Walsh G, Jones DN. Subsequent investigation and management of patients with intermediate-category and -probability ventilation-perfusion scintigraphy. *Australas Radiol* 2000;**44**:424–7.
- 129 Berghout A, Oudkerk M, Hicks SG, *et al.* Active implementation of a consensus strategy improves diagnosis and management in suspected pulmonary embolism. *Q J Med* 2000;**93**:335–40.
- 130 Gray HW, Bessent RG, McKillop JH. A preliminary evaluation of diagnostic odds in lung scan reporting. *Nucl Med Commun* 1998;**19**:113–8.
- 131 Rajendran JG, Jacobson AF. Review of 6-month mortality following low-probability lung scans. *Arch Intern Med* 1999;**159**:349–52.
- 132 Van Beek EJR, Brouwers EMJ, Song B, *et al.* Lung scintigraphy and helical computed tomography for the diagnosis of pulmonary embolism: a meta-analysis. *Clin Appl Thromb Hems* 2001;**7**:87–92.
- 133 Hartmann I, Hagen P, Melissant C, *et al.* Diagnosing acute pulmonary embolism: effect of chronic obstructive pulmonary disease on the performance of D-dimer testing, ventilation/perfusion scintigraphy, spiral computed tomographic angiography, and conventional angiography. *Am J Respir Crit Care Med* 2000;**162**:2232–7.
- 134 Infante JR, Torres-Avisbal M, Gonzalez FM, *et al.* Effect of different observers on the interpretation of pulmonary perfusion scintigraphy (Spanish). *Revist Esp Med Nucl* 2002;**21**:93–8.

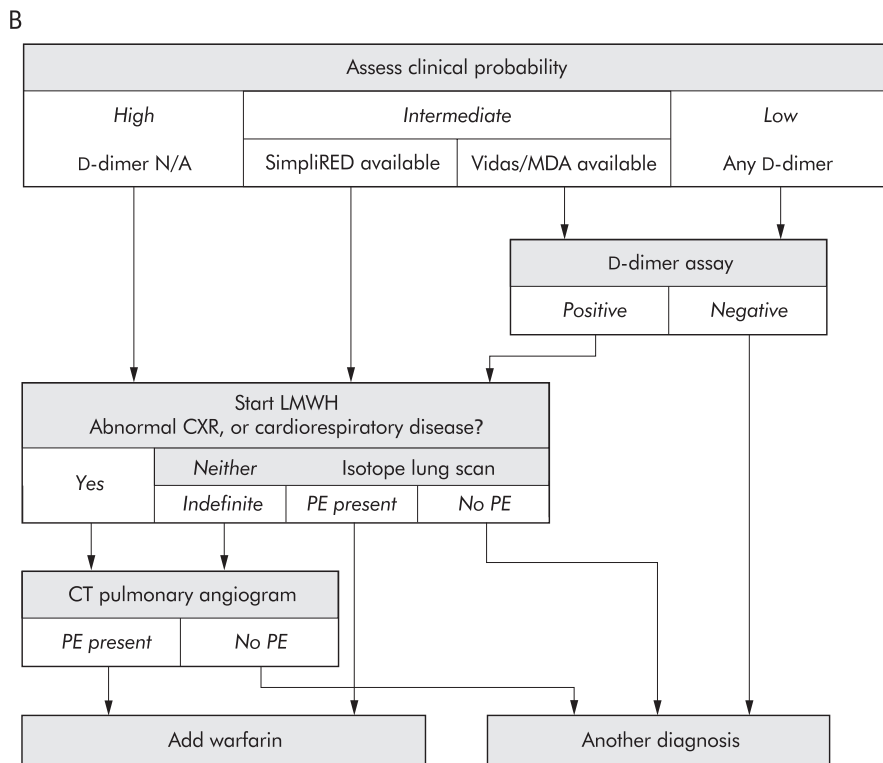
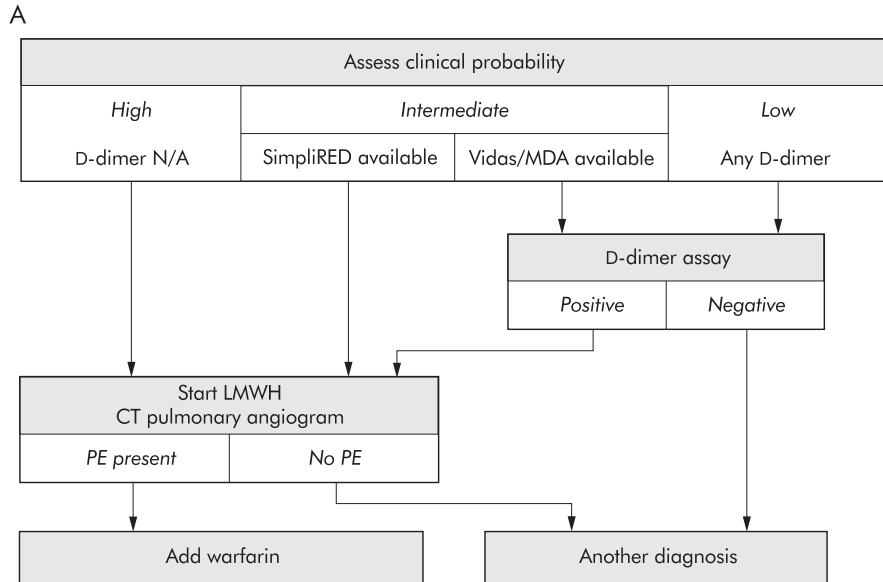
- 135 **Forbes KP**, Reid JH, Murchison JT. Do preliminary chest X-ray findings define the optimum role of pulmonary scintigraphy in suspected pulmonary embolism? *Clin Radiol* 2001;**56**:397–400.
- 136 **Wilson HT**, Meagher TM, Williams SJ. Combined helical computed tomographic pulmonary angiography and lung perfusion scintigraphy for investigating acute pulmonary embolism. *Clin Radiol* 2002;**57**:33–6.
- 137 **British Nuclear Medicine Society**. *Quality guidelines for ventilation / perfusion imaging for pulmonary embolic disease*. <http://www.bnms.org.uk/bnms.htm>; 2001.
- 138 **Bastuji-Garin S**, Schaeffer A, Walkenstein P, et al. Pulmonary embolism; lung scanning interpretation: about words. *Chest* 1998;**114**:1551–5.
- 139 **Gray HW**, Neilly JB. The role and value of ventilation perfusion imaging in pulmonary embolism. In: Oudkerk M, van Beek, EJR, ten cate JW, eds. *Pulmonary embolism: epidemiology, diagnosis and treatment*. Oxford: Blackwell Science, 1999:84–123.
- 140 **Clarke SEM**, Burwood R, Cox C. *Reaudit lung scintigraphy: ventilation and perfusion imaging for the investigation of possible acute pulmonary embolism*. London: South Thames Region Nuclear Medicine Audit Group, 2001.
- 141 **Turkstra F**, Kuijter PM, van Beek EJ, et al. Diagnostic utility of ultrasonography of leg veins in patients suspected of having pulmonary embolism. *Ann Intern Med* 1997;**126**:775–81.
- 142 **Torres JA**, Aracil E, Puras E, et al. Role of venous duplex imaging of lower extremity for pulmonary embolism diagnostic. *Angiologia* 1999;**51**:71–6.
- 143 **MacGillivray M**, Sanson B, Buller H, et al. Compression ultrasonography of the leg veins in patients with clinically suspected pulmonary embolism: is a more extensive assessment of compressibility useful? *Thromb Haemost* 2000;**84**:973–6.
- 144 **Barrellier M**, Lezin B, Landy S, et al. Prevalence of duplex ultrasonography detectable venous thrombosis in patients with suspected or acute pulmonary embolism. *J Mal Vasc* 2001;**26**:23–30.
- 145 **Girard P**, Musset D, Parent F, et al. High prevalence of detectable deep venous thrombosis in patients with acute pulmonary embolism. *Chest* 1999;**116**:903–8.
- 146 **Daniel KR**, Jackson RE, Kline JA. Utility of lower extremity venous ultrasound scanning in the diagnosis and exclusion of pulmonary embolism in outpatients. *Ann Emerg Med* 2000;**35**:547–54.
- 147 **Meyerovitz MF**, Mannting F, Polak JF, et al. Frequency of pulmonary embolism in patients with low-probability lung scan and negative lower extremity venous ultrasound. *Chest* 1999;**115**:980–2.
- 148 **Elias A**, Mallard L, Elias M, et al. A single complete ultrasound investigation of the venous network for the diagnostic management of patients with a clinically suspected first episode of deep venous thrombosis of the lower limbs. *Thromb Haemost* 2003;**289**:221–7.
- 149 **Hull RD**, Raskob GE, Ginsberg JS, et al. A noninvasive strategy for the treatment of patients with suspected pulmonary embolism. *Arch Intern Med* 1994;**154**:289–97.
- 150 **Wells PS**, Ginsberg JS, Anderson DR, et al. Utility of ultrasound imaging of the lower extremities in the diagnostic approach in patients with suspected pulmonary embolism. *J Intern Med* 2001;**250**:262–4.
- 151 **Diffin DC**, Leyendecker JR, Johnson SP, et al. Effect of anatomic distribution of pulmonary emboli on interobserver agreement in the interpretation of pulmonary angiography. *Am J Roentgenol* 1998;**171**:1085–9.
- 152 **Baile EM**, King GG, Muller NL, et al. Spiral computed tomography is comparable to angiography for the diagnosis of pulmonary embolism. *Am J Respir Crit Care Med* 2000;**161**:1010–5.
- 153 **Van Rossum AB**, Bongaerts AH, Woodard PK. Helical computed tomography and pulmonary embolism. In: Oudkerk M vBE, ten Cate JW, eds. *Pulmonary embolism: epidemiology, diagnosis and treatment*. Oxford: Blackwell Science, 1999:192–225.
- 154 **Remy-Jardin M**, Remy J, Mayo JR, et al. Acute pulmonary embolism. In: *CT angiography of the chest*. Philadelphia: Lippincott Williams & Wilkins, 2001:51–66.
- 155 **Mayo JR**, Remy-Jardin M, Muller NL, et al. Pulmonary embolism: prospective comparison of spiral CT with ventilation-perfusion scintigraphy. *Radiology* 1997;**205**:447–52.
- 156 **Garg K**, Welsh CH, Feyerabend AJ, et al. Pulmonary embolism: diagnosis with spiral CT and ventilation-perfusion scanning - correlation with pulmonary angiographic results or clinical outcome. *Radiology* 1998;**208**:201–8.
- 157 **Van Rossum AB**, Pattnayama PM, Mallens WM, et al. Can helical CT replace scintigraphy in the diagnostic process in suspected pulmonary embolism? A retrospective-prospective cohort study focusing on total diagnostic yield. *Eur Radiol* 1998;**8**:90–6.
- 158 **Blachere H**, Latrabe V, Montaudon M, et al. Pulmonary embolism revealed on helical CT angiography: comparison with ventilation-perfusion radionuclide lung scanning. *Am J Roentgenol* 2000;**174**:1041–7.
- 159 **Cueto SM**, Cavanaugh SH, Benenson RS, et al. Computed tomography scan versus ventilation-perfusion lung scan in the detection of pulmonary embolism. *J Emerg Med* 2001;**21**:155–64.
- 160 **Bankier AA**, Janata K, Fleischmann D, et al. Severity assessment of acute pulmonary embolism with spiral CT: evaluation of two modified angiographic scores and comparison with clinical data. *J Thorac Imaging* 1997;**12**:150–8.
- 161 **Mastora I**, Remy-Jardin M, Masson P, et al. Severity of acute pulmonary embolism: evaluation of a new spiral CT angiographic score in correlation with echocardiographic data. *Eur Radiol* 2003;**13**:29–35.
- 162 **Van Rossum AB**, van Erkel AR, van Persijn van Meerten EL, et al. Accuracy of helical CT for acute pulmonary embolism: ROC analysis of observer performance related to clinical experience. *Eur Radiol* 1998;**8**:1160–4.
- 163 **Chartrand-Lefebvre C**, Howarth N, Lucidarme O, et al. Contrast-enhanced helical CT for pulmonary embolism detection: inter- and intra-observer agreement among radiologists with variable experience. *Am J Roentgenol* 1999;**172**:107–12.
- 164 **Domingo ML**, Marti-Bonmati L, Dosda R, et al. Interobserver agreement in the diagnosis of pulmonary embolism with helical CT. *Eur J Radiol* 2000;**34**:136–40.
- 165 **Remy-Jardin M**, Remy J, Baghaie F, et al. Clinical value of thin collimation in the diagnostic workup of pulmonary embolism. *Am J Roentgenol* 2000;**175**:407–11.
- 166 **Perrier A**, Howarth N, Didier D, et al. Performance of helical computed tomography in unselected outpatients with suspected pulmonary embolism. *Ann Intern Med* 2001;**135**:88–97.
- 167 **Qanadli SD**, El Hajjam M, Vieillard-Baron A, et al. New CT index to quantify arterial obstruction in pulmonary embolism: comparison with angiographic index and echocardiography. *Am J Roentgenol* 2001;**176**:1415–20.
- 168 **Bourriol K**, Couffinhall T, Bernard V, et al. Clinical outcome after a negative spiral CT pulmonary angiogram in an in-patient population from cardiology and pneumology wards. *Chest* 2003;**123**:359–65.
- 169 **Mullins MD**, Becker DM, Hagspiel KD, et al. The role of spiral volumetric computed tomography in the diagnosis of pulmonary embolism. *Arch Intern Med* 2000;**160**:293–8.
- 170 **Rathbun SW**, Raskob GE, Whitsett TL. Sensitivity and specificity of helical computed tomography in the diagnosis of pulmonary embolism: a systematic review. *Ann Intern Med* 2000;**132**:227–32.
- 171 **Safriel Y**, Zinn H. CT pulmonary angiography in the detection of pulmonary emboli: a meta-analysis of sensitivities and specificities. *Clin Imag* 2002;**26**:101–5.
- 172 **Harvey R**, Gefter W, Hrunig J, et al. Accuracy of CT angiography versus pulmonary angiography in the diagnosis of acute pulmonary embolism: evaluation of the literature with summary ROC curve analysis. *Acad Radiol* 2000;**7**:786–97.
- 173 **Remy-Jardin M**, Remy J, Artaud D, et al. Spiral CT of pulmonary embolism: diagnostic approach, interpretive pitfalls and current indications. *Eur Radiol* 1998;**8**:1376–90.
- 174 **Howling SJ**, Hansell DM. Spiral computed tomography for pulmonary embolism. *Hosp Med* 2000;**61**:41–5.
- 175 **Stein PD**, Henry JW. Prevalence of acute pulmonary embolism in central and subsegmental pulmonary arteries and relation to probability interpretation of ventilation/perfusion lung scans. *Chest* 1997;**111**:1246–8.
- 176 **Qanadli S**, Hajjam M, Mesurulle B, et al. Pulmonary embolism detection: prospective evaluation of dual-section helical CT versus selective pulmonary arteriography in 157 patients. *Radiology* 2000;**217**:447–55.
- 177 **Remy-Jardin M**, Tillie-Leblond I, Szapiro D, et al. CT angiography of pulmonary embolism in patients with underlying respiratory disease: impact of multi-slice CT (MSCT) on image quality and negative predictive value. *Eur Radiol* 2002;**12**:1971–8.
- 178 **De Monye W**, van Strijen MJ, Huisman MV, et al. Suspected pulmonary embolism: prevalence and anatomic distribution in 487 consecutive patients. *Radiology* 2000;**215**:184–8.
- 179 **Raptopoulos V**, Boiselle PM. Multi-detector row spiral CT pulmonary angiography: comparison with single-detector row spiral CT. *Radiology* 2001;**221**:606–13.
- 180 **Schoepf UJ**, Holzknicht N, Helmberger TK, et al. Subsegmental pulmonary emboli: improved detection with thin-collimation multi-detector row spiral CT. *Radiology* 2002;**222**:483–90.
- 181 **Reid JH**, Murchison JT. Acute right ventricular dilatation: a new helical CT sign of massive pulmonary embolism. *Clin Radiol* 1998;**53**:694–8.
- 182 **Wintersperger BJ**, Stabler A, Seemann M, et al. Evaluation of right ventricular performance in patients with acute pulmonary embolism by helical CT (German). *Rofo Fortschr* 1999;**170**:542–9.
- 183 **Ferretti GR**, Bosson JL, Buffaz PD, et al. Acute pulmonary embolism: role of helical CT in 164 patients with intermediate probability at ventilation-perfusion scintigraphy and normal results at duplex US of the legs. *Radiology* 1997;**205**:453–8.
- 184 **Garg K**, Sieler H, Welsh CH, et al. Clinical validity of helical CT being interpreted as negative for pulmonary embolism: implications for patient treatment. *Am J Roentgenol* 1999;**172**:1627–31.
- 185 **Lomis NN**, Yoon HC, Moran AG, et al. Clinical outcomes of patients after a negative spiral CT pulmonary arteriogram in the evaluation of acute pulmonary embolism. *J Vasc Intervent Radiol* 1999;**10**:707–12.
- 186 **Lorut C**, Ghossains M, Horellou M, et al. A non-invasive diagnostic strategy including spiral computed tomography in patients with suspected pulmonary embolism. *Am J Respir Crit Care Med* 2000;**162**:1413–8.
- 187 **Goodman LR**, Lipchik RJ, Kuzo RS, et al. Subsequent pulmonary embolism risk after a negative helical CT pulmonary angiogram: prospective comparison with scintigraphy. *Radiology* 2000;**215**:535–42.
- 188 **Gottsater A**, Berg A, Centergard J, et al. Clinically suspected pulmonary embolism: is it safe to withhold anticoagulation after a negative spiral CT? *Eur Radiol* 2001;**11**:65–72.
- 189 **Nilsson T**, Olsson A, Johnsson H, et al. Negative spiral CT in acute pulmonary embolism. *Acta Radiol* 2002;**43**:486–91.
- 190 **Novelline RA**, Baltarowich OH, Athanasoulis CA, et al. The clinical course of patients with suspected pulmonary embolism and a negative pulmonary arteriogram. *Radiology* 1978;**126**:561–7.
- 191 **Cheely R**, McCartney WH, Perry JR, et al. The role of noninvasive tests versus pulmonary angiography in the diagnosis of pulmonary embolism. *Am J Med* 1981;**70**:17–22.

- 192 **Henry JW**, Relyea B, Stein PD. Continuing risk of thromboemboli among patients with normal pulmonary angiograms. *Chest* 1995;**107**:1375-8.
- 193 **Van Beek EJ**, Kuijter PM, Buller HR, *et al*. The clinical course of patients with suspected pulmonary embolism. *Arch Intern Med* 1997;**157**:2593-8.
- 194 **Swensen SJ**, Sheedy PF, Ryu JH, *et al*. Outcomes after withholding anticoagulation from patients with suspected acute pulmonary embolism and a negative computed tomogram: a cohort study. *Mayo Clin Proc* 2002;**77**:130-8.
- 195 **Ginsberg MS**, Oh J, Welber A, *et al*. Clinical usefulness of imaging performed after CT angiography that was negative for pulmonary embolus in a high-risk oncologic population. *Am J Roentgenol* 2002;**179**:1205-8.
- 196 **Cham MD**, Yankelevitz DF, Shaham D, *et al*. Deep venous thrombosis: detection by using indirect CT venography. The Pulmonary Angiography-Indirect CT Venography Cooperative Group. *Radiology* 2000;**216**:744-51.
- 197 **Duwe K**, Shiau M, Budorick N, *et al*. Evaluation of the lower extremity veins in patients with suspected pulmonary embolism: a retrospective comparison of helical CT venography and sonography. *Am J Roentgenol* 2000;**175**:1525-31.
- 198 **Garg K**, Kemp JL, Wojcik D, *et al*. Thromboembolic disease: comparison of combined CT pulmonary angiography and venography with bilateral leg sonography in 70 patients. *Am J Roentgenol* 2000;**175**:997-1001.
- 199 **Ghaye B**, Szapiro D, Willems V, *et al*. Combined CT venography of the lower limbs and spiral CT angiography of pulmonary arteries in acute pulmonary embolism: preliminary results of a prospective study. *J Belg Radiol* 2000;**83**:271-8.
- 200 **Au VW**, Walsh G, Fon G. Computed tomography pulmonary angiography with pelvic venography in the evaluation of thromboembolic disease. *Australas Radiol* 2001;**45**:141-5.
- 201 **Loud PA**, Katz DS, Bruce DA, *et al*. Deep venous thrombosis with suspected pulmonary embolism: detection with combined CT venography and pulmonary angiography. *Radiology* 2001;**219**:498-502.
- 202 **Nicolas M**, Debelle L, Laurent V, *et al*. Incremental lower extremity CT venography, a simplified approach for the diagnosis of deep venous thrombosis in patients with pulmonary embolism. *J Radiol* 2001;**82**:251-6.
- 203 **Peterson DA**, Kazerooni EA, Wakefield TW, *et al*. Computed tomographic venography is specific but not sensitive for diagnosis of acute lower-extremity deep venous thrombosis in patients with suspected pulmonary embolus. *J Vasc Surg* 2001;**34**:798-804.
- 204 **Wildberger JE**, Mahnken AH, Sinha AM, *et al*. A differentiated approach to the diagnosis of pulmonary embolism and deep venous thrombosis using multi-slice CT (German). *Rofo Fortschr* 2002;**174**:301-7.
- 205 **Jonez-Mentzel L**, Eger C, Basche S. CT venography and CT angiography of the pulmonary arteries in acute pulmonary embolism (German). *Zentralbl Chir* 2002;**127**:755-9.
- 206 **Rademaker J**, Griesshaber V, Hidayat N, *et al*. Combined CT pulmonary angiography and venography for diagnosis of pulmonary embolism and deep vein thrombosis: radiation dose. *J Thorac Imaging* 2001;**16**:297-9.
- 207 **Velmahos GC**, Vassiliu P, Wilcox A, *et al*. Spiral computed tomography for the diagnosis of pulmonary embolism in critically ill surgical patients: a comparison with pulmonary angiography. *Arch Surg* 2001;**136**:505-11.
- 208 **Tillie-Leblond I**, Mastora I, Radenne F, *et al*. Risk of subsequent pulmonary embolism after a negative spiral angiogram in patients with underlying pulmonary disease: a one-year clinical follow-up study. *Radiology* 2002;**232**:461-7.
- 209 **Kasper W**, Konstantinides S, Geibel A, *et al*. Prognostic significance of right ventricular afterload stress detected by echocardiography in patients with clinically suspected pulmonary embolism. *Heart* 1997;**77**:346-9.
- 210 **Serafini O**, Bisignani G, Greco F, *et al*. The role of 2D-Doppler electrocardiography in the early diagnosis of massive acute pulmonary embolism and therapeutic monitoring (Italian). *G Ital Cardiol* 1997;**27**:462-9.
- 211 **Jackson RE**, Rudoni RR, Hauser AM, *et al*. Prospective evaluation of two-dimensional transthoracic echocardiography in emergency department patients with suspected pulmonary embolism. *Acad Emerg Med* 2000;**7**:994-8.
- 212 **Miniati M**, Monti S, Pratali L, *et al*. Value of transthoracic echocardiography in the diagnosis of pulmonary embolism: results of a prospective study in unselected patients. *Am J Med* 2001;**110**:528-35.
- 213 **Vieillard-Baron A**, Page B, Augarde R, *et al*. Acute cor pulmonale in massive pulmonary embolism: incidence, echocardiographic pattern, clinical implications and recovery rate. *Intensive Care Med* 2001;**27**:1481-6.
- 214 **Comess K**, DeRook F, Russell M, *et al*. The incidence of pulmonary embolism in unexplained sudden cardiac arrest with pulseless electrical activity. *Am J Med* 2000;**109**:351-6.
- 215 **Krivec B**, Voga G, Zuran I, *et al*. Diagnosis and treatment of shock due to massive pulmonary embolism: approach with transoesophageal echocardiography and intrapulmonary thrombolysis. *Chest* 1997;**112**:1310-6.
- 216 **Antakly-Hanon Y**, Vieillard-Baron A, Qanadli SD, *et al*. The value of transoesophageal echocardiography for the diagnosis of pulmonary embolism with acute cor pulmonale (French). *Arch Mal Coeur Vaiss* 1998;**91**:843-8.
- 217 **Otmani A**, Tribouilloy C, Leborgne L, *et al*. Diagnostic value of echocardiography and thoracic spiral CT angiography in the diagnosis of acute pulmonary embolism (French). *Ann Cardiol Angeiol* 1998;**47**:707-15.
- 218 **Pruszczyk P**, Torbicki A, Kuch-Wociał A, *et al*. Diagnostic value of transoesophageal echocardiography in suspected haemodynamically significant pulmonary embolism. *Heart* 2001;**85**:628-34.
- 219 **Mathis G**, Bitschnau R, Gehmacher O, *et al*. Chest ultrasound in diagnosis of pulmonary embolism in comparison to helical CT. *Ultraschall Med* 1999;**20**:54-9.
- 220 **Reissig A**, Heyne JP, Kroegel C. Sonography of lung and pleura in pulmonary embolism: sonomorphologic characterisation and comparison with spiral CT scanning. *Chest* 2001;**120**:1977-83.
- 221 **Lechleitner P**, Riedl B, Raneburger W, *et al*. Chest sonography in the diagnosis of pulmonary embolism: a comparison with MRI angiography and ventilation perfusion scintigraphy (German). *Ultraschall Med* 2002;**23**:373-8.
- 222 **Coche EE**, Muller NL, Kim KI, *et al*. Acute pulmonary embolism: ancillary findings at spiral CT. *Radiology* 1998;**207**:753-8.
- 223 **Shah AA**, Davis SD, Gamsu G, *et al*. Parenchymal and pleural findings in patients with and patients without acute pulmonary embolism detected at spiral CT. *Radiology* 1999;**211**:147-53.
- 224 **Meaney JF**, Weg JG, Chenevert TL, *et al*. Diagnosis of pulmonary embolism with magnetic resonance angiography. *N Engl J Med* 1997;**336**:1422-7.
- 225 **Gupta A**, Frazer CK, Ferguson JM, *et al*. Acute pulmonary embolism: diagnosis with MR angiography. *Radiology* 1999;**210**:353-9.
- 226 **Bock JC**, Lehmann J. MR imaging of experimental pulmonary embolism using a macromolecular contrast medium (German). *Rofo Fortschr* 1997;**167**:516-20.
- 227 **Li KC**, Pelc LR, Napel SA, *et al*. MRI of pulmonary embolism using Gd-DTPA-polyethylene glycol polymer enhanced 3D fast gradient echo technique in a canine model. *Magn Reson Imag* 1997;**15**:543-50.
- 228 **Hurst DR**, Kazerooni EA, Stafford-Johnson D, *et al*. Diagnosis of pulmonary embolism: comparison of CT angiography and MR angiography in canines. *J Vasc Intervent Radiol* 1999;**10**:309-18.
- 229 **Reitner P**, Coxson HO, Nakano Y, *et al*. Pulmonary embolism: comparison of gadolinium-enhanced MR angiography with contrast-enhanced spiral CT in a porcine model. *Acad Radiol* 2001;**8**:343-50.
- 230 **Oudkerk M**, van Beek EJR, Wielopolski P, *et al*. Comparison of contrast-enhanced magnetic resonance angiography and conventional pulmonary angiography for the diagnosis of pulmonary embolism: a prospective study. *Lancet* 2002;**359**:1643-7.
- 231 **Ong YE**, Crowther A, Miller A. Rapid diagnosis of massive pulmonary embolism in a district general hospital. *Int J Clin Pract* 2000;**54**:144-6.
- 232 **Oliver TB**, Reid JH, Murchison JT. Interventricular septal shift due to massive pulmonary embolism shown by CT pulmonary angiography: an old sign revisited. *Thorax* 1998;**53**:1092-4.
- 233 **Wood KE**. Major pulmonary embolism: review of a pathophysiologic approach to the golden hour of hemodynamically significant pulmonary embolism. *Chest* 2002;**121**:877-905.
- 234 **Smulders YM**. Contribution of pulmonary vasoconstriction to haemodynamic instability after acute pulmonary embolism. Implications for treatment? *Neth J Med* 2001;**58**:241-7.
- 235 **Daniels LB**, Parker JA, Patel SR, *et al*. Relation of duration of symptoms with response to thrombolytic therapy in pulmonary embolism. *Am J Cardiol* 1997;**80**:184-8.
- 236 **Arcasoy SM**, Kreit JW. Thrombolytic therapy of pulmonary embolism: a comprehensive review of current evidence. *Chest* 1999;**115**:1695-707.
- 237 **Thabut G**, Thabut D, Myers R, *et al*. Thrombolytic therapy of pulmonary embolism: a meta-analysis. *J Am Coll Cardiol* 2002;**40**:1660-7.
- 238 **Jerjes-Sanchez C**, Ramirez-Rivera A, Garcia M de L, *et al*. Streptokinase and heparin versus heparin alone in massive pulmonary embolism: a randomised controlled trial. *J Thromb Thrombolysis* 1995;**2**:227-9.
- 239 **Rose PS**, Punjabi NM, Pearse DB. Treatment of right heart thromboemboli. *Chest* 2002;**121**:806-14.
- 240 **Konstantinides S**, Geibel A, Olschewski M, *et al*. Association between thrombolytic treatment and the prognosis of hemodynamically stable patients with major pulmonary embolism: results of a multicenter registry. *Circulation* 1997;**96**:882-8.
- 241 **Grifoni S**, Olivetto I, Cecchini P, *et al*. Short-term clinical outcome of patients with acute pulmonary embolism, normal blood pressure, and echocardiographic right ventricular dysfunction. *Circulation* 2000;**101**:2817-22.
- 242 **Hamel E**, Pacouret G, Vincetelli D, *et al*. Thrombolysis or heparin therapy in massive pulmonary embolism with right ventricular dilation: results from a 128-patient monocenter registry. *Chest* 2001;**120**:120-5.
- 243 **Konstantinides S**, Geibel A, Heusel G, *et al*. Heparin plus alteplase compared with heparin alone in patients with submassive pulmonary embolism. *N Engl J Med* 2002;**347**:1143-50.
- 244 **Serra-Prat M**, Jovell AJ, Aymerich M. Efficacy and safety of thrombolytic therapy in pulmonary embolism: meta-analysis of randomised controlled trials (Spanish). *Med Clin (Barc)* 1999;**112**:685-9.
- 245 **Agnelli G**, Becattini C, Kirschstein T. Thrombolysis vs heparin in the treatment of pulmonary embolism: a clinical outcome-based meta-analysis. *Arch Intern Med* 2002;**162**:2537-41.
- 246 **Gisselbrecht M**, Diehl JL, Meyer G, *et al*. Comparison of efficacy and tolerability of a thrombolytic treatment with rt-PA in acute massive pulmonary embolism in the elderly and patients under 75 years of age (French). *Rev Med Interne* 1997;**18**:521-7.
- 247 **Kanter DS**, Mikkola KM, Patel SR, *et al*. Thrombolytic therapy for pulmonary embolism. Frequency of intracranial hemorrhage and associated risk factors. *Chest* 1997;**111**:1241-5.

- 248 **Mikkola KM**, Patel SR, Parker JA, *et al*. Increasing age is a major risk factor for hemorrhagic complications after pulmonary embolism thrombolysis. *Am Heart J* 1997;**134**:69–72.
- 249 **Pacouret G**, Barnes SJ, Hopkins G, *et al*. Rapid haemodynamic improvement following saruplase in recent massive pulmonary embolism. *Thromb Haemost* 1998;**79**:264–7.
- 250 **Tebbe U**, Graf A, Kamke W, *et al*. Haemodynamic effects of double bolus reteplase versus alteplase infusion in massive pulmonary embolism. *Am Heart J* 1999;**138**:39–44.
- 251 **Meneveau N**, Schiele F, Vuilleminot A, *et al*. Streptokinase vs alteplase in massive pulmonary embolism. A randomised trial assessing right heart haemodynamics and pulmonary vascular obstruction. *Eur Heart J* 1997;**18**:1141–8.
- 252 **Meneveau N**, Schiele F, Metz D, *et al*. Comparative efficacy of a two-hour regimen of streptokinase versus alteplase in acute massive pulmonary embolism: immediate clinical and haemodynamic outcome and one-year follow-up. *J Am Coll Cardiol* 1998;**31**:1057–63.
- 253 **Schmitz-Rode T**, Kilbinger M, Gunther RW. Simulated flow pattern in massive pulmonary embolism: significance for selective intrapulmonary thrombolysis. *Cardiovasc Intervent Radiol* 1998;**21**:199–204.
- 254 **Verstraete M**, Miller GA, Bounameaux H, *et al*. Intravenous and intrapulmonary recombinant tissue-type plasminogen activator in the treatment of acute massive pulmonary embolism. *Circulation* 1988;**77**:353–60.
- 255 **Meyer G**, Gisselbrecht M, Diehl JL, *et al*. Incidence and predictors of major hemorrhagic complications from thrombolytic therapy in patients with massive pulmonary embolism. *Am J Med* 1998;**105**:472–7.
- 256 **Fava M**, Loyola S, Flores P, *et al*. Mechanical fragmentation and pharmacologic thrombolysis in massive pulmonary embolism. *J Vasc Intervent Radiol* 1997;**8**:261–6.
- 257 **Murphy JM**, Mulvihill N, Mulcahy D, *et al*. Percutaneous catheter and guidewire fragmentation with local administration of recombinant tissue plasminogen activator as a treatment for massive pulmonary embolism. *Eur Radiol* 1999;**9**:959–64.
- 258 **Voigtlander T**, Rupprecht HJ, Nowak B, *et al*. Clinical application of a new rheolytic thrombectomy catheter system for massive pulmonary embolism. *Catheter Cardiovasc Interv* 1999;**47**:91–6.
- 259 **Fava M**, Loyola S, Huete I. Massive pulmonary embolism: treatment with the hydrolyser thrombectomy catheter. *J Vasc Intervent Radiol* 2000;**11**:1159–64.
- 260 **Schmitz-Rode T**, Janssens U, Duda SH, *et al*. Massive pulmonary embolism: percutaneous emergency treatment by pigtail rotation catheter. *J Am Coll Cardiol* 2000;**36**:375–80.
- 261 **Müller-Hülsbeck S**, Brossmann J, Jahnke T, *et al*. Mechanical thrombectomy of major and massive pulmonary embolism with use of the Amplatzer thrombectomy device. *Invest Radiol* 2001;**36**:317–22.
- 262 **De Gregorio MA**, Gimeno MJ, Mainar A, *et al*. Mechanical and enzymatic thrombolysis for massive pulmonary embolism. *J Vasc Intervent Radiol* 2002;**13**:163–9.
- 263 **Zwaan M**, Kripke N, Lorch H, *et al*. In-vitro evaluation of different embolectomy catheters for the treatment of acute pulmonary embolism (German). *Rofo Fortschr* 1999;**171**:485–91.
- 264 **Doerge H**, Schoendube FA, Voss M, *et al*. Surgical therapy of fulminant pulmonary embolism: early and late results. *Thorac Cardiovasc Surg* 1999;**47**:9–13.
- 265 **Chartier L**, Michon P, Loubeyre C, *et al*. Mobile right heart thrombi in pulmonary embolism (French). *Arch Mal Coeur Vaiss* 1997;**90**:1471–6.
- 266 **Casazza F**, Agostoni O, Mandelli V, *et al*. The cardiologist facing pulmonary embolism: the experience of 160 cases of acute cor pulmonale (Italian). *Ital Heart J* 2000;**1**:520–6.
- 267 **Courtney DM**, Sasser HC, Pincus CL, *et al*. Pulseless electrical activity with witnessed arrest as a predictor of sudden death from massive pulmonary embolism in outpatients. *Resuscitation* 2001;**49**:265–72.
- 268 **Kurkciyan I**, Meron G, Sterz F, *et al*. Pulmonary embolism as a cause of cardiac arrest: presentation and outcome. *Arch Intern Med* 2000;**160**:1529–35.
- 269 **Ruiz-Bailen M**, Aguayo-de-Hoyos E, Serrano-Corcoles MC, *et al*. Thrombolysis with recombinant tissue plasminogen activator during cardiopulmonary resuscitation in fulminant pulmonary embolism. A case series. *Resuscitation* 2001;**51**:97–101.
- 270 **Kawahito K**, Murata S, Adachi H, *et al*. Resuscitation and circulatory support using extracorporeal membrane oxygenation for fulminant pulmonary embolism. *Artif Organs* 2000;**24**:427–30.
- 271 **Simonneau G**, Sors H, Charbonnier B, *et al*. A comparison of low-molecular-weight heparin with unfractionated heparin for acute pulmonary embolism. The THESEE Study Group. *N Engl J Med* 1997;**337**:663–9.
- 272 **Hirsh J**, Warkentin TE, Shaughnessy SG, *et al*. Heparin and low-molecular-weight heparin mechanisms of action, pharmacokinetics, dosing, monitoring, efficacy, and safety. *Chest* 2001;**119**:64–94S.
- 273 **Hyers TM**, Agnelli G, Hull RD, *et al*. Antithrombotic therapy for venous thromboembolic disease. *Chest* 2001;**119**:176S–93S.
- 274 **Wells PS**, Kovacs MJ, Bormanis J, *et al*. Expanding eligibility for outpatient treatment of deep venous thrombosis and pulmonary embolism with low-molecular-weight heparin: a comparison of patient self-injection with homecare injection. *Arch Intern Med* 1998;**158**:1809–12.
- 275 **Dolovich LR**, Ginsberg JS, Douketis JD, *et al*. A meta-analysis comparing low-molecular-weight heparins with unfractionated heparin in the treatment of venous thromboembolism: examining some unanswered questions regarding location of treatment, product type, and dosing frequency. *Arch Intern Med* 2000;**160**:181–8.
- 276 **Kovacs MJ**, Anderson D, Morrow B, *et al*. Outpatient treatment of pulmonary embolism with dalteparin. *Thromb Haemost* 2000;**83**:209–11.
- 277 **Merli G**, Spiro TE, Olsson CG, *et al*. Subcutaneous enoxaparin once or twice daily compared with intravenous unfractionated heparin for treatment of venous thromboembolic disease. *Ann Intern Med* 2001;**134**:191–202.
- 278 **Van den Belt AG**, Prins MH, Lensing AW, *et al*. Fixed dose subcutaneous low molecular weight heparins versus adjusted dose unfractionated heparin for venous thromboembolism. *Cochrane Database Syst Rev* 2000:CD001100.
- 279 **Hull RD**, Raskob GE, Brant RF, *et al*. Low-molecular-weight heparin vs heparin in the treatment of patients with pulmonary embolism. American-Canadian Thrombosis Study Group *Arch Intern Med* 2000;**160**:229–36.
- 280 **Couturaud F**, Julian JA, Kearon C. Low molecular weight heparin administered once versus twice daily in patients with venous thromboembolism: a meta-analysis. *Thromb Haemost* 2001;**86**:980–4.
- 281 **Wähländer K**, Lapidus L, Olsson C-G, *et al*. Pharmacokinetics, pharmacodynamics and clinical effects of the oral direct thrombin inhibitor ximelagatran in acute treatment of patients with pulmonary embolism and deep vein thrombosis. *Thromb Res* 2002;**107**:93–9.
- 282 **British Thoracic Society**. Optimum duration of anticoagulation for deep-vein thrombosis and pulmonary embolism. *Lancet* 1992;**340**:873–6.
- 283 **Hirsh J**. The optimal duration of anticoagulant therapy for venous thrombosis. *N Engl J Med* 1995;**332**:1710–1.
- 284 **Schulman S**, Rhedin AS, Lindmarker P, *et al*. A comparison of six weeks with six months of oral anticoagulant therapy after a first episode of venous thromboembolism. *N Engl J Med* 1995;**332**:1661–5.
- 285 **Agnelli G**, Prandoni P, Santamaria MG, *et al*. Three months versus one year of oral anticoagulant therapy for idiopathic deep venous thrombosis. *N Engl J Med* 2001;**345**:165–9.
- 286 **Pinede L**, Ninet J, Duhaut P, *et al*. Comparison of 3 and 6 months of oral anticoagulant therapy after a first episode of proximal deep vein thrombosis or pulmonary embolism and comparison of 6 and 12 weeks of therapy after isolated calf deep vein thrombosis. *Circulation* 2001;**103**:2453–60.
- 287 **Schulman S**, Granqvist S, Holmstrom M, *et al*. The duration of oral anticoagulant therapy after a second episode of venous thromboembolism. The Duration of Anticoagulation Trial Study Group. *N Engl J Med* 1997;**336**:393–8.
- 288 **Hirsh J**, Dalen JE, Anderson DR, *et al*. Oral anticoagulants: mechanism of action, clinical effectiveness, and optimal therapeutic range. *Chest* 2001;**119**:8–21S.
- 289 **Palareti G**, Leali N, Coccheri S, *et al*. Bleeding complications of oral anticoagulant treatment: an inception-cohort, prospective collaborative study. *Lancet* 1996;**348**:423–8.
- 290 **Bigaroni A**, Perrier A, de Moerloose P, *et al*. Risk of major bleeding in unselected patients with venous thromboembolism. *Blood Coagul Fibrinolysis* 2000;**11**:199–202.
- 291 **Levine MN**, Raskob G, Landefeld S, *et al*. Hemorrhagic complications of anticoagulant treatment. *Chest* 2001;**119**:108–21S.
- 292 **Stein P**, Hull R, Raskob G. Withholding treatment in patients with acute pulmonary embolism who have a high risk of bleeding and negative serial non-invasive leg tests. *Am J Med* 2000;**109**:301–6.
- 293 **Odén A**, Fahlén M. Oral anticoagulation and risk of death: a medical record linkage study. *BMJ* 2002;**325**:1073–5.
- 294 **Haire WD**. Vena caval filters for the prevention of pulmonary embolism. *N Engl J Med* 1998;**338**:463–4.
- 295 **Decossus H**, Leizorovicz A, Parent F, *et al*. A clinical trial of vena caval filters in the prevention of pulmonary embolism in patients with proximal deep-vein thrombosis. *N Engl J Med* 1998;**338**:409–15.
- 296 **White R**, Zhou H, Kim J, *et al*. A population-based study of the effectiveness of inferior vena cava filter use among patients with venous thromboembolism. *Arch Intern Med* 2000;**160**:2033–41.
- 297 **Geffroy S**, Furber A, L'Hoste P, *et al*. Very long term outcome of 68 vena caval filters implanted percutaneously (French). *Arch Mal Coeur Vaiss* 2002;**95**:38–44.
- 298 **Asch MR**. Initial experience in humans with a new retrievable inferior vena cava filter. *Radiology* 2002;**225**:835–44.
- 299 **Sing RF**, Jacobs DG, Heniford BT. Bedside insertion of inferior vena cava filters in the intensive care unit. *J Am Coll Surg* 2001;**192**:570–5.
- 300 **De Swiet M**. Management of pulmonary embolism in pregnancy. *Eur Heart J* 1999;**20**:1378–85.
- 301 **Ginsberg JS**, Greer I, Hirsh J. Use of antithrombotic agents during pregnancy. *Chest* 2001;**119**:122–31S.
- 302 **Greer IA**. The acute management of venous thromboembolism in pregnancy. *Curr Opin Obstet Gynecol* 2001;**13**:569–75.
- 303 **Laurent P**, Dussarat GV, Bonal J, *et al*. Low molecular weight heparins: a guide to their optimum use in pregnancy. *Drugs* 2002;**62**:463–77.
- 304 **Douketis J**, Foster G, Crowther M, *et al*. Clinical risk factors and timing of recurrent venous thromboembolism during the initial 3 months of anticoagulant therapy. *Arch Intern Med* 2000;**160**:3431–6.
- 305 **Huffen BA**, Prins MH, Gent M, *et al*. Incidence of recurrent thromboembolic and bleeding complications among patients with venous thromboembolism in relation to both malignancy and achieved international normalized ratio: a retrospective analysis. *J Clin Oncol* 2000;**18**:3078–83.
- 306 **Lee AY**. Treatment of venous thromboembolism in cancer patients. *Thromb Res* 2001;**102**:195–208.
- 307 **Jarrett BP**, Dougherty MJ, Calligaro KD. Inferior vena cava filters in malignant disease. *J Vasc Surg* 2002;**36**:704–7.

**APPENDIX: SUMMARY CHARTS AND NOTES FOR JUNIOR DOCTORS**

Management of suspected non-massive pulmonary embolism (A) with isotope lung scanning off site only and (B) with isotope lung scanning available on site.



### Summary notes for junior doctors

(1) Most patients with PE are breathless and/or tachypnoeic  $>20$ /min; in the absence of these, pleuritic chest pain or haemoptysis is usually due to another cause.

(2) Clinical probability in patients with possible PE may be assessed by asking:

- is another diagnosis unlikely (chest radiograph and ECG are helpful)?
- is there a major risk factor (recent immobility/major surgery/lower limb trauma or surgery, pregnancy/post partum, major medical illness, previous proven VTE)?

Low = neither; Intermediate = either; High = both. Some hospitals prefer to use a scoring system to classify into only low or high (see main document)

(3) D-dimer is very helpful if used wisely:

- it is not a routine "screening" test for PE;
- it should only be considered where there is reasonable suspicion of PE (see 1 above);
- only a negative result is of any value.

It should *not* be performed:

- where an alternative diagnosis is highly likely;
- if clinical probability is high;
- in probable massive PE.

Validated tests that, if negative, exclude PE are:

- SimpliRED (agglutination) for low clinical probability only
- Vidas (ELISA) for low/intermediate clinical probability
- MDA (latex) for low/intermediate clinical probability

(4) Leg ultrasound is an alternative to lung imaging in those with clinical DVT.

(5) Isotope lung scanning is not recommended if:

- unavailable on site, or
- the patient has chronic cardiac or respiratory disease, or
- the chest radiograph is abnormal.

The clinical significance of the report is:

- normal = no PE
- scan + clinical probability both low = no PE
- scan + clinical probability both high = PE present
- any other = needs CTPA

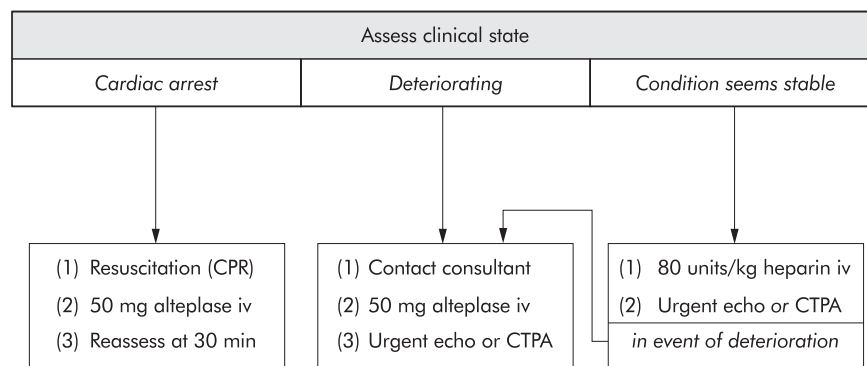
(6) In those with high clinical probability and negative CTPA, valid alternatives are:

- conclude that PE has been excluded and stop heparin;
- consider further imaging for VTE (leg ultrasound, conventional pulmonary angiography);
- seek specialist advice.

(7) Outpatient treatment may be considered if:

- the patient is not unduly breathless, *and*
- there are no medical or social contraindications, *and*
- there is an efficient protocol in place (e.g. as for outpatient DVT management).

### Management of probable massive pulmonary embolism.



#### Comments

1. Massive PE is highly likely if:
  - collapse/hypotension, and
  - unexplained hypoxia, and
  - engorged neck veins, and
  - right ventricular gallop (often)
2. In stable patients where massive PE has been confirmed, iv dose of alteplase is 100 mg in 90 min (i.e. accelerated myocardial infarction regimen).
3. Thrombolysis is followed by unfractionated heparin after 3 hours, preferably weight adjusted.
4. A few units have facilities for clot fragmentation via pulmonary artery catheter. Elsewhere, contraindications to thrombolysis should be ignored in life threatening PE.
5. "Blue light" patients with out-of-hospital cardiac arrest due to PE rarely recover.