

LUNG CANCER

Differential expression of VASP in normal lung tissue and lung adenocarcinomas

L Dertsiz, G Ozbilim, Y Kayisli, G A Gokhan, A Demircan and U A Kayisli

Thorax 2005;60:576–581. doi: 10.1136/thx.2004.037622

See end of article for authors' affiliations

Correspondence to:
Dr L Dertsiz, Department of Thoracic Surgery, School of Medicine, Akdeniz University, Antalya 07070, Turkey; leventdertsiz@akdeniz.edu.tr

Received
13 November 2004
Accepted 26 April 2005

Background: Vasodilator stimulated phosphoprotein (VASP) is associated with focal adhesions and is thought to have an important role in actin filament assembly and cell motility. We hypothesise that an increase in the expression of VASP is involved in the progression and invasion of lung adenocarcinomas in parallel to tumour progression. A study was undertaken to analyse VASP expression in normal lung tissue and lung adenocarcinomas.

Methods: Human lung tissues with adenocarcinomas (n = 26) were used. Normal lung tissue specimens (n = 14) were taken from areas a standard distance (3 cm) from resected adenocarcinomas of patients who underwent surgical lung resection. Adenocarcinomas were classified according to pathological staging and histopathological grades. Tissues were stained for VASP using immunohistochemistry.

Results: Normal lung pneumocytes showed no VASP expression while alveolar macrophages had the strongest immunoreactivity for VASP. Bronchial epithelium (surface epithelium, goblet cells) and bronchial gland cells had a very weak immunoreactivity for VASP. Adenocarcinomas had significantly greater VASP expression than normal epithelium (p < 0.001). Moreover, VASP expression in adenocarcinomas increased significantly with more advanced tumour stage (p < 0.001).

Conclusions: The spatial and differential expression of VASP in normal lung tissue and lung adenocarcinomas suggests that it is likely to be involved in the differentiation of normal lung cells to adenocarcinomas. The significant increase in the expression of VASP in adenocarcinomas in parallel to pathological staging suggests that it may regulate the invasive behaviour of lung adenocarcinomas as adenocarcinoma invasion is increased in more advanced tumours.

Vasodilator stimulated phosphoprotein (VASP) is a member of the Ena-VASP family and is a 46 kDa membrane associated protein that was first described in human platelets.¹ VASP is associated with focal adhesions and areas of dynamic membrane activity where it is thought to have an important role in actin filament assembly and cell motility.^{1,2} Previous studies performed in many systems have suggested that this family of proteins has a universal role in the control of cell motility and intracellular actin dynamics via a linear pathway from the receptor-ligand interaction.³ Moreover, VASP phosphorylation correlates well with the reversible inhibition of integrin $\alpha_2\beta_3$ (also known as fibrinogen receptor or platelet glycoprotein IIb-IIIa).⁴ In the intracellular environment, VASP is associated with filamentous actin formation and is involved in intracellular signalling pathways of the integrin-extracellular matrix (ECM) interaction. It is therefore suggested that this molecule might play a part in cell adhesion and motility.⁵

Lung cancer is the most common fatal malignancy worldwide. Approximately 80–90% of cases involve non-small cell carcinoma.⁶ Non-small cell carcinomas are subdivided into several histological types including squamous cell carcinoma, adenocarcinoma, and large cell undifferentiated carcinoma.⁷ Although pulmonary adenocarcinoma is the most common histological subtype (39% and 36.3% in the United States and Japan, respectively),^{8,9} its pathobiological features are not fully understood. Prognostic factors have a pivotal role in clinical oncology. They are helpful in the selection of treatment and provide insights into the disease process and the therapeutic response. The number of possibly useful prognostic factors in lung cancer is large.^{10–13}

Understanding the expression and role of VASP in cells is likely to lead to the development of new therapeutic strategies for diseases including tumour growth and atherosclerosis.²

No studies to date have examined VASP expression in normal lung and lung cancers and, since previous studies have suggested that VASP may be involved in trophoblast invasion, angiogenesis, cell proliferation and tumorigenesis,^{14–17} we hypothesised that an increased expression of VASP might be involved in the progression and invasion of lung cancer in parallel to tumour progression. We therefore analysed formalin fixed, paraffin embedded tissues of normal lung and lung with adenocarcinomas obtained from surgically treated patients. VASP expression was studied by immunohistochemistry.

METHODS

Collection of tissues

Specimens of human lung tissue with adenocarcinomas (n = 26) were collected from surgically treated patients who gave their informed consent. Normal lung tissue samples (n = 14) were taken from areas a standard distance (3 cm) from resected adenocarcinomas of patients who underwent surgical lung resection. All tissue samples were collected during the 3 year period between October 2000 and May 2003. Normal lung tissue sections were histopathologically assessed for tumour cells and apparent pathological features and were only included in the study if they were morphologically normal. Consent forms and protocols were approved by Human Investigation Committees of Akdeniz University. Tissues were fixed in formalin fixative and embedded in paraffin for immunohistochemical analysis. They were then cut into 5 μ m thick sections and mounted on poly-L-lysine coated slides. Immunohistochemical analysis was carried out

Abbreviations: ECM, extracellular matrix; VASP, vasodilator stimulated phosphoprotein

Table 1 Characteristics of study patients

Patient no	Age/sex	pTNM*	Stage	Histological differentiation	Surgical intervention
1	53/F	T2N2M0	3a	Well	Right upper and middle lobectomies
2	55/M	T2N1M0	2b	Well	Left lower lobectomy
3	60/M	T2N0M0	1b	Well	Left upper lobectomy
4	67/M	T2N0M0	1b	Well	Right upper lobectomy
5	79/M	T3N0M0	2b	Well	Left upper lobectomy
6	65/F	T1N0M0	1a	Well	Left upper lobectomy
7	62/M	T1N0M0	1a	Well	Right upper lobectomy
8	59/M	T2N1M0	2b	Well	Right upper and middle lobectomies
9	50/M	T3N0M0	2b	Well	Right upper lobectomy
10	56/M	T2N2M0	3a	Moderate	Right lower lobectomy
11	59/M	T1N1M0	2a	Moderate	Left lower lobectomy
12	67/M	T2N0M0	1b	Moderate	Left upper lobectomy
13	62/M	T1N0M0	1a	Moderate	Right lower lobectomy
14	57/M	T1N0M0	1a	Moderate	Right upper lobectomy
15	51/M	T2N2M0	3a	Moderate	Right upper lobectomy
16	59/M	T1N0M0	1a	Moderate	Left upper lobectomy
17	58/F	T2N1M0	2b	Poorly	Right lower and middle lobectomies
18	61/M	T2N2M0	3a	Poorly	Left lower lobectomy
19	70/M	T2N1M0	2b	Poorly	Right pneumonectomy
20	70/M	T3N1M0	3a	Poorly	Left lower lobectomy
21	68/M	T2N2M0	3a	Poorly	Right middle lobectomy
22	56/M	T2N1M0	2b	Poorly	Left upper lobectomy
23	66/M	T3N1M1	4**	Poorly	Right upper lobectomy
24	59/M	T2N2M1	4**	Poorly	Left lower lobectomy
25	39/M	T3N2M0	3a	Poorly	Left lower lobectomy
26	59/F	T3N2M0	3a	Poorly	Right middle lobectomy

*pTNM, pathological TNM.

**Patients with a solitary brain metastasis.

using a standardised method based on the streptavidin-biotin technique described below.

None of the patients had undergone chemotherapy before surgery and all lung adenocarcinomas were the initial presentation. Pathological staging was performed according to the surgical resection materials and systematic mediastinal lymph node dissection: stage 1 (n = 7), stage 2 (n = 9), stage 3 (n = 8) and stage 4 (n = 2).¹⁸ The tumours were also graded histopathologically as well differentiated (grade I; n = 9), moderately differentiated (grade II; n = 7) and poorly differentiated (grade III; n = 10).¹⁹

Immunohistochemistry

To detect VASP immunoreactivity a mouse monoclonal antibody (Alexis Platform, San Diego, CA, USA) was used. Following deparaffinisation of sections, tissues were rinsed twice in phosphate buffer saline (PBS) for 10 minutes. Endogenous peroxidase activity was quenched by 0.6 ml 3% hydrogen peroxide (H₂O₂) and 5.4 ml methanol for 10 minutes and rinsed in 0.05% Tween-20 in PBS (PBS-T; pH 7.3). Sections were then incubated with mouse anti-VASP (1:400 dilution) for 60 minutes at room temperature. Normal mouse antibody isotype was used as a negative control replacing primary antibody. After several rinses in PBS-T, biotinylated horse anti-mouse IgG antibody (Vector Labs, Burlingame, CA, USA) was applied for 30 minutes. Following several PBS-T rinses, slides were incubated with streptavidin-peroxidase complex for 30 minutes (Vector Labs), then rinsed several times in PBS-T and incubated with DAB (Vector Labs) for 2 minutes. After slight staining with haematoxylin the slides were mounted using a permanent mounting medium.^{14, 15}

Histological scoring (HSCORE) was performed as described previously.^{20, 21} The intensity of VASP immunoreactivity in lung tissues was semi-quantitatively evaluated as positively stained cells using the following intensity categories: – (no staining), 1+ (weak but detectable staining), 2+ (moderate or distinct staining), 3+ (intense staining). For each tissue a HSCORE value was derived by summing the percentages of cells stained at each intensity category and multiplying that

value by the weighted intensity of the staining using the formula:

$$\text{HSCORE} = P_i (i + 1)$$

where i represents the intensity scores and P_i is the corresponding percentage of the cells. Two slides were stained for each patient; in each slide three different areas and 500 cells in each area were evaluated under a microscope with 40× objective magnification. Two investigators (12% interobserver variability) who were blind to the slides determined the percentage of cells and the mean of their scores was used.²¹

Statistical analysis

Patients with pathological stages 1 and 2 tumours and those with stages 3 and 4 were combined for comparison. Semi-quantitative results of VASP were normally distributed as assessed by the Kolmogorov-Smirnov test. Analysis of variance (ANOVA) and the post hoc Tukey test for pairwise comparisons were used in statistical analysis. A p value of <0.05 was considered significant. Statistical calculations were performed using Sigmastat for Windows, Version 3.0 (Jandel Scientific Corporation, San Rafael, CA, USA).

RESULTS

Of the 26 patients with adenocarcinomas, 22 (84.6%) were men. The mean age of the patients was 59.7 years (range 39–79). Details of the clinical evaluation of the adenocarcinomas such as nodal or distant metastases are shown in table 1. Adenocarcinomas were classified as stage 1–2 (n = 16) or stage 3–4 (n = 10) after clinical and pathological examination (table 1).

VASP expression in normal lung tissue

VASP expression was first analysed in normal lung tissue. No VASP expression was observed in pneumocytes (fig 1A) but alveolar macrophages showed moderate to strong immunoreactivity for VASP and the staining was mostly membranous (fig 1B). Vascular smooth muscle cells showed weak to moderate immunoreactivity for VASP and the staining model was in the cytosol and was homogenous (fig 1A, C).

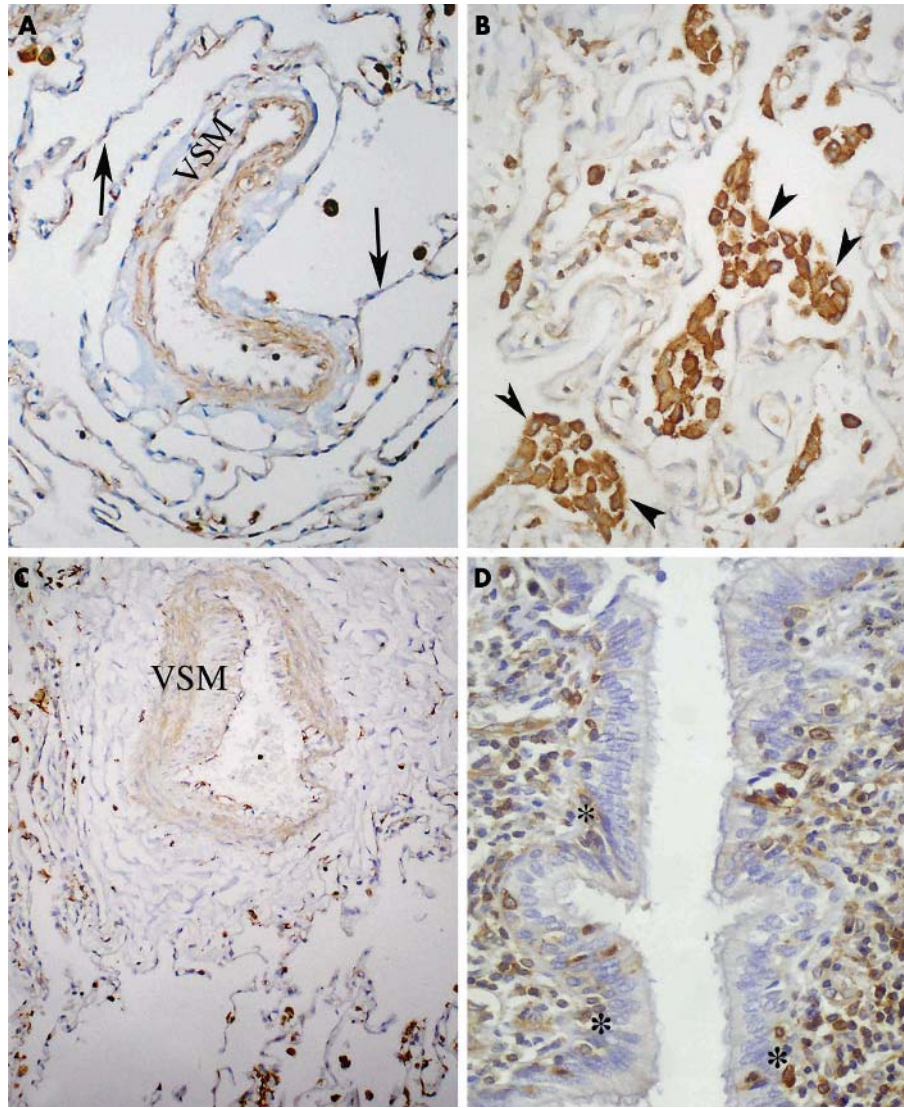


Figure 1 Representative micrographs of normal human lung tissue immunolabelled for VASP. No VASP immunoreactivity is seen in pneumocytes (A, arrows). The strongest immunoreactivity is seen in alveolar macrophages (B, arrowheads). Vascular smooth muscle cells (VSM) showed moderate immunoreactivity for VASP (A, C) and bronchial epithelial cells had very weak or no VASP immunoreactivity (D). A few parabasal cells were strongly positive for VASP (D, stars). Magnification: A, B, D $\times 100$; C, $\times 50$.

Bronchial gland cells and epithelial cells (surface epithelium, goblet cells) showed weak VASP immunoreactivity but some parabasal cells were moderately positive (fig 1D). All normal lung specimens had a similar immunohistochemical staining pattern for VASP.

VASP expression in lung tissue with adenocarcinomas

We first analysed the lung cells neighbouring the adenocarcinoma tissue on the same slide and found no difference in VASP expression from that of normal cells. Pneumocytes had no VASP expression while alveolar macrophages had moderate to strong immunoreactivity for VASP in lung samples with adenocarcinomas (fig 2A). No difference in VASP immunoreactivity was detected in alveolar macrophages or vascular smooth muscle cells between the groups (fig 2A).

The highest VASP immunoreactivity was detected in stage 3–4 adenocarcinoma tissue (fig 2B). Compared with normal bronchial epithelial cells, VASP expression was significantly higher in both stage 1–2 and stage 3–4 adenocarcinoma groups (fig 1D *v* fig 2B and C, $p < 0.001$). Moreover, VASP

expression in stage 3–4 adenocarcinomas was significantly higher than in stage 1–2 adenocarcinomas (fig 2B *v* fig 2C, $p < 0.001$; fig 3).

Adenocarcinomas were also classified pathologically as well differentiated (grade I), moderately differentiated (grade II), and poorly differentiated (grade III). These differentiated cells generally showed moderate to strong immunoreactivity. Although there was a tendency for VASP immunoreactivity to increase from grade I to grade III, no statistically significant difference was found between the grades ($p = 0.229$, fig 4). However, the adenocarcinoma cells of each grade revealed a statistically significant increase in VASP expression compared with normal bronchial epithelial cells ($p < 0.001$, fig 4).

DISCUSSION

The pathobiological characteristics of adenocarcinoma of the lung have not been completely delineated which makes it difficult to predict precisely the outcome after complete resection of the tumour. Many tumour related factors such as stage, histological type, pathological grade, and expression and activation status of p53, K-ras and c-erbB proteins have

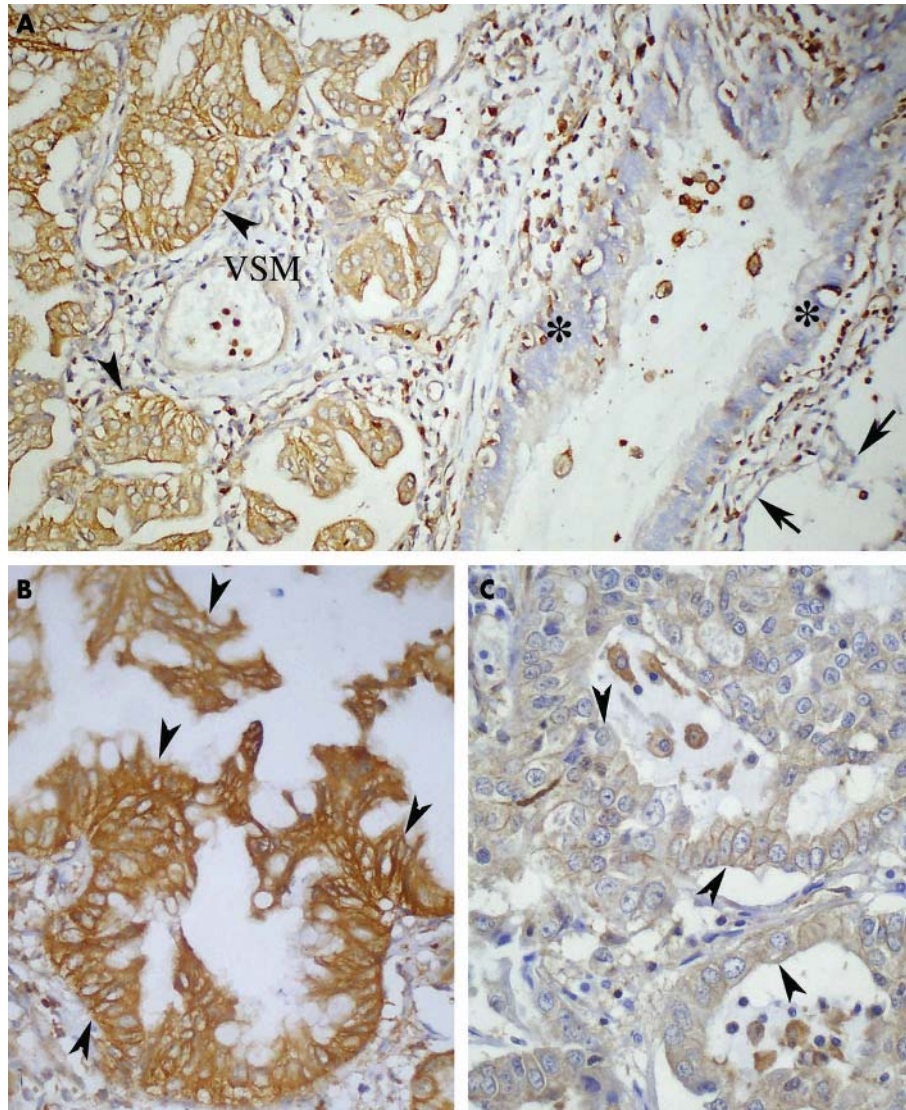


Figure 2 Representative micrographs of human lung tissue with adenocarcinomas immunolabelled for VASP. (A) No VASP immunoreactivity is seen in pneumocytes (arrows) and very weak immunoreactivity was found in the epithelium (stars). The strongest immunoreactivity is seen in adenocarcinoma cells (arrowheads) where vascular smooth muscle cells (VSM) show weak to moderate immunoreactivity for VASP. (B) Considerably increased VASP immunoreactivity is seen in stage 3 adenocarcinomas (arrowheads) compared with normal bronchial epithelium (A) and stage I adenocarcinomas (C). Magnification: A $\times 50$; B, C $\times 100$.

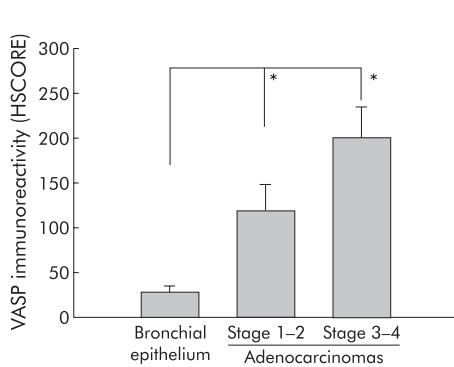


Figure 3 Comparison of VASP immunoreactivity in normal bronchial epithelium, stage 1–2 adenocarcinomas, and stage 3–4 adenocarcinomas. Bronchial epithelium represents VASP immunoreactivity in normal lung tissue. All values are shown as mean (SD). * $p < 0.001$.

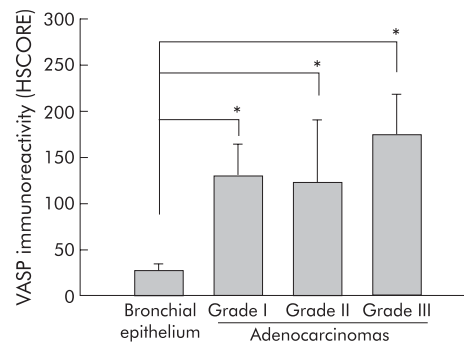


Figure 4 Comparison of VASP immunoreactivity in normal bronchial epithelial cells and lung adenocarcinomas graded pathologically as grades I, II, and III. Bronchial epithelium represents VASP immunoreactivity in normal lung bronchial epithelial cells. No significant difference was found between the adenocarcinoma grades ($p = 0.229$). All values are shown as mean (SD). * $p < 0.001$.

been reported to be related to recurrence and survival of patients with adenocarcinoma.^{22–25} The cellular and molecular functions of VASP remain to be determined since it is a multifunctional protein which is associated with filamentous actin formation and is involved in the intracellular signalling pathway of the integrin-ECM interaction. It has therefore been suggested that it participates in cell adhesion and motility.⁵ As a membrane associated protein, VASP is widely distributed in the cytoplasm of migrating cells, especially at the leading edge of the cytoplasm. Moreover, this family of proteins is involved in focal adhesions.²⁶

Previous studies have suggested that the VASP protein family has a universal role in the control of cell motility and in the regulation of intracellular actin dynamics via a linear pathway from the receptor-ligand interaction in many systems.³ In this study, to our knowledge, we have shown for the first time that VASP has a spatial expression pattern in lung tissues depending on the cell type. In normal lung tissue VASP shows the strongest immunoreactivity in alveolar macrophages; these are migratory cells and it is possible that VASP may be involved in regulating the migration of these cells. The absence of VASP from pneumocytes and its very weak expression in normal bronchial epithelial cells—which are accepted as the main cell origin of adenocarcinomas—also support this suggestion since these cells are non-migratory cells of normal lung tissue. Furthermore, the presence of weak but membranous expression of VASP in the bronchial epithelium may suggest a role for VASP in cell-cell junctions where it modulates the formation of filamentous actin in cell-cell binding, since it has previously been found to bind to components of cadherin-catenin junctional complex and the transmission of signals at the cytoskeleton-membrane interface.¹⁴ Localisation of VASP to the leading edge of a migrating cell can lead to the local accumulation of profilin which, in turn, can supply actin monomers to growing filament ends. VASP binds to the focal adhesion proteins vinculin and zyxin and this probably directs the phosphoprotein to focal adhesions and the leading edge of stimulated cells.

Major therapeutic approaches in cancer have been based on inhibition of the ras signalling pathway with special emphasis on the MAPK arm.²⁵ Transformation from benign to malignant cells can be affected by the expression of rho GTPases and ras effectors. In malignant epithelial cells inhibition of MAPK-*rac1* signalling alters the expression and localisation of the actin regulating proteins vinculin and VASP which results in the loss of stable F-actin structures and the characteristics of actin based differentiation. The interaction between *rac1* and VASP could therefore be an important target for cancer treatment.²⁷

Previous studies have suggested that VASP may have a role in trophoblast invasion, angiogenesis, cell proliferation, and tumorigenesis.^{14–16} In the present study we have shown that VASP expression is higher in adenocarcinomas than in normal bronchial epithelial cells and pneumocytes. Although we did not study the molecular mechanisms by which VASP could regulate tumorigenesis, we hypothesise that VASP may be involved in the transformation from normal bronchial epithelium and bronchial gland cells to adenocarcinomas. Moreover, the fact that VASP immunoreactivity increases in parallel with tumour stage and that there is a statistically significant correlation between increasing VASP immunoreactivity and stage 3–4 adenocarcinomas suggests that the protein may assist in tissue invasion by adenocarcinomas. It has previously been shown that preventing VASP function or overproduction of VASP in naive NIH 3T3 fibroblasts results in neoplastic transformation, implying that normal cell growth may require the maintenance of VASP expression within a narrow range and

suggesting a role for VASP in tumorigenesis and/or cancer progression.¹⁷

There was no difference in VASP expression between adenocarcinomas of different grades, but a significant increase in VASP immunoreactivity was found with advancing adenocarcinoma stages from 1 to 4. This finding agrees with the results of previous studies implying that prognostic criteria in lung adenocarcinoma are related to the stage of the disease rather than the grade.^{28–31}

In conclusion, our results show for the first time the spatial and differential expression of VASP in normal lung tissue and in lung adenocarcinomas. A gradual increase in VASP expression in adenocarcinoma tissue in parallel to the increase in stage suggests that VASP may be involved in the invasive behaviour of lung adenocarcinomas, possibly by regulating intracellular F-actin formation, focal adhesion, and cell migration since adenocarcinoma invasion increases with increasing stage. Furthermore, we speculate that VASP may be involved in the differentiation of normal lung cells into lung adenocarcinomas, even though VASP expression is not related to the transformation from poorly to well differentiated adenocarcinoma tissue.

Authors' affiliations

L Dertsiz, A Demircan, Department of Thoracic Surgery, School of Medicine, Akdeniz University, Antalya, Turkey
G Ozbilim, G A Gokhan, Department of Pathology, School of Medicine, Akdeniz University, Antalya, Turkey
Y Kayisli, U A Kayisli, Department of Histology and Embryology School of Medicine, Akdeniz University, Antalya, Turkey

This study was funded in part by Akdeniz University Scientific Research Project Unit.

REFERENCES

- Halbrugge M, Walter U. Purification of a vasodilator-regulated phosphoprotein from human platelets. *Eur J Biochem* 1989;**185**:41–50.
- Holt MR, Critchley DR, Brindle NP. The focal adhesion phosphoprotein, VASP. *Int J Biochem Cell Biol* 1998;**30**:307–11.
- Machesky LM. Putting on the brakes: a negative regulatory function for Ena/VASP proteins in cell migration. *Cell* 2000;**101**:685–8.
- Horstrup K, Jablonka B, Honig-Liedl P, et al. Phosphorylation of focal adhesion vasodilator-stimulated phosphoprotein at Ser157 in intact human platelets correlates with fibrinogen receptor inhibition. *Eur J Biochem* 1994;**225**:21–7.
- Halbrugge M, Eigenthaler M, Polke C, et al. Protein phosphorylation regulated by cyclic nucleotide-dependent protein kinases in cell extracts and in intact human lymphocytes. *Cell Signal* 1992;**4**:189–99.
- Gibbs AR, Thunnissen FB. Histological typing of lung and pleural tumors (3rd edition). *J Clin Pathol* 2001;**54**:498–9.
- The World Health Organization histological typing of lung tumors (2nd edition). *Am J Clin Pathol* 1982;**77**:123–36.
- Watanabe S, Tsugane S, Arimoto H, et al. Trend of lung cancers in the National Cancer Center of Japan and comparison with that of Japanese pathological autopsy records. *Jpn J Cancer Res* 1987;**78**:460–6.
- Valaitis J, Warren S, Gamble D. Increasing incidence of adenocarcinoma of the lung. *Cancer* 1981;**47**:1042–6.
- Buccheri G, Ferrigno D. Prognostic factors in lung cancer: tables and comments. *Eur Respir J* 1994;**7**:1350–64.
- Fong KM, Sekido Y, Gazdar AF, et al. Lung cancer. 9: Molecular biology of lung cancer, clinical implications. *Thorax* 2003;**58**:892–900.
- Paleri C, Morero JL, Nieva B, et al. Risk of recurrence in patients with surgically resected stage I non-small lung carcinoma. Histopathologic and immunohistochemical analysis. *Chest* 2003;**123**:1858–67.
- Janssen-Heijnen ML, Smulders S, Lemmens VE, et al. Effect of comorbidity on the treatment and prognosis of elderly patients with non-small cell lung cancer. *Thorax* 2004;**59**:602–7.
- Kayisli UA, Selam B, Demir R, et al. Expression of vasodilator-stimulated phosphoprotein in human placenta: possible implications in trophoblast invasion. *Mol Hum Reprod* 2002;**8**:88–94.
- Kayisli UA, Demir R, Erguler G, et al. Vasodilator-stimulated phosphoprotein expression and its cytokine-mediated regulation in vasculogenesis during human placental development. *Mol Hum Reprod* 2002;**8**:1023–30.
- Chen L, Daum G, Chitale K, et al. Vasodilator-stimulated phosphoprotein regulates proliferation and growth inhibition by nitric oxide in vascular smooth muscle cells. *Arterioscler Thromb Vasc Biol* 2004;**24**:1403–8.
- Liu K, Li L, Nisson PE, et al. Reversible tumorigenesis induced by deficiency of vasodilator-stimulated phosphoprotein. *Mol Cell Biol* 1999;**19**:3696–703.
- Mountain CF. Revisions in the International System for Staging Lung Cancer. *Chest* 1997;**111**:1710–7.

- 19 **Nomori H**, Matsuno Y, Naguchi M, *et al.* Adenocarcinoma of the lung with selective metastasis to the lung: clinical, histologic and DNA-cytofluorometric analyses. *Jpn J Cancer Res* 1992;**83**:93–100.
- 20 **Bacus S**, Flowers JL, Press MF, *et al.* The evaluation of estrogen receptor in primary breast carcinoma by computer-assisted image analysis. *Am J Clin Pathol* 1988;**90**:233–9.
- 21 **Guzeloglu-Kayisli O**, Kayisli UA, Al-Rejjal R, *et al.* Regulation of PTEN (Phosphatase and Tensin Homolog Deleted on Chromosome 10) expression by estradiol and progesterone in human endometrium. *J Clin Endocrinol Metab* 2003;**88**:5017–26.
- 22 **Naruke T**, Tsuchiya R, Kondo H, *et al.* Prognosis and survival after resection for bronchogenic carcinoma based on the 1997 TNM-staging classification: the Japanese experience. *Ann Thorac Surg* 2001;**71**:1759–64.
- 23 **Sorensen JB**, Hirsch FR, Gazdar A, *et al.* Interobserver variability in histopathologic subtyping and grading of pulmonary adenocarcinoma. *Cancer* 1993;**71**:2971–6.
- 24 **Huang CL**, Taki T, Adachi M, *et al.* Mutations of p53 and K-ras genes as prognostic factors for non-small cell lung cancer. *Int J Oncol* 1998;**12**:553–63.
- 25 **Fontanini G**, De Laurentiis M, Vignati S, *et al.* Evaluation of epidermal growth factor-related growth factors and receptors and of neoangiogenesis in completely resected stage I-IIIa non-small-cell lung cancer: amphiregulin and microvessel count are independent prognostic indicators of survival. *Clin Cancer Res* 1998;**4**:241–9.
- 26 **Niebuhr K**, Ebel F, Frank R, *et al.* A novel proline-rich motif present in ActA of *Listeria monocytogenes* and cytoskeletal proteins is the ligand for the EVH1 domain, a protein module present in the Ena/VASP family. *EMBO J* 1997;**16**:5433–44.
- 27 **Quinlan MP**. Suppression of epithelial cell transformation and induction of actin dependent differentiation by dominant negative Rac1, but not Ras, Rho or Cdc42. *Cancer Biol Ther* 2004;**3**:65–70.
- 28 **Asamura H**, Ando M, Matsuno Y, *et al.* Histopathologic prognostic factors in resected adenocarcinomas. *Chest* 1999;**115**:1018–24.
- 29 **Ichinose Y**, Hara N, Ohta M, *et al.* Is T factor of the TNM staging system a predominant prognostic factor in pathologic stage I non-small-cell lung cancer? A multivariate prognostic factor analysis of 151 patients. *J Thorac Cardiovasc Surg* 1993;**106**:90–4.
- 30 **Suzuki K**, Nagai K, Yoshida J, *et al.* The prognosis of surgically resected N2 non-small cell lung cancer: the importance of clinical N status. *J Thorac Cardiovasc Surg* 1999;**118**:145–53.
- 31 **Sugarbaker DJ**. Lung cancer. 6: The case for limited surgical resection in non-small cell lung cancer. *Thorax* 2003;**58**:639–41.

LUNG ALERT

Clinical staging underestimates pathological stage in non-small cell lung cancer

▲ López-Encuentra A, García-Luján R, Rivas JJ, *et al.* Comparison between clinical and pathologic staging in 2,994 cases of lung cancer. *Ann Thorac Surg* 2005;**79**:974–9

Clinical staging of lung cancer should establish a cTNM reliably predictive of the pathological stage. This study analysed 2994 lung cancers, operated on with curative intent in Spain between 1993 and 1997, with the aim of determining the agreement between clinical and pathological staging.

93% of patients were male with a 57.5 pack-year smoking history. In 29% of the cases lung cancer was an incidental radiological finding. 98% of the cancers were non-small cell (59% squamous) and 80% underwent complete resection (55% lobectomy/bilobectomy, 32% pneumonectomy). Of the 2994 patients initially included in the series, 2606 had a clinical staging, 2710 were classified using the pathological staging, and a clinicopathological comparison was performed in 2377 cases (79%). The clinicopathological agreement for stages IA–IIIB was 47% (Kappa's index 0.248), similar to that found in other studies (35–55%). The highest agreement (75%) was achieved for stages IA and IB (Kappa's index 0.56) and the lowest for stages IIIB (22%) and IIIA (8%). Clinical staging underestimated the pathological staging in 92% of stage IIA, 86% of IIIA, 74% of IIB, and 15% of IB tumours. Differences in staging protocols and in the characteristics of the population studied are likely to explain variability in the results between different studies. Future studies, using integrated positron emission tomography (PET)/CT scanning, are likely to result in a better agreement between clinical and pathological staging. This is important for treatment planning and the provision of accurate prognostic information.

L Camporota

Research Registrar, Guy's & St Thomas' NHS Foundation Trust, London, UK;
luigicamporota@yahoo.co.uk