

Images in *Thorax*

Pulmonary sequestration supplied by a coronary artery

A 59 year old woman presented with chest tightness radiating to her back and shortness of breath. The ECG and cardiac enzymes were consistent with an acute apical inferior myocardial infarction. Her past medical history was significant for a 47 year history of four episodes of pneumonia with haemoptysis. She carried a diagnosis of a “lung scar”. A previous CT scan of the thorax showed cystic changes in the left lower lobe posterior segment (fig 1). At cardiac catheterisation, in addition to a 70% proximal left anterior descending artery lesion, a large torturous vessel was noted arising from the left circumflex coronary artery and supplying the left lower lobe of the lung (fig 2A and B). Bronchoscopic examination revealed normal left lower lobe basilar segment anatomy and a thoracic MRI scan revealed no other abnormal arterial connections to the left lower lobe. The patient was referred to thoracic surgery for resection.

This entity has been described in the literature 11 times previously with a mean age at presentation of 59.5 years. In the majority of cases it arises from the left circumflex or right coronary artery.^{1,2}

G M Hunninghake

Divisions of Pulmonary and Critical Care Medicine, Brigham and Women's Hospital, Boston, MA, USA

D J Kanarek

Divisions of Pulmonary and Critical Care Medicine, Massachusetts General Hospital, Boston, MA, USA

Correspondence to: Dr G M Hunninghake, Brigham and Women's Hospital, Boston, MA 02115, USA; ghunninghake@partners.org

Competing interests: none declared.

REFERENCES

- 1 **Briancon S**, Neimann JL, Cuilliere M, *et al*. Abnormal vascularisation of the right inferior pulmonary lobe an aberrant coronary artery. A propos of two uncommon cases. *Arch Mal Coeur Vaiss* 1981;**74**:481–6.

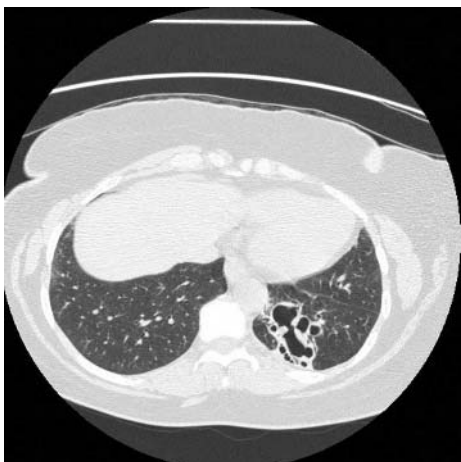

Figure 1 Thoracic CT scan showing cystic changes in the left lower lobe posterior segment.

Learning point

- Pulmonary sequestration supplied by a coronary artery is a rare clinical entity but should be suspected in patients with symptoms consistent with coronary artery disease and a history of haemoptysis.

- 2 **Morii K**, Kayama D, Shimizu Y, *et al*. Pulmonary pseudosequestration receiving arterial supply from the right coronary artery: a case report. *J Cardiol* 2002;**39**:271–6.

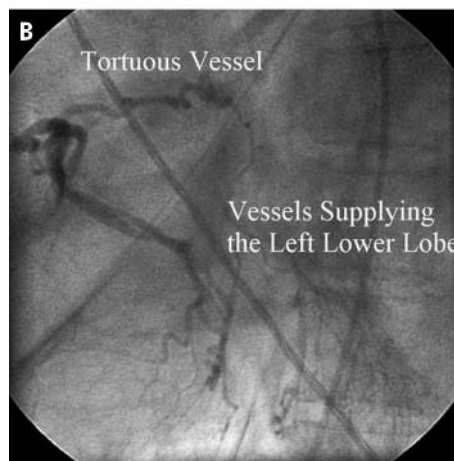
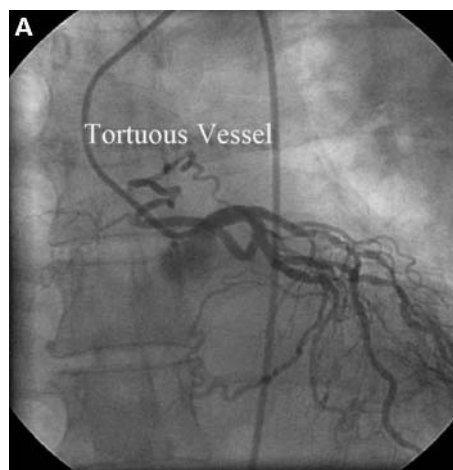


Figure 2 (A) Injection into the left main artery that gives rise to a left anterior descending artery with 70% proximal occlusion. Another branch from the left main artery gives rise to a left circumflex artery with a tortuous accessory branch supplying a region of the left lower lobe of the lung. (B) The tortuous branch arising from the left circumflex artery supplying a blush of vessels within the left lower lobe (LLL) of the lung.