

ORIGINAL ARTICLE

Intravenous atropine treatment in infantile hypertrophic pyloric stenosis

H Kawahara, K Imura, M Nishikawa, M Yagi, A Kubota

Arch Dis Child 2002;**87**:71–74

See end of article for authors' affiliations

Correspondence to:
Dr Kawahara, Division of Paediatric Surgery, Osaka Medical Centre and Research Institute for Maternal and Child Health, 840 Murodo-cho Izumi, Osaka, Japan 594-1101; kawahara@ped surg.med.osaka-u.ac.jp

Accepted
7 February 2002

Aims: To assess the efficacy of a new regimen of intravenous atropine treatment for infantile hypertrophic pyloric stenosis (IHPS) with special reference to regression of pyloric hypertrophy.

Methods: Atropine was given intravenously at a dose of 0.01 mg/kg six times a day before feeding in 19 patients with IHPS diagnosed from radiographic and ultrasonographic findings. When vomiting ceased and the infants were able to ingest 150 ml/kg/day formula after stepwise increases in feeding volume, they were given 0.02 mg/kg atropine six times a day orally and the dose was decreased stepwise.

Results: Of the 19 infants, 17 (89%) ceased projectile vomiting after treatment with intravenous (median seven days) and subsequent oral (median 44 days) atropine administration. The remaining two infants required surgery. No significant complications were encountered. Ultrasonography showed a significant ($p < 0.05$) decrease in pyloric muscle thickness, but no significant shortening of the pyloric canal after completion of the atropine treatment. The patients exhibited failure to thrive at presentation, but were thriving at 6 months of age ($p < 0.01$).

Conclusions: This atropine therapy resulted in satisfactory clinical recovery. Pyloric muscle thickness was significantly reduced.

Redet-Ramstedt pyloromyotomy has been regarded as the optimal treatment for infantile hypertrophic pyloric stenosis (IHPS),¹ although surgical complications have been reported.^{2,3} Medical treatment with oral antispasmodics such as atropine sulphate or methyl scopolamine nitrate have virtually been abandoned since the mid-1960s.⁴⁻⁷ Oral atropine has not worked consistently in infants with frequent projectile vomiting unless given at a high dose. Recently, medical treatment with atropine has been reappraised as an option for IHPS.^{8,9} Nagita *et al*⁸ have reported a high success rate using intravenous atropine treatment. In their regimen, the intravenous dose of atropine was increased stepwise until vomiting was controlled, so the final dose administered varied between patients. We devised a new regimen with a fixed dose of atropine. This study was designed to assess the clinical outcome of our regimen and to look for evidence of regression of pyloric hypertrophy using ultrasonography.

PATIENTS AND METHODS

Patients

Ethical approval was obtained from the departmental committee, and informed consent was obtained from the patients' guardians. The study population consisted of 19 consecutive infants (male/female 16:3) with IHPS, who were in Osaka Medical Centre and Research Institute for Maternal and Child Health in the period November 1996 to March 1998. All fulfilled the following diagnostic criteria for IHPS:

- (a) repeated projectile vomiting more than twice a day;
- (b) gastric outlet obstruction and characteristic narrow, long pyloric canal on upper gastrointestinal series;
- (c) pyloric canal length ≥ 15 mm and pyloric muscle thickening ≥ 4 mm on ultrasonography.

Table 1 shows the patient characteristics. The median (range) age was 40 (22–85) days at admission. Their median (range) weights at birth and admission were 3086 (2480–4430) g and 3970 (3200–5410) g respectively.

Treatment regimen

Atropine was administered intravenously at a dose of 0.01 mg/kg six times a day five minutes before feeding. During atropine infusion, the heart rate was continuously monitored by electrocardiography. Oral feeding was started at a volume of 10 ml formula, six times a day. The volume was increased day by day until patients tolerated 150 ml/kg/day (418 J/kg/day), unless vomiting occurred more than twice a day. Concentrated formula was not given. When patients were able to tolerate the full volume of formula without vomiting more than twice a day, 0.02 mg/kg atropine was administered orally six times a day before feeding. Intravenous atropine treatment was considered unsuccessful if patients failed to tolerate half of the full volume within a week or the full volume within two weeks. They were discharged from the hospital when vomiting was controlled with oral atropine. When patients were free of vomiting and showed steady weight gain, atropine was decreased in three steps (0.12 mg/kg/day, 0.06 mg/kg/day, 0.03 mg/kg/day). If patients vomited more than twice a day for three days after discontinuation of atropine treatment, oral administration was restarted.

Follow up

Successfully treated patients were followed up.

Clinical symptoms

Daily frequency of vomiting, recorded in medical charts during intravenous treatment and in guardians' diaries during oral treatment, was examined at three weeks, three months, and six months after completion of oral atropine administration.

Physical development

Serial changes in body weight were examined at presentation and at the ages of 3 months, 6 months, 1 year, and 2 years. Weights were converted into standard deviation scores (SDS) using data from Japanese infants, published in the national survey for 1990 (Ministry of Health and Welfare, Japan).

Table 1 Characteristics of subjects

Case	Sex	Age at admission	Hospital stay (days)	Weight at birth (g)	Weight at admission (g)	Weight increase during hospital stay (g/day)	Atropine treatment			Ultrasonographic measurement (mm)			
							IV (days)	Oral (days)	Total (days)	Before atropine		After atropine	
										Muscle thickness	Canal length	Muscle thickness	Canal length
Successful cases													
1	F	46	11	2900	4205	21	6	22	28	4	17	3	15
2	M	29	14	3336	3605	25	9	82	91	5	20	3	13
3	M	37	13	3086	4385	27	5	28	33	5	16	3	15
4	M	37	16	3804	4315	16	8	128	136	6	17	4	19
5	F	45	13	3015	4234	17	9	28	37	5	20	3	15
6	M	76	15	3530	5270	4	8	72	80	5	19	3	19
7	M	34	9	3342	3405	44	6	66	72	6	20	3	15
8	M	24	10	2918	3350	9	7	42	49	5	15	4	19
9	M	55	6	3036	3970	66	4	28	32	4	24	2	12
10	M	22	14	3546	3545	6	10	60	70	5	25	5	20
11	M	85	13	3440	5410	11	7	63	70	6	19	3	20
12	M	40	9	2592	3465	16	6	44	50	5	18	3	13
13	F	29	9	3070	3505	13	4	41	45	4	22	3	16
14	M	36	14	2600	3200	24	8	41	49	4	17	2	15
15	M	54	10	4430	5010	10	7	44	51	6	18	4	13
16	M	69	11	3140	5400	28	7	40	47	5	19	3	16
17	M	62	20	2480	3458	24	10	50	60	5	18	4	15
Unsuccessful cases													
18	M	23	28	3190	3325	5	18	-	18	4	15	-	-
19	M	74	19	3154	3765	7	9	-	9	7	20	-	-

Ultrasonographic measurements were made before and three weeks after atropine administration. IV, Intravenous atropine administration.

Ultrasonographic evaluation of the pylorus

Ultrasonographic evaluations were conducted at presentation, at three weeks and six months after completion of oral atropine administration, and at 1 year of age. Ultrasonography was performed by the same paediatric radiologist (MN) using a Yokogawa Medical RT4600 and 7.5 MHz linear probe. The patients were fasted for more than three hours before ultrasonographic examination and were not sedated. The examination was performed on several planes. The thickness of the pyloric muscle and the length of the pyloric canal were measured on transverse views, which showed the pylorus along its long axis. Transpyloric flow of gastric contents was also examined. All patients were followed up until 2 years of age.

Statistical analysis

All data are presented as median (range). Tests for statistically significant differences in weight SDSs and ultrasonographic measurements were analysed using the Kruskal-Wallis test. Categorical variables were compared using the Tukey test.

RESULTS

At the time of presentation, 12 patients had previously received infusions at other hospitals, and dehydration and/or electrolyte imbalance were not noted. Of the 19 patients, 17 became free from projectile vomiting during atropine treatment. The remaining two required surgery after 9 and 18 days of intravenous atropine. Total hospital stay was 13 (6–20) days for the 17 patients. The duration of intravenous and subsequent oral atropine administration was 7 (4–10) days and 44 (22–128) days respectively. Atropine was administered for 50 (28–136) days in total, and was completed at 93 (71–174) days of age.

Of the 17 patients, 13 experienced little vomiting three weeks after completion of oral atropine administration. The remaining four occasionally vomited once or twice a day three weeks after completion of oral atropine, but rarely vomited three and six months after completion.

Weight SDSs showed significant changes during atropine treatment ($p < 0.01$) (fig 1). There was a significant ($p < 0.01$) increase at 6 months of age (-0.3 (-1.7 – $+1.8$)),

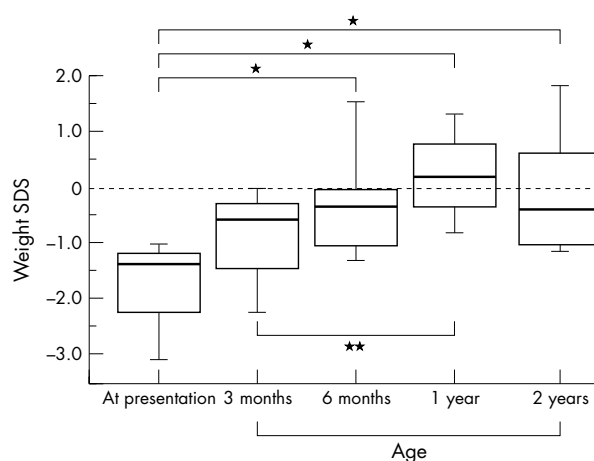


Figure 1 Serial changes in weight standard deviation scores (SDS) in patients successfully treated with atropine. Box, interquartile range; horizontal bar, median; whiskers, 10th and 90th centile. * $p < 0.01$, ** $p < 0.05$.

but not at 3 months (-0.6 (-3.1 – 0)), compared with that at presentation (-1.4 (-4.1 – -0.2)). There was no further significant change at 1 year ($+0.2$ (-1.7 – $+2.1$)) and 2 years of age (-0.4 (-1.2 – $+2.4$)).

Ultrasonography showed significant ($p < 0.01$) changes during atropine treatment. Figure 2 shows serial changes in pyloric muscle thickness and pyloric canal length. Pyloric muscle thickness decreased significantly ($p < 0.05$) from 5 (4–6) mm at presentation to 3 (2–5) mm three weeks after completion of oral atropine. Pyloric canal length was 19 (15–25) mm at presentation and 15 (12–20) mm three weeks after completion of oral atropine (not significant). Transpyloric flow of intragastric fluid was not observed by ultrasound in any patient before treatment, but was detected in all three weeks after completion of oral atropine. Pyloric muscle thickness was 2 (2–4) mm six months after completion of oral atropine and 2 (2–3) mm at 1 year of age, both of which were significantly ($p < 0.01$) less than that at presentation. Pyloric canal length

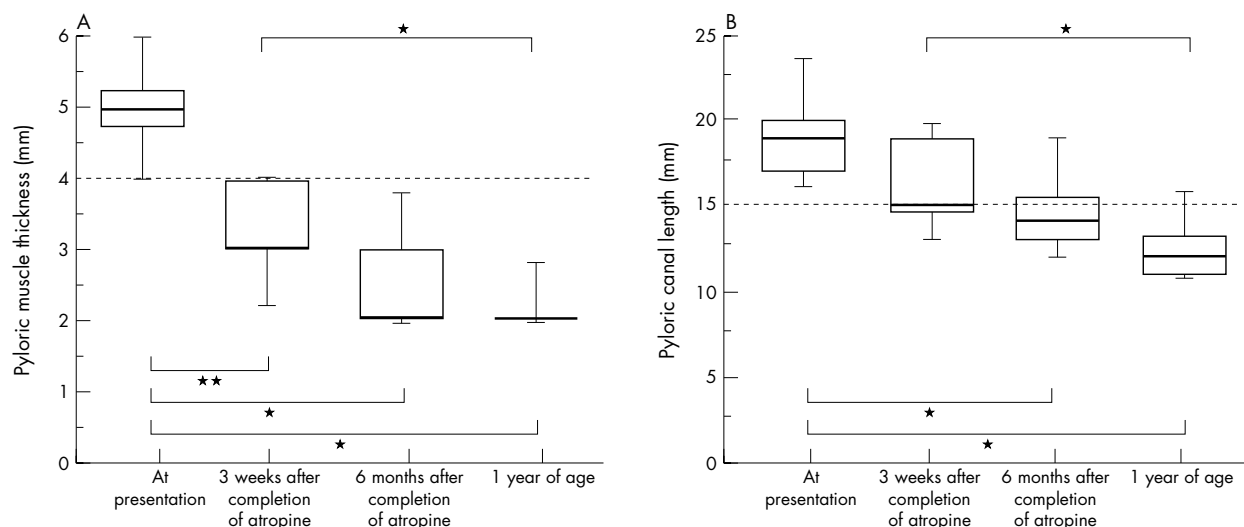


Figure 2 Serial changes in pyloric muscle thickness (A) and pyloric canal length (B) of patients successfully treated with atropine. Box, interquartile range; horizontal bar, median; whiskers, 10th and 90th centile. * $p < 0.01$, ** $p < 0.05$.

was 14 (11–19) mm six months after completion of oral atropine and 12 (9–19) mm at 1 year of age, both of which were significantly ($p < 0.01$) less than that at presentation.

Significant complications were not encountered. One patient had a urinary tract infection and one a transient slight increase in serum aspartate aminotransferase and alanine aminotransferase (< 60 IU/l) during intravenous atropine administration. Facial flushing was not reported during treatment. The resting heart rate remained less than 160 beats/min.

DISCUSSION

Medical treatment with atropine has been reappraised as an option for IHPS treatment, using a step up dosage technique with intravenous atropine administration and was associated with a successful short term outcome.^{8,9} The clusters of tonic and phasic pyloric contractions characteristic of IHPS recently reported are transiently abolished by an intravenous atropine injection of 0.01 mg/kg.¹⁰ We thought that this dose of atropine would improve transpyloric flow by inhibiting the contractions. We therefore used this as a fixed dose before feeds six times a day. This was in contrast with the regimen of Nagita *et al.*,⁸ in which the dose of atropine was increased until projectile vomiting was controlled. In that study, the dose of atropine actually given was 0.07 (0.04–0.11) mg/kg/day, and 12 of 22 patients received a dose greater than that used in our study. The success rate in our regimen (89%) was similar to that reported by Nagita *et al.* (91%). The duration of intravenous atropine administration was slightly longer in our study (7 (4–10) days) than in theirs (5 (1–8) days) ($p < 0.05$; Mann-Whitney U test). No special characteristics were evident in the two patients for whom atropine treatment failed. During subsequent oral atropine treatment, we used double the intravenous dose as described by Nagita *et al.*

During the intravenous administration, heart rate was maintained in a safe range and there were no serious clinical problems. The adverse events in the series of Nagita *et al.*⁸ included mild facial flushing, increased alanine aminotransferase, and tachycardia. No serious complications occurred with intravenous atropine, but it may be both safer and more convenient to use a fixed dose as in our regimen.

In this study, we attempted to reach half the full volume of formula within a week and the full volume within two weeks. Although prolonged intravenous atropine was given for a couple of days at the guardians' request in two patients, they did

not improve and required surgery. In contrast, projectile vomiting was controlled within 10 days in 17 patients.

Long term outcome has not been compared in patients with IHPS treated medically and surgically.¹¹ The patients treated successfully with atropine showed failure to thrive at presentation. They had all recovered when reviewed at 6 months of age. They were all free from symptoms without atropine. All were well at their two year follow up. These findings indicate that atropine treatment is not associated with any significant adverse long term effects.¹¹

Regression of pyloric muscle hypertrophy has been investigated ultrasonographically in patients treated surgically¹² and medically.^{8,9} Sauerbrei and Paloschi¹² reported that pyloric muscle thickness and the diameter and length of the pyloric canal were normal within six weeks of pyloromyotomy. In patients with IHPS treated with atropine, Nagita *et al.*⁸ reported that the time to normalisation of pyloric muscle thickness ranged from four to 12 months. Yamataka *et al.*⁹ reported that the normalisation of pyloric muscle thickness was not significantly different between patients undergoing pyloromyotomy (3.8 (2.0) months) and those treated with atropine (3.4 (2.3) months). The present study indicated that pyloric muscle thickness was significantly less on completion of oral atropine treatment, and preceded normalisation of pyloric canal length.

The value of intravenous atropine as a treatment for IHPS remains controversial.¹³ It has not gained wide acceptance mainly because it requires a prolonged hospital stay and treatment at home. Although pyloromyotomy has been regarded as the optimum treatment of IHPS, the actual and potential consequences of surgery cannot be ignored.^{2,3} The patient has an abdominal scar, and there is a small long term risk of complications due to adhesion. Expert paediatric surgery is not universally available. A randomised controlled trial comparing the outcomes and cost effectiveness of intravenous atropine versus surgery is required.

Authors' affiliations

H Kawahara, K Imura, M Nishikawa, M Yagi, A Kubota, Divisions of Paediatric Surgery and Radiology, Osaka Medical Centre and Research Institute for Maternal and Child Health, Osaka, Japan

REFERENCES

- Benson CD, Lloyd JR. Infantile pyloric stenosis: a review of 1120 cases. *Am J Surg* 1964;**107**:429–33.
- Brain AJL, Roberts DS. Who should treat pyloric stenosis: the general or specialist paediatric surgeon? *J Pediatr Surg* 1996;**31**:1535–7.

- 3 **Hulka F**, Harrison MW, Campbell TJ, *et al*. Complications of pyloromyotomy for infantile hypertrophic pyloric stenosis. *Am J Surg* 1997;**173**:450-2.
- 4 **Corner BD**. Hypertrophic pyloric stenosis in infancy treated with methyl scopolamine nitrate. *Arch Dis Child* 1955;**30**:377-86.
- 5 **Jacoby NM**. Pyloric stenosis: selective medical and surgical treatment: a survey of sixteen years' experience. *Lancet* 1962;i:119-21.
- 6 **Mellin GW**, Santulli TV, Altman HS. Congenital pyloric stenosis: a controlled evaluation of medical treatment utilizing methyl-scopolamine-nitrate. *J Pediatr* 1965;**66**:649-57.
- 7 **Day LR**. Medical management of pyloric stenosis. *JAMA* 1969;**207**:948-50.
- 8 **Nagita A**, Yamaguchi J, Amemoto K, *et al*. Management and ultrasonographic appearance of infantile hypertrophic pyloric stenosis with intravenous atropine sulfate. *J Pediatr Gastroenterol Nutr* 1996;**23**:172-7.
- 9 **Yamatata A**, Tsukada K, Yokoyama-Laws Y, *et al*. Pyloromyotomy versus atropine sulfate for infantile hypertrophic pyloric stenosis. *J Pediatr Surg* 2000;**35**:338-42.
- 10 **Kawahara H**, Imura K, Yagi M, *et al*. Motor abnormality in the gastroduodenal junction in patients with infantile hypertrophic pyloric. *J Pediatr Surg* 2001;**36**:1641-5.
- 11 **Berglund G**, Rabo E. A long-term follow-up investigation of patients with hypertrophic pyloric stenosis, with special reference to the physical and mental development. *Acta Paediatr Scand* 1973;**62**:125-9.
- 12 **Sauerbrei EE**, Paloschi GGB. The ultrasonic features of hypertrophic pyloric stenosis, with emphasis on the postoperative appearance. *Radiology* 1983;**147**:503-6.
- 13 **Rudolph CD**. Medical treatment of idiopathic hypertrophic pyloric stenosis: should we marinate or slice the "olive"? *J Pediatr Gastroenterol Nutr* 1996;**23**:399-401.

Direct Access to Medline

Medline

Link to Medline from the homepage and get straight into the National Library of Medicine's premier bibliographic database. Medline allows you to search across 9 million records of bibliographic citations and author abstracts from approximately 3,900 current biomedical journals.

www.archdischild.com