

Successful conservative treatment of rheumatoid subaxial subluxation resulting in improvement of myelopathy, reduction of subluxation, and stabilisation of the cervical spine. A report of two cases

Johanna C M Oostveen, Martin A F J van de Laar, Jan A G Geelen, Ron de Graaff

Abstract

Objective—To report the efficacy of conservative treatment with cervical traction and immobilisation with a Halo vest, in two consecutive rheumatoid arthritis patients with progressive cervical myelopathy caused by subaxial subluxation.

Methods—Description of neurological symptoms and signs and findings in plain radiography (PR) and magnetic resonance imaging (MRI) of the cervical spine before and after treatment of the subaxial subluxation by traction and immobilisation with a Halo vest during four months.

Results—During four months of traction and immobilisation neurological examination showed a considerable improvement of the signs and symptoms of cervical myelopathy. Afterwards PR and MRI of the cervical spine showed reduction of the subaxial subluxation. Eventually firm stabilisation was obtained in both patients without surgery of the cervical spine.

Conclusion—Cervical traction and immobilisation with a Halo vest can be considered as an independent conservative treatment in rheumatoid arthritis patients with cervical myelopathy caused by subaxial subluxation.

(*Ann Rheum Dis* 1999;58:126-129)

Case reports

CASE ONE

A 69 year old patient was admitted with weakness of the arms and legs, "jumping" of the legs, and urinary incontinence. Her medical history mentioned severe destructive RA of 37 years duration, total knee replacement, one transient ischaemic episode, and mild chronic bronchitis. Over the years, she had been treated with several disease modifying drugs. One year before admission she developed weakness and paresthesia of the left arm without abnormal neurological signs. Plain radiography (PR) and magnetic resonance imaging (MRI) of the cervical spine showed mild anterior and vertical AAS, erosions of the odontoid process, SAS at C4-C5 level (5 mm) and secondary spondylosis. The spinal subarachnoid space was narrowed, but there was no spinal cord compression. She continued to wear a soft cervical collar.

At admission examination showed urinary incontinence, flexor spasms of the legs, quadriplegia (Medical Research Council (MRC) grade 3), loss of sensation to vibration and touch in arms and legs, and bilateral positive Babinsky's sign.⁸ PR and MRI showed SAS at C4-C5 level (9 mm), secondary spondylosis, narrowing of the spinal subarachnoid space and compression of the spinal cord (fig 1A and 1B). A diagnosis of rapidly progressive myelopathy caused by SAS at C4-C5 level was made. The patient was treated with cervical traction using a Halo vest to reduce the SAS and the neurological deficit. Afterwards surgical stabilisation would be performed. During the first weeks of traction the muscle strength of arms and legs improved (MRC grade 4), and the flexor spasms and urinary incontinence disappeared. PR of the cervical spine showed reduction of the SAS. She tolerated the Halo vest treatment well. Four months after admission the surgical procedure was to be performed. Postponement of the surgery was caused by pulmonary infections. After removal of the Halo traction the neurosurgeon found a very stable fixation of the cervical spine during radiographic controlled external palpation of the cervical spine. He cancelled the surgical stabilisation in this frail patient. PR and MRI of the cervical spine showed no SAS at C4-C5 level (fig 2A and 2B). One year after this treatment the clinical condition was unchanged. PR of the cervical spine showed a stable fixation of the cervical spine at the C4-C5 level without SAS. Bony fusion was

Departments of

Rheumatology

J C M Oostveen
M A F J van de Laar

Neurology

J A G Geelen

and Neurosurgery

R de Graaff

Rheumatology Twente,
Medisch Spectrum
Twente, Enschede, the
Netherlands

Correspondence to:
Dr J C M Oostveen,
Rheumatology Twente,
Medisch Spectrum Twente,
Postbus 50.000, 7500KA
Enschede, the Netherlands.

Accepted for publication
2 November 1998

Rheumatoid arthritis (RA) commonly affects the cervical spine. Radiographic abnormalities have been observed with a frequency of 19% to 88%, depending on the patients studied.¹ The most common abnormalities are atlantoaxial subluxations (AAS). Subaxial subluxation (SAS) has been seen in 7% to 29% of RA patients. Only a small minority of these patients will develop signs of cervical myelopathy. Once myelopathy is clinically apparent, 50% of the conservatively treated patients die within six months.² In these cases surgery can be undertaken to stabilise the cervical spine. Preoperative cervical traction is an effective method to reduce subluxation.²⁻⁷ We describe two RA patients and myelopathy caused by SAS, in whom sustained improvement of the neurological signs and cervical stabilisation were achieved by temporary traction and external fixation of the cervical spine with a Halo vest.

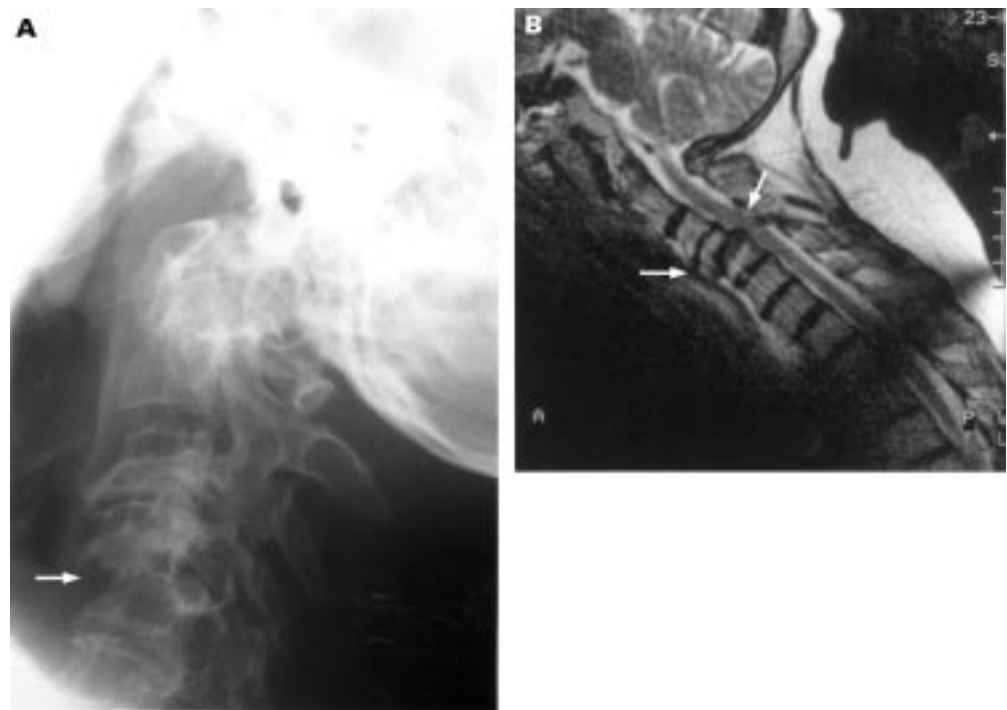


Figure 1 Lateral plain radiograph in flexion (A) and T2 weighted sagittal MR image (B) of the cervical spine showing C4–C5 subluxation of 9 mm with secondary spondylosis, discopathy, narrowing of the spinal subarachnoid space, and compression of the spinal cord.

not yet seen. Sixteen months after treatment she died of cardiac failure.

CASE TWO

A 66 year old patient with severe destructive polyarticular juvenile RA was admitted with weakness of the arms and legs, paresthesia of the arms, and numbness of the legs. Over the years, she had been treated with several disease

modifying drugs and had undergone total joint replacement of both hips and one knee. Four years before admission she experienced transient neck pain and paresthesia of the arms without neurological signs of cervical myelopathy. PR showed SAS at C3–C4 level (4.5 mm) and C4–C5 level (10 mm), and discopathy at C4–C5 level. A few weeks before admission she developed increasing weakness of the arms and

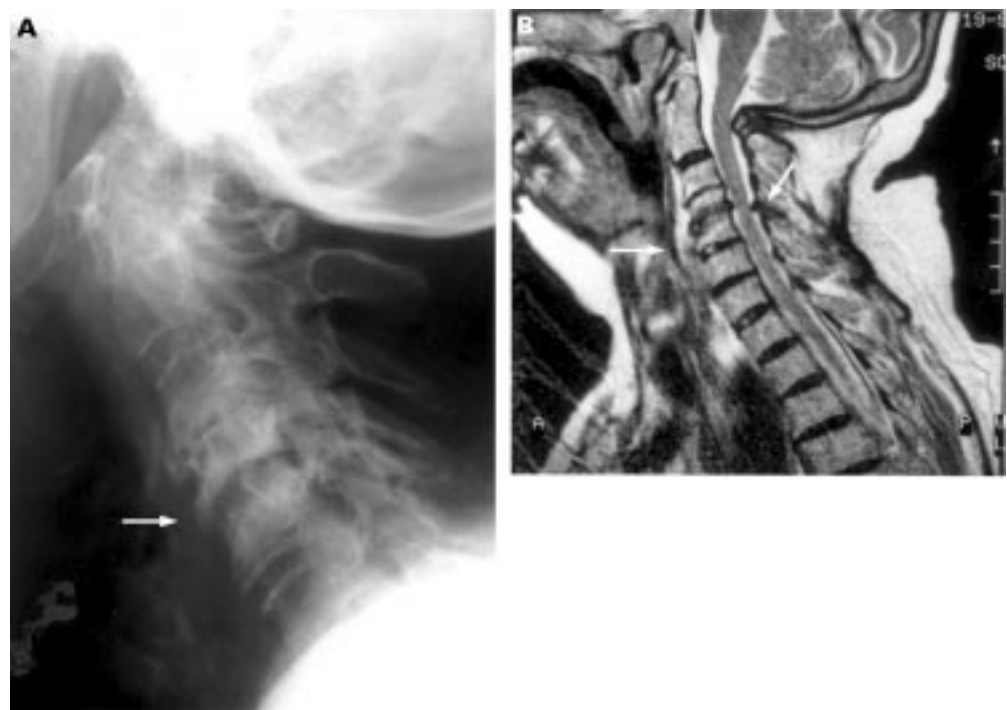


Figure 2 Lateral plain radiography (A) and T2 weighted sagittal MR image (B) of the cervical spine after four months Halo vest traction and immobilisation showing reduction of C4–C5 subluxation, narrowing of the spinal subarachnoid space, and compression of the spinal cord.

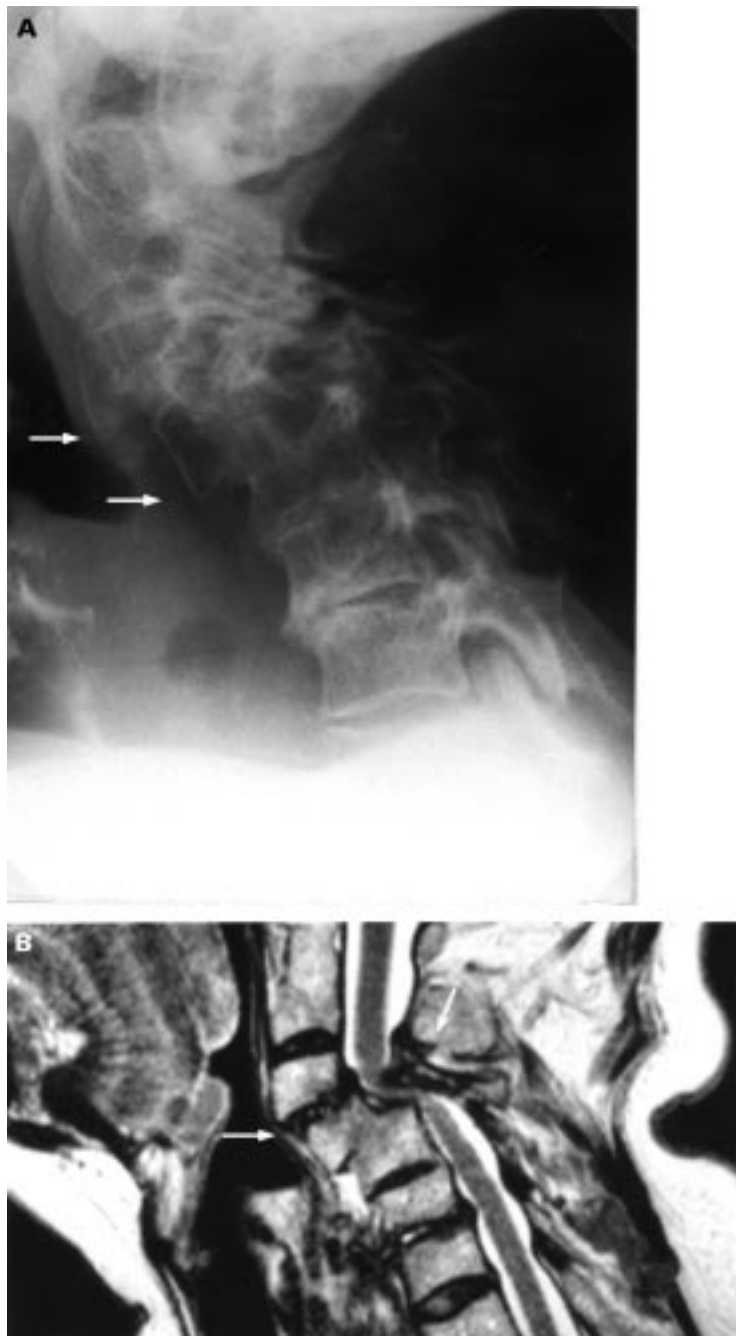


Figure 3 Lateral plain radiography in flexion (A) and T2 weighted sagittal MR image (B) of the cervical spine showing C3–C4 subluxation of 9 mm, stable C4–C5 subluxation of 8 mm with fusion of the vertebral bodies of C4 and C5, narrowing of the spinal subarachnoid space, and compression of the spinal cord.

legs, paresthesia of the arms, and numbness of the arms and legs.

At admission she was not able to walk. Examination showed quadriparesis (MRC grade 3), loss of sensation to vibration and light touch in the arms and legs, and hyper-reflexia. PR and MRI of the cervical spine showed C3–C4 subluxation of 9 mm, stable C4–C5 subluxation of 8 mm with fusion of the vertebral bodies of C4 and C5, narrowing of the spinal subarachnoid space, and compression of the spinal cord (fig 3A and 3B). The MR image suggests presence of some extradural soft tissue at C3–C4 level. A diagnosis of rapidly progressive myelopathy resulting from

C3–C4 subluxation was made. The C4–C5 subluxation was stable and not increased during the past four years. She was treated with cervical traction and immobilisation using a Halo vest to reduce the neurological deficit and the C3–C4 subluxation. During the first weeks of traction the muscle strength of arms and legs improved (MRC grade 4) and the numbness in arms and legs disappeared. PR showed reduction of C3–C4 subluxation (3 mm). Four months after admission the Halo vest was removed. PR and MRI demonstrated stable C3–C4 subluxation (3 mm) and reduction of compression of the spinal cord (fig 4A and 4B). As expected there were no changes at C4–C5 level. Surgical stabilisation was not done because the patient preferred conservative treatment. One year after this treatment the patient had no numbness of arms and legs and was able to walk. PR of the cervical spine showed stable C3–C4 subluxation (3 mm).

Discussion

We described two cases of successful conservative treatment of severe myelopathy resulting from rheumatoid SAS. In the past five years we have not seen other RA patients with severe myelopathy caused by SAS in our department (1997:1900 RA patients).

Conservative management of AAS and SAS subluxations in RA includes all applicable measures in the suppression of active synovitis, the ultimate cause of subluxations. At admission the two patients had no active synovitis of the peripheral joints. Synovitis in the cervical spine may have been reduced by rest because of immobilisation with the HALO vest. Patients with cervical subluxation but without objective or deteriorating neurological signs can be treated with a soft collar, which provides symptomatic relief and may provide some degree of protection from trauma.^{9,10} There are no controlled trials of prophylactic surgery of the cervical spine in RA patients. The radiological progression of cervical spine subluxation in RA patients is unpredictable and there is poor correlation between an increasing AAS or SAS and the development of neurological signs.⁹

In patients with cervical myelopathy, the recommended procedure is cervical traction and surgical stabilisation.^{9,10} In our patients the decision was taken to treat them accordingly. After four months of cervical traction and external fixation with a Halo vest improvement of the neurological deficit, reduction of the SAS, and firm stabilisation of the cervical spine were obtained. Therefore surgical stabilisation was not necessary for these frail patients. The only partial improvement of neural function may be attributable to irreversible spinal cord injury as a result of mechanical or vascular damage.

The results of surgical treatment in non-ambulant myelopathic patients are dismal. Casey *et al* reported that only a quarter of these patients achieved a satisfactory outcome and a quarter died within six months.¹¹ McRorie *et al* reported better results of surgical stabilisation in patients with less neurological deficit.¹² They did not mention differences in patients with AAS, SAS or a combination of these. Peppel-

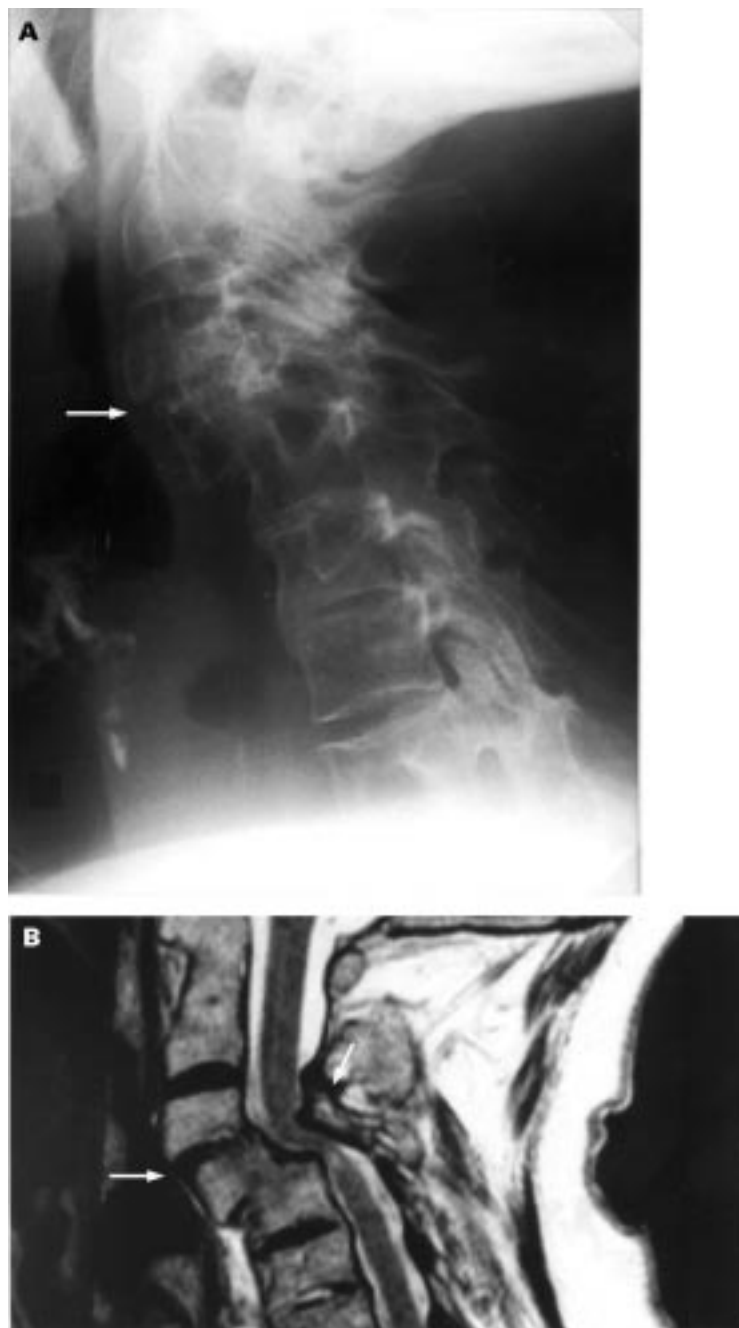


Figure 4 Lateral plain radiography (A) and T2 weighted sagittal MR image (B) of the cervical spine showing reduction and stabilisation of C3–C4 subluxation (3 mm), reduction of compression of the spinal cord, and no changes at C4–C5 level.

man *et al* reported improvement in 14 of 16 patients with neurological deficit resulting from SAS (14 with paresis) after surgical stabilisation.⁷ Santavirta *et al* found improvement of severe paresis in eight of nine patients with SAS.¹³ Olerud *et al* reported that four of five patients with severe myelopathy caused by SAS died within three months after surgery.¹⁴

Temporary cervical traction and immobilisation as only treatment for cervical myelopathy in RA patients is an unusual procedure to achieve amelioration of the neurological deficit and stabilisation of the cervical spine. In former days cervical traction was only possible by immobilising the patient. Nowadays, cervical traction and immobilisation with a Halo

vest allows the patient to continue to be active. Marks *et al* and Meijers *et al* reported some patients with cervical myelopathy treated only by continuous cervical traction.^{2–5} The reasons for this treatment were unfavourable initial response on cervical traction, refusal of a surgical procedure, or a bad physical condition. All these patients died within one year, mostly because of complications of cord compression. They did not mention differences in patients with AAS or SAS. Kornblum *et al* described three patients, in two of whom the subluxation was reduced with cervical traction and held with external support.¹⁵ One of these two suffered from severe progressive SAS. In our patients treatment with temporary cervical traction and external fixation resulted in sustained improvement of neurological deficit. The definite stabilisation of the cervical spine may be merely achieved by the external fixation in the Halo vest.

In RA patients with cervical myelopathy caused by cervical subluxations cervical traction followed by a surgical procedure is still the recommended intervention. It is remarkable in these cases that prolonged cervical traction and external fixation with a Halo vest resulted in a firm stabilisation of the cervical spine. Cervical traction and immobilisation with a Halo vest can be considered as an independent, conservative treatment for SAS, in particular in patients with a high operation risk. This procedure without surgical stabilisation is probably not suitable for treatment of AAS. The anatomy and mechanical forces operating at C1–C2 level are different from those at the lower levels of the cervical spine.

- Halla JT, Hardin JG, Vitec J, Alarcon GS. Involvement of the cervical spine in rheumatoid arthritis. *Arthritis Rheum* 1989;32:652–9.
- Marks JS, Sharp J. Rheumatoid cervical myelopathy. *Q J Med* 1981;50:307–19.
- Ferlic DC, Clayton ML, Leidholt JD, Gamble WE. Surgical treatment of the symptomatic unstable cervical spine in rheumatoid arthritis. *J Bone Joint Surg* 1975;57A:349–54.
- Ranawat CS, O'Leary P, Pellici P, Tsairis P, Marchisello P, Dorr L. Cervical spine fusion in rheumatoid arthritis. *J Bone Joint Surg* 1979;61A:1003–10.
- Meijers KAE, Cats A, Kremer HPH, Luyendijk W, Onvlee GJ, Thomeer RTWM. Cervical myelopathy in rheumatoid arthritis. *Clin Exp Rheumatol* 1984;2:239–45.
- Santavirta S, YT Konttinen, E Laasonen, V Honkanen, I Antti-Poika, M Kauppi. Ten year results of operations for rheumatoid cervical spine disorders. *J Bone Joint Surg* 1991;73B:116–20.
- Peppelman WC, Kraus DR, Donaldson WF, Agarwal A. Cervical spine surgery in rheumatoid arthritis: improvement of neurological deficit after cervical spine fusion. *Spine* 1993;16:2375–9.
- Medical Research Council. *Aids to the examination of the peripheral nervous system. Memorandum 45*. London: Her Majesty's Stationary Office, 1976.
- Bland JH. Rheumatoid subluxation of the cervical spine. *J Rheumatol* 1990;17:134–6.
- Agarwal AK, Peppelman WC, Kraus DR, Eisenbeis CH. The cervical spine in rheumatoid arthritis. *BMJ* 1993;306:79–80.
- Casey ATH, Crockard HA, Bland JM, Stevens J, Moskovich R, Ransford AO. Surgery on the rheumatoid cervical spine for the non-ambulant myelopathic patient - too much, too late? *Lancet* 1996;347:1004–7.
- McRorie ER, McLoughlin P, Russell T, Beggs I, Nuki G, Hurst NP. Cervical spine surgery in patients with rheumatoid arthritis: an appraisal. *Ann Rheum Dis* 1996;55:99–104.
- Santavirta S, Konttinen YT, Sandelin J, Slati P. Operations for the unstable cervical spine in rheumatoid arthritis. Sixteen cases of subaxial subluxation. *Acta Orthop Scand* 1990;61:106–10.
- Olerud C, Larsson BE, Rodriguez M. Subaxial cervical spine subluxation in rheumatoid arthritis. *Acta Orthop Scand* 1997;68:109–15.
- Kornblum K, Clayton ML, Nash HH. Nontraumatic cervical dislocations in rheumatoid spondylitis. *JAMA* 1952;149:431–5.