

LESSON OF THE MONTH

Fatal myocardial necrosis

Margaret-Mary Gordon, Rajan Madhok

Case history

A 36 year old married, non-smoker was referred for further management of a 10 week history of Raynaud's phenomenon affecting the hands and feet beginning in mid-summer. There was an associated history of myalgia, fatigueability and exertional praecordial chest pain radiating into the neck and relieved by rest. Her symptoms had increased such that she was no longer able to work. She had no significant past medical history and was taking no regular medication. There was no family history of note.

On examination, there was proximal muscle tenderness in the limb girdles with reduced power. She was comfortable at rest, normotensive and full cardiorespiratory examination was normal. All peripheral pulses were present and symmetrical and there was no sclerodactyly or nail fold capillary changes. There was no associated rash.

Initial investigations including full blood count, erythrocyte sedimentation rate, renal and hepatic function, chest radiography, and electrocardiography were all normal. Urine analysis was negative. ANF, antiphospholipid antibodies and antibodies to extractable nuclear antigens, including anti-Jo1 were not detected. Creatine kinase was increased at 313 U/l (normal range 10-171). Needle muscle biopsy showed an inflammatory infiltrate with no muscle necrosis. Electronmicrography showed spontaneous fibrillation, consistent with a diagnosis of polymyositis.

Prednisolone 40 mg/day resulted in an improvement in muscle symptoms with a concomitant decrease in creatine kinase to 676 U/l. An exercise tolerance test was limited by fatigue with no associated changes in electrocardiography.

Eighteen days later she was readmitted with increasing anterior chest pain at rest. The pain settled spontaneously on admission and sequential resting electrocardiograms were normal. There was no rise in creatine kinase. On the second day after admission, her chest pain recurred and was relieved by leaning forward. There was a rise in creatine kinase to 756 U/l. Resting electrocardiography remained normal and continuous cardiac monitoring did not show any arrhythmias or repolarisation changes over the next 24 hours. Raynaud's phenomenon was not a feature during admission and her skin remained intact.

Cardiac echo showed moderate reduction in left ventricular function. To assess left ventricu-

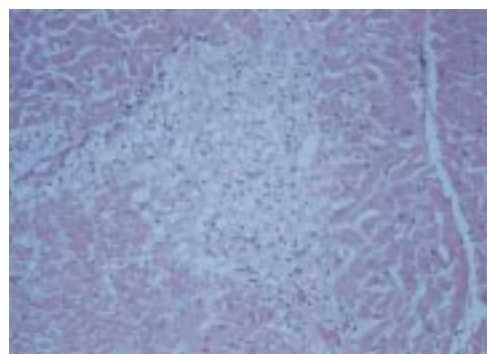


Figure 1 Extensive myocardial necrosis with no inflammatory infiltrate.

lar function more accurately, a thallium scan was performed on the fourth hospital day and was followed by further acute chest pain, requiring diamorphine for pain relief. Creatine kinase rose after this episode to 1132 U/l. Further chest pain 32 hours later was associated with repolarisation changes on electrocardiography and a further rise in creatine kinase including an MB fraction of 11.3%. She was transferred to coronary care with a presumptive diagnosis of an inflammatory myocarditis and treated with a doubling in corticosteroid dose and an intravenous bolus of cyclophosphamide (5 mg/kg). Intravenous nitrates were used as vasodilators, but had to be discontinued because of hypotension. She was then treated with dopamine and dobutamine by continuous infusion.

On the sixth hospital day, a repeat echo showed a dilated poorly contracting ventricle. Coronary angiography showed normal coronary arteries and no evidence of pulmonary hypertension. Myocardial biopsy showed gross myocardial necrosis with no evidence of an inflammatory infiltrate therefore further immunosuppressants or an increased dose of cyclophosphamide were not given. Her condition rapidly deteriorated and despite full pharmacological inotropic support in addition to an intra-aortic balloon pump, she died before a cardiac transplant becoming available.

At postmortem examination, there was extensive myocardial necrosis (fig 1). There was no evidence of coronary artery disease, vasculitis or inflammatory infiltrate. There was no evidence of atheromatous disease or renal involvement. The underlying aetiology was presumed to be widespread intense coronary vasospasm.

Centre for Rheumatic Diseases, Glasgow Royal Infirmary, 84 Castle Street, Glasgow G4 OSF

Correspondence to: Dr M-M Gordon.

Accepted for publication 11 December 1998

Discussion

The cardiac involvement in our patient was severe and attributed to extensive coronary artery vasospasm. Polymyositis was diagnosed using accepted criteria on the basis of symmetrical limb girdle weakness, increase in muscle enzyme activities, and characteristic electromicrographic findings.^{1,2} The initial history suggested myocardial ischaemia but was not confirmed on investigation. Myocardial biopsy and subsequent postmortem examination did not show an inflammatory infiltrate. The extent and severity of myocardial necrosis could be a result of widespread coronary artery vasospasm, a manifestation of a more generalised vasospastic disorder also resulting in Raynaud's phenomenon.

Raynaud's phenomenon occurs in up to 30% of patients with polymyositis and often antedates the diagnosis.³ In patients with connective tissue disorders, it is one manifestation of a more generalised vasospastic disorder that may also result in variant angina, migraine or pulmonary hypertension.⁴ In systemic sclerosis, patchy myocardial ischaemia responsive to nifedipine has been reported. This is probably attributable to vasospasm of the smaller epicardial vessels rather than the main coronary arteries.⁵ There is also suggestive evidence in primary Raynaud's that the digital vasospasm is but one feature of a more generalised disorder as in one cross sectional study of women with Raynaud's there was a higher than expected incidence of anterior chest pain.⁶

A Medline search using the keywords polymyositis, cardiac vasospasm, and myocardial necrosis revealed no similar reports in the context of connective tissue diseases. Histologically similar extensive myocardial necrosis has been reported with cocaine ingestion caused by coronary vasospasm⁷; there was no

such history in our patient, a finding confirmed by questioning both her relatives and colleagues at work.

Cardiac involvement in polymyositis is recognised but the incidence is not known, probably because of its diversity.⁸⁻¹⁰ It is usually manifest late in the course of the disease and reported features include arrhythmias, including heart block, congestive cardiac failure, prolapsed mitral valve, and pericardial disease. Coronary vasculitis and obstructive atheromatous lesions also occur; in our patient these features were absent.

Lesson

- Raynaud's phenomenon in the context of connective tissue disorders is a generalised vascular disorder.
- It may result in coronary vasospasm.
- Early use of vasodilators such as prostacyclin in those with chest pain may be indicated and may have changed the outcome in our patient.

- 1 Bohan A, Peter JB. Polymyositis and dermatomyositis (first of two parts). *N Engl J Med* 1975;292:344-7.
- 2 Bohan A, Peter JB. Polymyositis and dermatomyositis (second of two parts). *N Engl J Med* 1975;292:403-7.
- 3 Byron MA. *Oxford textbook of medicine*. 2nd ed. Oxford: Oxford Medical Publication, 1986:16.49.
- 4 Wigley FM. Raynaud's phenomenon. *Current Opin Rheumatol* 1993;5:773-84.
- 5 Gustafsson R, Mannting F, Kazzam E, Waldenstrom A, Hallgren R. Cold induced reversible myocardial ischaemia in systemic sclerosis. *Lancet* 1989;ii:475-9.
- 6 Leppert J, Aberg H, Rineqvist I, Sorensson S. Raynaud's phenomenon in a female Population: prevalence and association with other conditions. *Angiology* 1987;38:871-7.
- 7 Kloner RA, Hale S, Alker K, Rezkalla S. The effects of acute and chronic cocaine use on the heart. *Circulation* 1992;85:407-19.
- 8 Walton JN, Adams RD. *Polymyositis*. London: E and S Livingstone, 1958:157.
- 9 Oka M, Raasakka T. Cardiac involvement in polymyositis. *Scand J Rheumatol* 1978;7:202-8.
- 10 Makino M, Oono M, Oosugi S, Kamiya H, Nakamura E, Morimoto S. Two cases of polymyositis with cardiac involvement. *J Cardiol* 1994;24:327-34.