

Synovial membrane p53 protein immunoreactivity in rheumatoid arthritis patients

C Soon Lee, Ian Portek, John Edmonds, Bruce Kirkham

Abstract

Objectives—To examine the expression of the p53 protein in synovial membrane of rheumatoid arthritis (RA) patients and to compare this with the expression in normal synovial tissues in subjects without RA.

Methods—Immunohistological expression of the p53 protein was studied using a streptavidin-biotin-peroxidase method and the monoclonal antibody DO-7, an antibody directed against both wild and mutant forms of p53 protein, in synovial tissues of RA patients (n=10) and from subjects with no known joint disease (n=4).

Results—p53 protein expression was present in a small percentage of synovial cells in the majority of the RA patients (n=8; 80%) and in half of the normal control cases with no inflammatory joint disease (n=2; 50%). No sample had more than 5% cells staining with intranuclear pattern. The difference in synovial p53 immunoreactivity between the RA patients and normal controls is not statistically significant ($p=0.64$; χ^2 contingency test).

Conclusions—This study has shown that p53 protein is only weakly expressed in the rheumatoid synovial membrane, with a low percentage of p53 protein immunostaining cells present, with intranuclear staining. These results suggest this is wild type p53 protein rather than mutant protein. These findings suggest that synovial p53 protein expression may not be important in the pathogenesis of RA and may only represent a reactive repair process to DNA damage secondary to the immune and inflammatory reactions associated with the disease.

(*Ann Rheum Dis* 2000;59:143-145)

Department of
Rheumatology, St
George Hospital,
University of New
South Wales, Australia
I Portek
J Edmonds
B Kirkham

Department of
Anatomical Pathology,
Royal Prince Alfred
Hospital, University of
Sydney, NSW,
Australia
C Soon Lee

Correspondence to:
Dr Kirkham and
A/Professor Soon Lee,
Department of
Rheumatology, St George
Hospital, Gray Street,
Kogarah, New South Wales,
Australia 2217

Accepted for publication
2 November 1999

chemically detectable p53 protein can also represent overexpression of the wild type protein in response to DNA damage.⁶ High levels of p53 staining have been reported in the synovial membrane (SM) of patients with longstanding rheumatoid arthritis (RA).⁷ Subsequent studies showed p53 gene mutations in these tissues, suggesting an explanation for changes in SM fibroblast activity and the destructive properties of pannus.⁸ If these findings are supported, they have important implications for our understanding of the pathogenesis of RA, and the development of new therapeutic strategies. However, high p53 expression was not detected in two other studies.^{9,10} To resolve these discrepant findings, we investigated p53 expression in SM biopsy specimens from RA and normal subjects.

Methods

PATIENTS AND TISSUE SAMPLES

This study was approved by the St George Hospital Ethics Committee, and the subjects gave informed consent. Synovial tissue was obtained from 10 patients with RA and four subjects without inflammatory joint disease, at knee arthroscopy. Synovial membrane biopsy specimens were obtained from the suprapatellar pouch, medial and lateral gutters and cartilage/pannus junction sites.

IMMUNOHISTOCHEMISTRY

The synovial samples were formalin fixed and paraffin wax embedded using standard routine methods. Immunohistochemistry was performed on 4 μ m sections, mounted on 5-aminopropyltriethoxysilane coated slides and dried overnight. The sections were dewaxed in xylene and were treated with microwave heating at 60°C for 20 minutes in citrate buffer (2.1 g/1000 ml; pH 6.0) for antigen retrieval. Two adjacent sections were used for immunostaining and negative control respectively. After blocking endogenous peroxidase, washing in phosphate buffered saline (PBS), and blocking of non-specific binding of secondary antibody with normal swine serum, routine streptavidin-biotin-peroxidase immunostaining with diaminobenzidine was applied to the sections incubated overnight with the monoclonal antibody, DO7 (Novocastra; 1:100 dilution). Primary antibody was substituted with PBS in negative control sections. Sections were counterstained with Harris haematoxylin. Tissues from rectal, breast, gall bladder and pancreatic adenocarcinomas known to be immunoreactive for p53 protein were used as positive controls.

Immunoreactivity was evaluated using a previously described method.⁹ All the surface area

The 53 kDa nuclear phosphoprotein encoded by the p53 gene, located on human chromosome 17p13.1,¹ is important in the control of the cell cycle. Wild type p53 protein inhibits cell proliferation and transformation.² Mutation in the p53 gene produces an abnormal protein, with loss of regulation of the cell cycle leading to cell proliferation and in some situations, neoplastic tissue growth.²

Immunohistochemistry can demonstrate p53 protein overexpression in formalin fixed, paraffin wax processed tissue sections of tumours.^{3,4} Mutant p53 protein has a greatly extended half life compared with normal wild type p53 and is more easily detected by immunohistochemical methods.⁵ Immunohisto-

Table 1 Clinical details and p53 immunostaining scores of subjects with rheumatoid arthritis

Subject	Sex/age	DD (y)	Drugs	ESR/CRP	RF	SJC	EMS (min)	Maximum p53 score
1	F 75	6	PRED MTX	30/-	120	5	0	1
2	F 49	5	NIL	32/-	256	2	15	1
3	F 18	2.5	MTX PRED	30/24	NEG	14	30	1
4	M 46	6	NSAID GOLD MTX PRED NSAID	27/<5	120	17	0	1
5	F 29	0.5	NIL	50/-	118	26	60	1
6	F 25	13	SZ NSAID	15/-	NEG	6	30	0
7	F 74	8	SZ PRED	84/106	498	8	0	2
8	F 54	2.5	NSAID	90/90	NEG	23	300	1
9	M 83	6	MTX PRED	33/5	NEG	8	15	1
10	M 43	2	GOLD	4/<5	NEG	8	15	0

DD = duration of disease; PRED = oral prednisolone; MTX = methotrexate; GOLD = IM sodium aurothiomalate; SZ = sulfasalazine; SJC = swollen joint count; EMS = early morning stiffness.

of each tissue section was assessed and an average score calculated for each patient. For each subject two to six samples were available for examination, giving a total of 41 samples from 10 RA patients and 14 samples from the four subjects with no inflammatory joint disease. Immunostaining was assigned a score of 0–4+ : 0 = no staining; 1+ = intranuclear staining of <1% of cells; 2+ = 1–5% cells staining; 3+ = 5–20% cells staining; 4+ = >20% cells staining.

STATISTICAL ANALYSIS

Categorical variables were analysed with the χ^2 contingency test. Only p values of less than 0.05 were considered significant.

Results

SUBJECT DETAILS

The 10 patients with RA varied in both disease duration and current treatments (table 1). Six patients had active RA, with at least two of these features: swollen joint count > 5 ; ESR > 28 or CRP > 8; early morning stiffness > 45 minutes. The four normal subjects with non-inflammatory synovium had arthroscopies for investigation of knee pain of less than six months duration. Two had no discernible cause found, and two had meniscal tears.

p53 EXPRESSION

Expression of the p53 protein was seen as nuclear immunostaining of cells scattered through the sub-synovial lining layer. Eight of the 10 RA patients (80%) had definite immunostaining (fig 1; table 1). Of the 41 samples from the 10 patients examined, most (28 of 41; 68%) showed staining for p53 protein, with similar expression at the different biopsy sites. However, staining was infrequent, with no subject showing more than 5% cells staining. p53 staining did not correlate with disease activity or duration.

In two subjects with no inflammatory joint disease (50%), p53 immunoactivity was also seen in a minority of samples (3 of 11; 27%) (fig 2), with less than 5% of cells staining in each sample. The difference in synovial p53

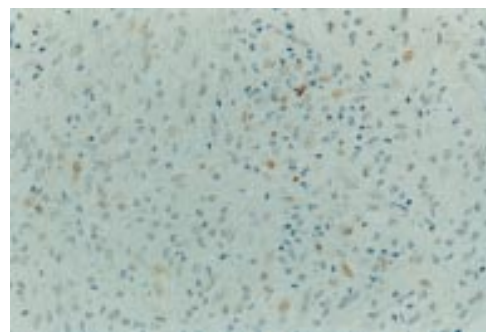


Figure 1 p53 protein nuclear immunostaining present in a small number of synovial cells in a case of clinically active rheumatoid arthritis. (Immunoperoxidase, DO-7; original magnification $\times 200$).

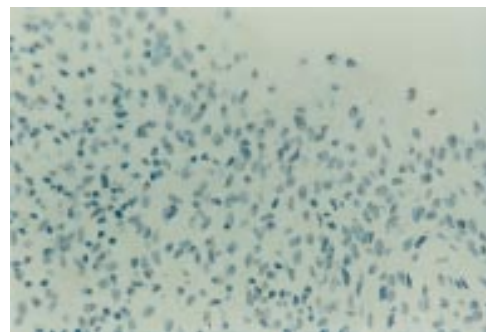


Figure 2 Absence of p53 protein immunostaining in the normal synovium of a subject with no inflammatory joint disease. (Immunoperoxidase, DO-7; original magnification $\times 200$).

immunoreactivity between the RA patients and normal controls is not statistically significant ($p = 0.64$; χ^2 contingency test).

Discussion

Studies of p53 expression in the RA synovium have been stimulated by the hypothesis that cellular accumulation occurs because of defective apoptosis. Abnormal function of a tumour suppressor, such as p53 could contribute to defective apoptosis and also to the transformed appearance of RA synovial fibroblasts.^{7,8} Initial reports of p53 protein expression demonstrated both high⁷ and low or absent levels.^{9,10} Tak *et al* has reported p53 expression in both early (< 6 months) and longer duration (> 5 years) RA.¹¹ That study used a highly sensitive technique on frozen sections and detected 6–15% cells positive in the diffuse sublining leucocyte infiltrate, with less than 5% in the lining layer and lymphocyte aggregates.¹¹ This differs from previous reports from that group of high levels in the intimal lining layer,⁷ and may be accounted for by different antibodies and staining techniques. However, a feature of both these reports is strong cytoplasmic staining.^{7,11} In contrast our results showed low level staining (usually less than 1% of cells) with exclusively intranuclear staining. Cytoplasmic staining for p53 is rare in tumour pathology. It has been reported in an unusually aggressive breast carcinoma using frozen section techniques and was shown to be a truncated form of the p53 protein, because of a non-sense mutation in exon 6.¹²

We used the DO7 monoclonal antibody, regarded by tumour pathologists as the most consistent antibody for paraffin wax sections. This antibody was used by Tak *et al* for western blot analysis.¹¹ The DO1 and Pab 1801 antibodies have previously been shown to give no staining in RA synovium.¹⁰ In fact p53 staining varies widely depending on the antibody used.¹³ Studies of this variability have shown that staining with the Pab 1801 antibody was not repeatable even using a different batch of the antibody from the same manufacturer. In that report staining with the DO1 antibody was negative and caution about overinterpretation of p53 immunostaining was called for, particularly if unusual patterns such as cytoplasmic staining were seen.¹³ More recently a detailed investigation of p53 gene mutations failed to detect any mutations in synovial fibroblasts from European RA patients, but did detect mutations in synovial fibroblasts from three Californian patients.¹⁴

Our results also show that p53 immunostaining is detectable in RA synovium with a frequency of positive cells generally higher than control tissue. The lack of statistical significance may relate to the small numbers of control tissue samples and this may be a biologically important increase in RA. Low p53 expression in various human cancers is strongly associated with wild type, rather than mutant p53 protein.¹⁵ We believe the low level of p53 expression in the RA synovium represents a reactive process to DNA damage secondary to the immune and inflammatory mediators of the disease. We are unable to explain the Californian patients cytoplasmic staining of p53 and suggest it may relate more to the immunostaining techniques and monoclonal antibodies used. Our suggestion that p53 staining is not related to mutations is supported by the recent findings that mutation of the p53 gene was not found in European patients with RA.¹⁴ Whether p53 plays a patho-

logical part in RA, generating severe disease for example, will need to be investigated in a longitudinal outcome study.

Funding: this project is partly supported by a grant from the Rebecca L Cooper Research Foundation, and the National Health and Medical Research Council of Australia.

- 1 Miller C, Mohandas T, Wolf D, Prokocimer M, Rotter V, Koeffler HP. Human p53 gene localized to short arm of chromosome 17. *Nature* 1983;19:783-4.
- 2 Nigro JM, Baker SJ, Preisinger AC, Jessup JM, Hostetter R, Cleary K, *et al*. Mutations in the p53 gene occur in diverse human tumor types. *Nature* 1989;342:705-8.
- 3 Lane DP, Benichou S. p53: oncogene or anti-oncogene? *Genes Dev* 1990;4:1-8.
- 4 Porter PL, Gown AM, Kramp SG, Coltrera MD. Widespread p53 overexpression in human malignant tumors. An immunohistochemical study using methacarn-fixed, embedded tissue. *Am J Pathol* 1992;140:145-53.
- 5 Bartek J, Iggo R, Gannon J, Lane DP. Genetic and immunocytochemical analysis of mutant p53 in human breast cancer cell lines. *Oncogene* 1990;5:893-9.
- 6 Kastan MB, Onyekwere O, Sidransky D, Vogelstein B, Craig RW. Participation of p53 protein in the cellular response to DNA damage. *Cancer Res* 1991;51:6304-11.
- 7 Firestein GS, Nguyen K, Aupperle K, Lwin A, Yeo M, Boyle DL, *et al*. Apoptosis in rheumatoid arthritis: p53 overexpression in rheumatoid arthritis synovium. *Am J Pathol* 1996;149:2143-51.
- 8 Firestein GS, Echeverri F, Yeo M, Zvaifler NJ, Green DR. Somatic mutations in the p53 tumor suppressor gene in rheumatoid arthritis synovium. *Proc Natl Acad Sci* 1997;94:10895-900.
- 9 Sugiyama M, Tsukazaki T, Yonekura A, Matsuzaki S, Yamashita S, Iwasaki K. Localisation of apoptosis and expression of apoptosis related proteins in the synovium of patients with rheumatoid arthritis. *Ann Rheum Dis* 1996;55:442-9.
- 10 McGonagle D, Reece RJ, Green MJ, Blythe D, Veale DJ, Jack AS, *et al*. No p53 expression in rheumatoid arthritis synovium in early and late disease. *Br J Rheumatol* 1997;36 (suppl 1):92.
- 11 Tak PP, Smeets TJM, Boyle DL, Kraan MC, Shi Y, Zhuang S, *et al*. P53 overexpression in synovial tissue from patients with early and longstanding rheumatoid arthritis compared with patients with reactive arthritis and osteoarthritis. *Arthritis Rheum* 1999;42:948-53.
- 12 Johnson RC, Pedersen CA, Cartun RW, Moore RE, Ricci A, Tsongalis GJ. Characterization of an immunohistochemically localized truncated p53 protein by molecular analysis. *Cell Vision* 1995;2:338-42.
- 13 Nickels A, Selter H, Pfreundschuh M, Montenarh M, Koch B. Detection of p53 in inflammatory tissue and lymphocytes using immunohistology and flow cytometry: a critical comment. *J Clin Pathol* 1997;50:654-60.
- 14 Kullmann F, Judex M, Neudecker I, Lechner S, Jüsten H-P, Green DR, *et al*. Analysis of the p53 tumour suppressor gene in rheumatoid arthritis synovial fibroblasts. *Arthritis Rheum* 1999;42:1594-600.
- 15 Baas IO, Mulder JWR, Offerhaus GJA, Vogelstein B, Hamilton SR. An evaluation of six antibodies for immunohistochemistry of mutant p53 gene product in archival colorectal neoplasms. *J Pathol* 1994;172:5-12.