

Prolonged prodrome, systemic vasculitis, and deafness in Cogan's syndrome

S Van Doornum, G McColl, M Walter, I Jennens, P Bhatthal, I P Wicks

Abstract

Cogan's syndrome is a rare, multisystem disease which occurs predominantly in children and young adults. It was originally described as the combination of interstitial keratitis and audiovestibular disturbance, but other forms of ocular disease, as well as systemic vasculitis, have since been recognised as part of the syndrome. Diagnosis can be difficult if the various manifestations occur separately, but early recognition is important because prompt treatment may prevent deafness. Two cases are presented here illustrating the features of this disease, and providing histological evidence of systemic vasculitis in both.

(*Ann Rheum Dis* 2001;60:69-71)

In 1945 Cogan described a syndrome of interstitial keratitis and audiovestibular dysfunction in young adults.¹ The potential for systemic features including vasculitis to occur as part of this syndrome was highlighted by Cody and Williams in 1960.² Although uncommon, it is important to recognise Cogan's syndrome quickly and attempt to prevent deafness. Corticosteroids are the mainstay of treatment; however, further immunosuppressive treatment may be required for associated vasculitis.

Case reports

CASE 1

A 30 year old man presented with progressive, bilateral hearing loss of three weeks' duration associated with tinnitus, vertigo, and ataxia. He had been intermittently unwell for two years with episodic fever and pleuritic chest pain. For four months before presentation he had arthralgia and myalgia, sweats, fatigue, hair fall, nausea, abdominal pain, anorexia, and weight loss. Three days before admission he developed red painful eyes, testicular pain, and several painful lumps on his forearms.

Examination showed several tender subcutaneous nodules on both forearms, splenomegaly, and a tender right testis. Ophthalmic examination showed bilateral conjunctivitis and iritis.

The erythrocyte sedimentation rate (ESR) was 35 mm/1st h (normal <10) and C reactive protein (CRP) was 185 mg/l (normal 0-8). Peripheral blood count, electrolytes, renal function, urine analysis, muscle enzymes, immunoglobulins, serum angiotensin converting enzyme (ACE), antineutrophil cytoplasmic antibodies (ANCA), antinuclear antibodies (ANA), rheumatoid factor, and complement were normal. Liver function was mildly abnor-

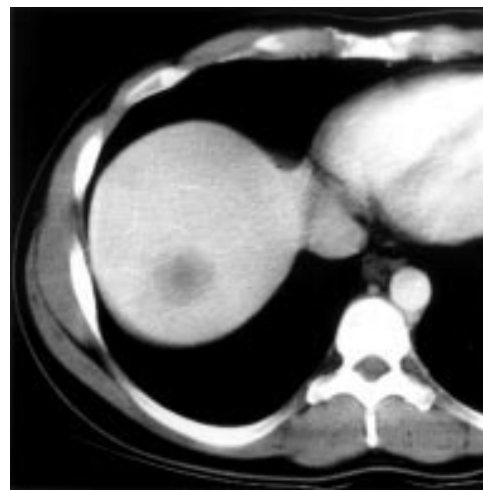


Figure 1 Computed tomography of the abdomen of patient 1: 4 cm hypodense lesion in the liver.

mal (alkaline phosphatase 127 IU/l (normal <120); alanine transaminase 72 IU/l (normal <55); γ -glutamyltransferase 91 IU/l (normal <50)). Serology for viral hepatitis, HIV, *Chlamydia* species, syphilis, and rickettsial disease was negative. Audiometry showed bilateral moderate to severe sensorineural hearing loss. Magnetic resonance imaging of the brain and inner ear was normal. Lumbar puncture showed three polymorphs, 13 lymphocytes, and a protein level of 0.52 g/l (normal 0.15-0.45). Plain radiography and computed tomography (CT) of the chest were normal. Abdominal CT showed multiple, low density lesions within an enlarged spleen, a 4 cm diameter low density lesion in the liver, and slightly enlarged retroperitoneal lymph nodes (fig 1). Bone marrow examination and angiography of the hepatic, splenic, and mesenteric arteries were normal. Transcutaneous biopsy of the liver lesion showed arteritis, a mixed chronic inflammatory cell infiltrate with abundant eosinophils, and a portal tract granuloma (fig 2A). Biopsy of a skin nodule showed an arteritis affecting small muscular arteries (fig 2B).

A provisional diagnosis of Cogan's syndrome was made and intravenous corticosteroids (methylprednisolone 1 g daily for three days) were given. Repeat audiometry a week later showed a clinically significant 10 decibel improvement in the right ear and a 15 decibel improvement in the left. Intravenous (one pulse), then oral cyclophosphamide was started for persistent systemic symptoms. After three months' treatment with oral cyclophosphamide (150 mg daily) and prednisolone (60 mg daily), his systemic symptoms slowly

**Rheumatology Unit,
The Royal Melbourne
Hospital, Parkville VIC
3050, Australia**
S Van Doornum
G McColl
I P Wicks

**Department of
Nephrology, The Royal
Melbourne Hospital**
M Walter

**Victorian Infectious
Diseases Service, The
Royal Melbourne
Hospital**
I Jennens

**Department of
Anatomical Pathology,
The Royal Melbourne
Hospital**
P Bhatthal

Correspondence to:
Professor Ian Wicks,
Department of
Rheumatology, Ground
Floor, West Wing, Charles
Connibere Building, The
Royal Melbourne Hospital,
Parkville VIC 3050, Australia
wicks@wehi.edu.au

Accepted for publication
27 April 2000

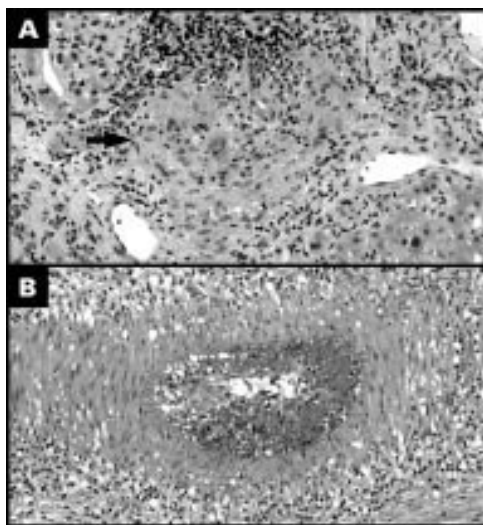


Figure 2 (A) Liver biopsy patient 1. Portal tract granuloma (arrow) and inflammatory cell infiltrate. (Haematoxylin and eosin stain, original magnification $\times 400$.) (B) Skin biopsy patient 1. Occluded artery in subcutaneous fat with adventitial inflammation. (Haematoxylin and eosin stain, original magnification $\times 400$.)

improved. He can hear conversational speech with the assistance of a hearing aid.

CASE 2

A 36 year old man presented with recurrent fevers associated with night sweats, headaches, lethargy, weight loss, and a transient nodular erythematous rash on the trunk and legs. Physical examination was normal.

Investigations showed a mild anaemia (haemoglobin 127 g/l (normal 130–180)) and thrombocytopenia (platelets $146 \times 10^9/l$ (normal 150–400)), ESR of 114 mm/1st h, CRP of 170 mg/l, and serum ferritin of 4664 $\mu\text{g/l}$ (normal 20–400). Renal function, urine analysis, muscle enzymes, thyroid function, rheumatoid factor, ANA, ANCA, complement, serum ACE, and bone marrow biopsy were normal. Liver function was moderately abnormal (albumin 30 g/l (normal 35–50); aspartate transaminase 252 IU/l (normal <43); alanine transaminase 399 IU/l (normal <55); γ -glutamyltransferase 254 IU/l (normal <50)). CT scan of the chest and abdomen showed mild splenomegaly, and liver biopsy showed only fatty change. Echocardiography was normal and blood cultures were negative. Extensive serological testing for bacterial, viral, rickettsial, protozoal, and tuberculous disease was negative.

Prednisolone 100 mg daily was started, with marked clinical response and normalisation of serum inflammatory markers. Reduction of the corticosteroids over the next six months was limited by flares of disease at prednisolone doses of less than 25 mg/day. The introduction of weekly methotrexate allowed the prednisolone to be weaned to 5 mg daily. Six months later he developed left eye iritis, which responded to topical corticosteroid drops, but became a recurrent problem. One and a half years later he re-presented with recurrent fevers, arthralgia, and red nodules on his legs.

He also noted tinnitus and bilateral hearing loss of two weeks' duration. A CT scan of the brain was normal, but audiometric testing showed bilateral moderate to severe sensorineural hearing loss. Despite increasing the prednisolone dose to 50 mg daily (IV methylprednisolone was not used at the discretion of the treating doctor) the hearing did not improve. However, repeated audiometry over the following two weeks showed no further deterioration. Biopsy of a skin nodule showed vasculitis affecting arteries, veins, and capillaries. Based on the clinical constellation of iritis, sensorineural hearing loss, and evidence of systemic vasculitis, a diagnosis of Cogan's syndrome was made.

Discussion

Cogan's syndrome describes the association of audiovestibular dysfunction and inflammatory eye disease with or without systemic features, including vasculitis.^{1,2} The audiovestibular disturbance in Cogan's syndrome produces a Ménière's-like illness and progressive sensorineural hearing loss, which results in profound, irreversible deafness in 50–85% of patients.^{3–6} Cogan's syndrome has been divided into typical and atypical forms based on the ocular findings, with typical Cogan's syndrome defined by interstitial keratitis, and atypical Cogan's syndrome by other forms of ocular disease, including iritis, conjunctivitis, episcleritis, anterior or posterior scleritis, or retinal vasculitis.^{3,4} However, this distinction has been questioned recently as it provides little prognostic information.⁶ In most cases the eye and ear manifestations occur within a few weeks to months of each other (as seen in patient 1), but may occur up to nine years apart.^{3,5}

The pathogenesis of Cogan's syndrome is unknown. Infectious causes have been suggested, including *Chlamydia* and *Borrelia* species, but not proved. There was no evidence for infection with these or other organisms in our patients. Reports of pathological examination of ocular and inner ear tissue have shown lymphocyte and plasma cell infiltration of the cornea and cochlea.^{4,5} The presence of serum antibodies apparently recognising corneal and inner ear antigens has been shown in a few cases,^{6,7} but the significance of this is not yet clear.

Systemic disease occurs in approximately 50% of patients with Cogan's syndrome.^{2,5} Non-specific symptoms such as fever, weight loss, fatigue, headache, arthralgia, myalgia, and abdominal pain are most common.^{4,5} Other manifestations include testicular pain, pleuritis, diarrhoea, cutaneous nodules, lymphadenopathy, splenomegaly, hepatomegaly, and central and peripheral nervous system abnormalities.⁵ Vasculitis has been reported, though there are relatively few reports with histological confirmation.^{4–6,8} Although usually a large and/or medium vessel vasculitis, any sized vessel may be affected.^{5,6,9,10} In our two cases the histological appearances and the normal mesenteric angiogram (patient 1) support a diagnosis of small vessel vasculitis.

There is no confirmatory test for Cogan's syndrome and diagnostic criteria have not been developed. The differential diagnosis includes infection (for example, syphilis, *Chlamydia* species, viral infection, and Lyme disease), sarcoidosis, and coincident unrelated eye and ear disease.⁴⁻⁵ Diseases such as polyarteritis nodosa, Wegener's granulomatosis, rheumatoid arthritis, giant cell arteritis, and relapsing polychondritis may be complicated by inflammatory eye disease and, less commonly, sensorineural hearing loss.¹¹ The diagnosis of Cogan's syndrome in our two patients was based on the combination of inflammatory eye disease and sensorineural hearing loss in the presence of systemic symptoms and histologically proved vasculitis. Our cases did not fulfil diagnostic criteria for any of the primary systemic vasculitides and may help to distinguish Cogan's syndrome from unclassified systemic vasculitis.

The ocular inflammation in Cogan's syndrome generally responds to topical corticosteroids.⁵ Systemic steroids are given for progressive hearing loss or systemic manifestations of Cogan's syndrome. Administration of high dose corticosteroids within two weeks of the onset of hearing loss is reported to give the best outcome.^{4-9,12} In case 1 our patient's hearing improved significantly after treatment with intravenous methylprednisolone despite a three week history of hearing loss. In contrast, his constitutional symptoms only slowly improved with intensive treatment, consistent with a systemic vasculitis. In case 2 the hearing loss of two weeks' duration occurred despite methotrexate and low dose prednisolone, but there was no further deterioration once the dose of steroids was increased.

These cases highlight several important features of Cogan's syndrome. There may be con-

siderable diagnostic difficulty when there is a long prodrome of systemic illness before the development of hearing loss and eye symptoms. The partial reversal of hearing loss in case 1, and stabilisation of hearing in case 2, show the value of high dose steroids for this complication of Cogan's syndrome. Immunosuppressive agents, such as cyclophosphamide and methotrexate, may be required to control the systemic manifestations of the disease.¹²⁻¹³

- 1 Cogan DG. Syndrome of non-syphilitic interstitial keratitis and vestibulo-auditory symptoms. *Arch Ophthalmol* 1945;33:144.
- 2 Cody DTR, Williams HL. Cogan's syndrome. *Laryngoscope* 1960;70:447-75.
- 3 Chynn EW, Jakobiec FA. Cogan's syndrome: ophthalmic, audiovestibular, and systemic manifestations and therapy. *International Ophthalmol Clin* 1996;36:61-72.
- 4 Haynes BF, Kaiser-Kupfer MI, Mason P, Fauci AS. Cogan syndrome: studies in thirteen patients, long-term follow-up, and a review of the literature. *Medicine (Baltimore)* 1980;59:426-41.
- 5 Vollersten R, McDonald TJ, Young BR, Banks PM, Stanson AW, Istrup DM. Cogan's syndrome: 18 cases and a review of the literature. *Mayo Clin Proc* 1986;61:344-61.
- 6 St Clair EW, McCallum RM. Cogan's syndrome. *Curr Opin Rheumatol* 1999;11:47-52.
- 7 Helmchen C, Arbusow V, Jager L, Strupp M, Stocker W, Sculz P. Cogan's syndrome: clinical significance of antibodies against the inner ear and cornea. *Acta Otolaryngol (Stockh)* 1999;119:528-36.
- 8 Vollersten R. Vasculitis and Cogan's syndrome. *Rheum Dis Clin North Am* 1990;16:433-8.
- 9 McCallum RM, Allen NB, Cobo LM, Weber BA, Haynes BF. Cogan's syndrome: clinical features and outcomes [abstract]. *Arthritis Rheum* 1992;35(suppl):S51.
- 10 Scully RE, Mark EJ, McNeely WF, Ebeling SH. Weekly clinicopathological exercises. *N Engl J Med* 1999;340:635-41.
- 11 Berrettini S, Ferri C, Ravecca F, La Civita L, Bruschini L, Riente L, *et al.* Progressive sensorineural hearing impairment in systemic vasculitides. *Semin Arthritis Rheum* 1998;27:301-18.
- 12 Richardson B. Methotrexate therapy for hearing loss in Cogan's syndrome. *Arthritis Rheum* 1994;37:1559-61.
- 13 Allen NB, Cox CC, Cobo M, Kisslo J, Jacobs MR, McCallum RM, *et al.* Use of immunosuppressive agents in the treatment of severe ocular and vascular manifestations of Cogan's syndrome. *Am J Med* 1990;88:296-301.