

## LESSON OF THE MONTH

# Sarcoidosis: TB or not TB?

I Litinsky, O Elkayam, G Flusser, R Segal, M Yaron, D Caspi

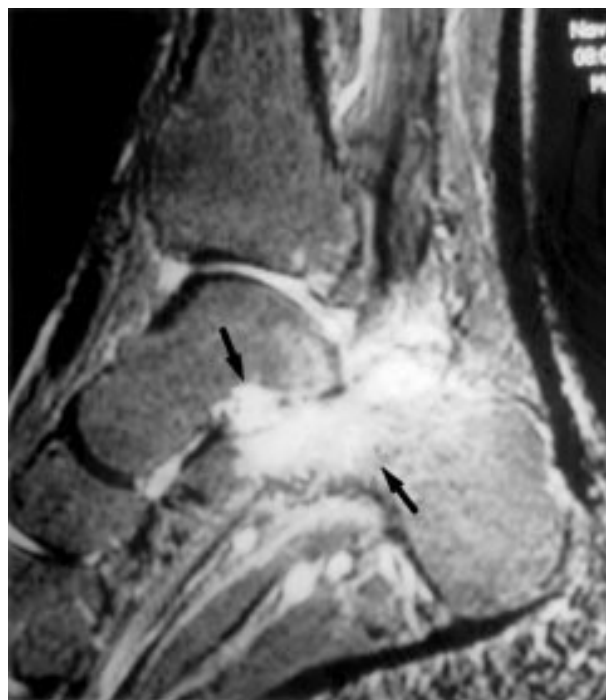
Series editor: Anthony D Woolf

Ann Rheum Dis 2002;61:385-386

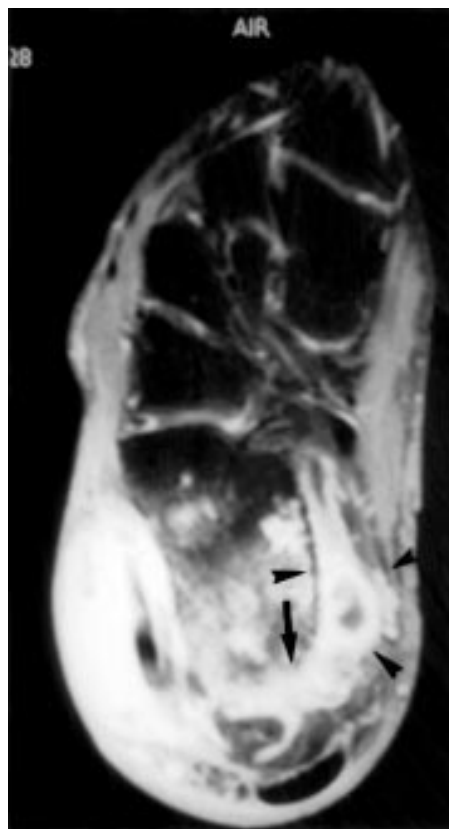
### CASE HISTORY

A 37 year old man presented at another centre with a three week history of high grade fever, chills, and cervical lymphadenopathy. Routine laboratory tests as well as a purified protein derivative (PPD) test were within the normal ranges. Computed tomography of the chest and abdomen showed massive lymphadenopathy in the mediastinum and retroperitoneum. A cervical lymph node biopsy disclosed non-caseating granuloma negative for *Mycobacterium tuberculosis* by acid fast staining and culture. Sarcoidosis was diagnosed and the patient was treated with corticosteroids at a maximum dose of 60 mg/day for two months with complete resolution of the fever and lymphadenopathy.

Four months later, the patient developed right carpal tunnel syndrome, which was attributed to a lesion occupying space in the right radius; the tumour was removed and histology demonstrated non-caseating granuloma, interpreted as osseous sarcoidosis. A short course of corticosteroids was renewed and tapered off. He remained asymptomatic during the following six months when he developed oligoarthritis affecting the right ankle and wrist. Synovectomy of his right wrist showed non-caseating granuloma. Culture of the synovium was negative for *Mycobacterium tuberculosis*. Despite treatment with systemic and intra-articular steroids and addition of a three month course of weekly methotrexate, chronic and disabling monoarthritis of the right ankle persisted, confining him to a wheelchair.



**Figure 1** MRI of the ankle. Gadolinium enhanced axial T<sub>1</sub> with fat suppression shows erosions at the calcaneus and talus bones (arrows).



**Figure 2** MRI of the ankle. Sagittal STIR shows erosions at the calcaneus and talus bones (arrows) and abscess formation within the calcaneus and in the soft tissues surrounding the bone (arrow heads).

This time, a year after developing the oligoarthritis, the patient was admitted to our department. At presentation physical examination was normal except for his right ankle, which was extremely tender, swollen, and warm. A chest x ray examination and routine blood tests were normal except for increased acute phase reactants. The PPD test was 20 mm. Arthrocentesis of the right ankle produced 5 ml of white creamy fluid, which was positive for *Mycobacterium tuberculosis* by polymerase chain reaction (PCR) and culture. A magnetic resonance imaging (MRI) study of the joint disclosed by axial T<sub>1</sub> fat suppressed gadolinium enhanced (fig 1) and sagittal STIR (fig 2) showed irregularly hyperaemic calcaneous bone with erosion on its posterior site (arrows), soft tissue abscess with enhancing walls (arrow heads), and large amounts of fluid.

**Abbreviations:** MRI, magnetic resonance imaging; PCR, polymerase chain reaction; PPD, purified protein derivative

Re-evaluation of the first lymph node biopsy ratified the diagnosis of non-caseating granuloma. However, PCR evaluation of the tissue was positive for *Mycobacterium tuberculosis*.

The patient was given multiagent 4 antituberculosis treatment for six months, and underwent arthrodesis of the right ankle, and his condition improved impressively.

## DISCUSSION

We have presented a patient diagnosed with sarcoidosis. The diagnosis was based on repeated biopsies, confirming non-caseating granuloma, negative *Mycobacterium* cultures, negative PPD, and a complete response to corticosteroids. The patient developed chronic monoarthritis of the right ankle, which turned out to be secondary to *Mycobacterium tuberculosis* infection.

Distinguishing between sarcoidosis and tuberculosis can be a challenge. The main manifestations of both diseases are in the lungs, in association with systemic symptoms such as fever, malaise, anorexia, and weight loss.<sup>1,2</sup> Both diseases can affect the same organs; both can produce granuloma, which may be non-caseating in sarcoidosis as well as in tuberculosis.<sup>1,2</sup> Musculoskeletal involvement is a well known manifestation of both diseases.<sup>3,4</sup> Peripheral arthritis may be found in up to 5% of patients with tuberculosis<sup>5</sup> and up to 21% of patients with sarcoidosis.<sup>6,7</sup>

Our case raises a few intriguing questions of the relationships between sarcoidosis and tuberculosis: Was his disease tuberculosis masquerading as sarcoid from the very start of his medical puzzle? Or was it real sarcoid later complicated by tuberculosis in a patient who used corticosteroids?

The original diagnosis of sarcoidosis was supported by the clinical picture, the negative PPD test, the non-caseating granuloma, the absence of *Mycobacterium tuberculosis*, and his excellent response to corticosteroids. Does the positive retrospective PCR examination of the lymph node (biopsied two years previously) rule out the diagnosis of sarcoidosis? Several studies have shown the presence of *Mycobacterium* DNA in sarcoid granuloma, suggesting previous exposure to *Mycobacterium*, which might have induced a granulomatous reaction.<sup>8,9</sup>

The key to the diagnosis of tuberculosis is a high degree of awareness. The laboratory diagnosis is based on several methods such as direct microscopy, tissue culture, and PCR based nucleic acid amplification techniques. Although direct microscopy has low sensitivity (about 65%), tissue culture is a "gold standard" for diagnosis, with positive results for synovial fluid up to 80%. However, it requires four to six weeks before growth is detected.<sup>10</sup> The principal advantage of PCR methods is that they provide a rapid diagnosis with extremely high sensitivity 97–100% and specificity of 90–100% for any form of tuberculosis infection (active, treated, or asymptomatic). On the other hand, the positive PCR test does not necessarily imply active tuberculosis, the specificity for the active form being only 70%.<sup>11–13</sup>

Undoubtedly, our patient developed active tuberculosis of the ankle. Corticosteroid treatment might have contributed to the reactivation of the tuberculosis,<sup>14</sup> although the risk of corticosteroid treatment in patients with previous exposure to tuberculosis is probably lower than is generally believed.<sup>15,16</sup>

Finally, sarcoidosis and tuberculosis probably coexisted in this patient as has been previously shown in some other cases.<sup>17,18</sup> Sarcoidosis and tuberculosis in the same patient do not exclude each other and the respective and mutual importance of both partners of this intriguing tandem should always be considered.

This case report taught us the longstanding, fascinating, yet mysterious, links between these two granulomatous diseases. It also showed us that in the process of differential diagnosis between sarcoid and tuberculosis the correct word between the two may not be just "or" but also "and".

## THE LESSONS

- Reconsider the diagnosis if the response to treatment is not as expected.
- Look for a chronic infection such as tuberculosis in patients with chronic monoarthritis, despite an underlying disease which may explain the arthritis.
- In cases of doubt—positive PCR and suspicious clinical suggestion of tuberculosis—an empirical antituberculosis treatment should be considered.

## Authors' affiliations

I Litinsky, O Elkayam, M Yaron, D Caspi, Department of Rheumatology, Tel Aviv "Sourasky" Medical Centre, Israel  
 G Flusser, Department of Radiology, Tel Aviv "Sourasky" Medical Centre  
 R Segal, Shmuel Harofe Geriatric Medical Centre and Tel Aviv University, Tel Aviv, Israel

Correspondence: Dr I Litinsky, Department of Rheumatology, Tel Aviv Sourasky Medical Centre, 6 Weizmann Street, Tel Aviv 64239, Israel

Accepted 28 August 2001

## REFERENCES

- 1 Newman LS, Rose CS, Maier LA. Sarcoidosis. *N Engl J Med* 1997;336:1224–33.
- 2 Noppen M. Tuberculosis and sarcoidosis. *Chest* 1999;115:1480.
- 3 Peterson T. Rheumatic features of sarcoidosis. *Curr Opin Rheumatol* 1997;9:62–7.
- 4 Stelianides S, Belmatoug N, Fantin B. Manifestations and diagnosis of extrapulmonary tuberculosis. *Rev Mal Respir* 1997;14(suppl 5):S72–87.
- 5 Fanning A. Tuberculosis: extrapulmonary disease. *Can Med Assoc J* 1999;160:1597–603.
- 6 Perruquet JL, Harrington TM, Davis DE, Viozzi FJ. Sarcoid arthritis in North American Caucasian population. *J Rheumatol* 1984;11:521–5.
- 7 Glennas A, Kvein TK, Melby K, Refvem OK, Andrup O, Karstensen B, et al. Acute sarcoid arthritis: occurrence, seasonal onset, clinical features and outcome. *Br J Rheumatol* 1995;34:45–50.
- 8 Fidler HM, Rook GA, Johnson NM, McFadden J. *Mycobacterium tuberculosis* DNA in tissue affected by sarcoidosis. *BMJ* 1993;306:546–9.
- 9 Popper HH, Klemen H, Hoefler G, Winter E. Presence of mycobacterium DNA in sarcoidosis. *Hum Pathol* 1997;28:796–800.
- 10 Inderlied CB. *Mycobacteria*. In: Armstrong D, Cohen J, eds. *Infectious diseases*. London: Mosby, 1999:8.20.1–22.
- 11 Schluger NW, Kinney D, Harkin TJ, Rom WN. Clinical utility of the polymerase chain reaction in diagnosis of infections due to *Mycobacterium tuberculosis*. *Chest* 1994;105:1116–21.
- 12 Querol JM, Farga MA, Granda M, Gimeno C, Garcia-de-Lomas J. The utility of polymerase chain reaction (PCR) in the diagnosis of pulmonary tuberculosis. *Chest* 1995;107:1631–35.
- 13 Bemer-Melchior P, Germaud P, Drugeon HB. Diagnosis of extrapulmonary tuberculosis by a commercial polymerase chain reaction kit. *Pathol Biol (Paris)* 1998;46:597–603.
- 14 Golding IM, Lester W, Berg GS. Adrenocortical steroids and tuberculosis. *N Engl J Med* 1956;254:1026–8.
- 15 Smyllie HC, Connolly CK. Incidence of serious complications of corticosteroid therapy in respiratory disease. *Thorax* 1968;23:571–81.
- 16 Cowie RL, King LM. Pulmonary tuberculosis in corticosteroid-treated asthmatics. *S Afr Med J* 1987;72:849–51.
- 17 Wong CF, Yew WW, Wong PC, Lee J. A case of concomitant tuberculosis and sarcoidosis with mycobacterial DNA present in the sarcoid lesion. *Chest* 1998;114:626–9.
- 18 Knox AJ, Wardman AG, Page RL. Tuberculous pleural effusion occurring during corticosteroid treatment of sarcoidosis. *Thorax* 1986;41:651.