

# Anti-tumour necrosis factor monoclonal antibody treatment for ocular Behçet's disease

G Triolo, M Vadalà, A Accardo-Palumbo, A Ferrante, F Ciccia, E Giardina, P Citarrella, G Lodato, G Licata

*Ann Rheum Dis* 2002;**61**:560–561

Ocular involvement is a common and serious component of Behçet's disease (BD). This manifestation worsens without treatment, and loss of vision occurs an average of 3.3 years after the onset of eye symptoms.<sup>1</sup> High levels of tumour necrosis factor (TNF)  $\alpha$  have been found in the serum of patients with BD together with other proinflammatory cytokines.<sup>2,3</sup> Many studies indicate a strong polarised Th1 immune response as in rheumatoid arthritis and Crohn's disease.<sup>4</sup>

High affinity monoclonal anti-TNF $\alpha$  antibody treatment has been recently introduced for patients with Crohn's disease or rheumatoid arthritis who were resistant to standard treatment. We describe the use of the anti-TNF $\alpha$  chimeric monoclonal antibody, infliximab (Remicade; Centocor Inc, Malvern, PA; Schering Plough SpA, Italy) in a patient with BD who exhibited a severe ocular involvement refractory to standard treatment.

## CASE REPORT

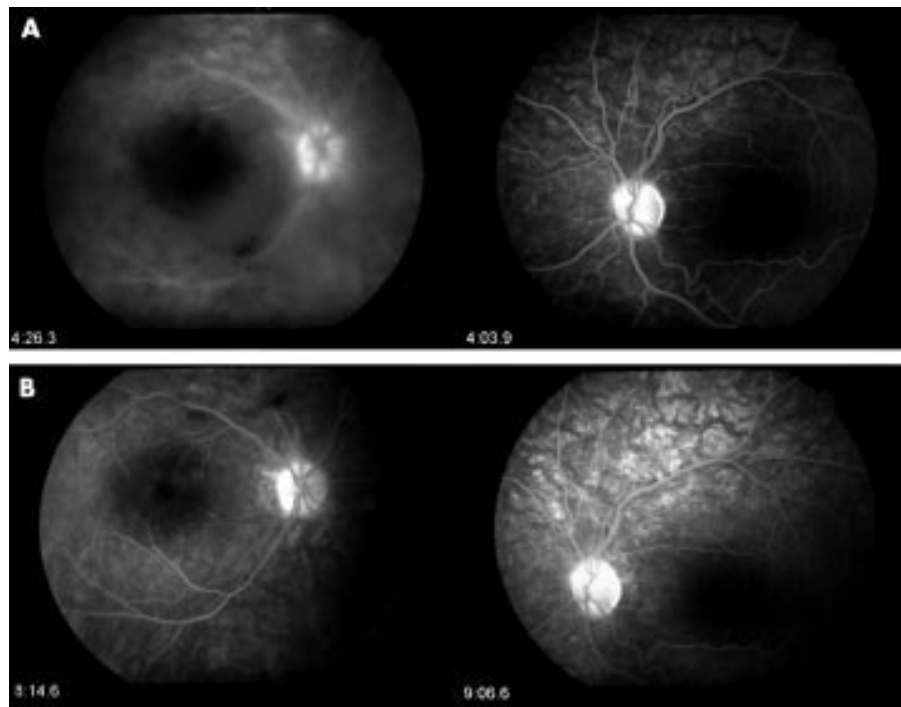
An 18 year old man with BD was admitted in January 2001. He had been diagnosed with BD four years earlier in view of his presentation of recurrent oral and genital aphthous ulcers, polyarthritis, erythema nodosum, and superficial thrombophlebitis. The onset of the ocular disease was in 1999, when the patient was treated with steroids and cyclosporin for bilateral posterior uveitis. In the course of cyclosporin treatment he had several attacks of uveitis in both the eyes.

Cyclophosphamide was introduced without a satisfactory control of disease symptoms and of the ocular manifestations.

A new relapse of severe neuroretinitis occurred in October 2000. He was treated with intravenous methylprednisolone, followed by oral prednisone (50 mg/day), topical steroids, and mydriatic agents. Tapering of the prednisone dose resulted in November in a new acute attack of neuroretinitis in the left eye. Intravenous methylprednisolone was reintroduced, followed by 75 mg of oral prednisone and by local peribulbar injection of methylprednisolone every 15 days. Recovery was slow and less evident and, the visual acuity being 20/30, optic disc oedema and retinal vasculitis were still present. The patient received prednisone maintenance treatment (15 mg /day) for approximately four weeks before receiving an infliximab infusion.

At admission, fluorescein angiography (fig 1A) showed a hyperfluorescent optic disc in both eyes, and diffuse irregular mottled retinal hyperfluorescence and haemorrhagic hypofluorescence in the left eye. Oral and genital ulcerations were present together with erythema nodosum, thrombophlebitis, and arthritis. An infusion protocol was designed and approved by the Department of Internal Medicine Institutional Board and informed consent for treatment was obtained from the patient.

The patient was infused with infliximab, 5 mg/kg, by a two hour infusion, at weeks 0, 2, 4, and 8, and the patient observed for a further two hours without adverse effects. An improvement in symptoms was noticed within 24 hours after



**Figure 1** (A) Fluorescein angiography obtained at admission, showing a hyperfluorescent optic disc in both eyes, diffuse irregular mottled retinal hyperfluorescence, and haemorrhagic hypofluorescence in the left eye. (B) Fluorescein angiography obtained before the third infusion, showing a normal optic disc aspect, improvement of macular oedema in the right eye and still in the mottled aspect of retinal capillary filling.

receiving the first infusion. At the time of the second infusion he had a complete remission of all signs and symptoms. A new fluorescein angiography was performed just before the third infusion. At that time there was a normal optic disc aspect, improvement of macular oedema in the right eye and still in the mottled aspect of retinal capillary filling (fig 1B). Before the first infusion the erythrocyte sedimentation rate was 35 mm/1st h and the C reactive protein level was 34 mg/l. They decreased to 22 mm/1st h and 6 mg/l (normal <10 mg/l), respectively, by week 2 and remained within the normal range for the duration of the study.

## DISCUSSION

This is the first report, to our knowledge, of the treatment of ocular BD with anticytokine specific treatment. Treatment with infliximab led, in our patient, to a complete remission of all disease manifestations and there was no recurrence after steroid tapering.

Three interesting points can be made. Firstly, the drug had a profound effect on ocular BD as well as on the other manifestations of disease. This effect on global diseases seems to be remarkable, as standard treatments had failed in our patient. Secondly, the onset of improvement was fast. Thirdly, when a loading dose regimen of four infusions (weeks 0, 2, 6, and 8) was used, remission continued for up to eight weeks. Further confirmation of the beneficial effects of TNF $\alpha$  blockade in randomised, controlled, double blind studies is necessary.

## Authors' affiliations

**G Triolo, A Accardo-Palumbo, A Ferrante, F Ciccia, E Giardina,** Rheumatology and Clinical Immunology Unit, Palermo University Hospital, Italy  
**M Vadala, G Lodato,** Division of Ophthalmology, Palermo University Hospital  
**P Citarrella,** Division of Haematology, Palermo University Hospital  
**G Licata,** Division of Internal Medicine, Palermo University Hospital

Correspondence to: Professor G Triolo, Rheumatology and Clinical Immunology Unit, Istituto di Clinica Medica, Policlinico Universitario, Piazza delle Cliniche 2, 90127 Palermo, Italy; triolog@iscalinet.it

Accepted 7 November 2001

## REFERENCES

- 1 **Mamo JG.** The rate of visual loss in Behçet's disease. *Arch Ophthalmol* 1970;84:451-2.
- 2 **Amzaoui K, Hamza M, Ayed K.** Production of TNF alpha and IL-1 in active Behçet's disease. *J Rheumatol* 1990;17:1428-9.
- 3 **Megel JL, Dilsen N, Sanguedolce V, Gul A, Bongrand P, Ocal L, et al.** Overproduction of monocyte derived tumor necrosis factor alpha, interleukin (IL)6, IL-8 and increased neutrophil superoxide generation in Behçet's disease. A comparative study with familial Mediterranean fever and healthy subjects. *J Rheumatol* 1993;20:1944-9.
- 4 **Frasanito MA, Dammacco R, Cafforio P, Dammacco F.** Th1 polarization of the immune response in Behçet's disease: a putative role of interleukin-12. *Arthritis Rheum* 1999;42:1967-74.

# Is hirudin a potential therapeutic agent for arthritis?

**K Scott**

*Ann Rheum Dis* 2002;61:561-562

A recent pilot study by Michalsen *et al* showed that a single brief treatment with medicinal leeches (*Hirudo medicinalis*) can give relatively long term relief from pain in osteoarthritic joints. A number of leech salivary components are known, which may contribute to this effect.<sup>1</sup> Although there was no evidence for any therapeutic outcomes, other than pain relief, the extended timescale suggests that one or more leech components may exert more than an anaesthetic or analgesic effect. Independent evidence indicates that the leech anticoagulant protein, hirudin, may make a significant contribution to this phenomenon.

A synovial stimulatory protein (SSP), acting as an autoantigen to which T lymphocytes from patients with rheumatoid arthritis respond, has been identified in synovial fluid.<sup>2</sup> A smaller protein, derived from human fibroblasts, and identifiable from its amino acid sequence as a fragment of the SSP, has been found to bind to a hirudin-agarose affinity chromatography matrix.<sup>3</sup> More recently, we have shown that both the SSP and its smaller derivative, now known as the DING protein, are found in synovial fluid samples and synovial fibroblasts from normal subjects, and from patients with a range of arthritic conditions, including rheumatoid and osteoarthritis. The proteins act as autocrine growth stimulators for normal and arthritic synovial fibroblasts.<sup>4</sup> The presence of hirudin can inhibit this stimulation.<sup>3</sup> Given that hyperproliferation of synovial fibroblasts is believed to contribute to the formation of the destructive pannus that is characteristic of some arthritic joints,<sup>5</sup> the SSP and DING protein may act to promote this process, and hirudin may have the potential to retard it. Hirudin might thus have value in treating arthritis. Recombinant hirudin has already been used in a range of therapeutic anticoagulant applications,<sup>6-8</sup> so patient safety and other clinical data have been collected and evaluated. A trial of hirudin in an antiarthritis role may now be appropriate.

The first DING protein isolates displayed proteolytic activity, and its inhibition was believed to be the basis of the action of hirudin, but subsequent DING preparations have had little or no proteolytic activity.<sup>3, 4</sup> The basis of the inhibitory action of hirudin is thus not known. Peptides derived from hirudin such as hirulog (bivalirudin), which are effective anticoagulants by virtue of thrombin inhibition,<sup>9, 10</sup> may not possess the ability to bind and inhibit the SSP or DING proteins.

## ACKNOWLEDGEMENTS

The experiments from the author's laboratory were supported by the Auckland Medical Research Foundation, and the Staff Research Fund of the University of Auckland.

## Author's affiliations

**K Scott,** School of Biological Sciences, University of Auckland, Private Bag 92019, Auckland, New Zealand Correspondence to Dr Scott; k.scott@auckland.ac.nz

Accepted 18 December 2001

## REFERENCES

- 1 **Michalsen A, Deuse U, Esch T, Dobos G, Moebus S.** Effect of leeches therapy (*Hirudo medicinalis*) in painful osteoarthritis of the knee: a pilot study. *Ann Rheum Dis* 2001;60:986.
- 2 **Hain NAK, Stuhlmuller B, Hahn GR, Kalden JR, Deutzmann R, Burmester GR.** Biochemical characterisation and microsequencing of a 205kDa synovial protein stimulatory for T cells and reactive with rheumatoid factor containing sera. *J Immunol* 1996;157:1773-80.
- 3 **Bush D, Fritz H, Knight C, Mount J, Scott K.** A hirudin-sensitive, growth-related proteinase from human fibroblasts. *Biol Chem* 1998;379:225-9.
- 4 **Adams L, Davey S, Scott K.** The DING protein: an autocrine growth-stimulatory protein related to the human synovial stimulatory protein. *Biochim Biophys Acta* (in press).