

CONCISE REPORT

Kinetics of hepatitis C (HCV) viraemia and quasispecies during treatment of HCV associated cryoglobulinaemia with pulse cyclophosphamide

J Thiel, T Peters, A Mas Marques, B Rösler, H H Peter, S M Weiner

Ann Rheum Dis 2002;**61**:838–841

Objective: To investigate the effect of pulse cyclophosphamide treatment on hepatitis C virus (HCV) kinetics and quasispecies in interferon α (IFN α) resistant HCV related cryoglobulinaemic vasculitis.

Methods: Reports on two patients with severe manifestations of HCV related cryoglobulinaemia who failed to respond to interferon α are given. Both patients were treated with pulse cyclophosphamide (750–1000 mg/month for six and 11 months, respectively). HCV RNA was quantified and HCV quasispecies determined in cryoprecipitates and supernatants before and during treatment.

Results: Cryocrit and complement activation decreased in both patients with rebound of cryocrit in one case during continuing pulse cyclophosphamide treatment. Vasculitic symptoms improved. Alanine aminotransferase (ALT) levels and HCV viral load (0.2–0.4 log) increased slightly and reached pretreatment levels after cyclophosphamide was stopped. A highly heterogeneous quasispecies was found in the cryoprecipitate and supernatant of one patient, whereas the viral population was homogeneous in the other patient. After six cycles of cyclophosphamide, viral distances decreased non-significantly. However, phylogenetic analysis showed the evolution of distinct viral strains in one patient and replacement of the main viral population by another population in the second patient.

Conclusions: Immunosuppressive treatment with pulse cyclophosphamide has a temporary limited effect on HCV associated cryoglobulinaemia and leads to a reversible increase of ALT levels and HCV viral load. Short term immunosuppression does not affect the viral heterogeneity as measured by amino acid and nucleotide distances in the hypervariable region 1 of HCV. A change of quasispecies was observed, but further studies are needed to evaluate if this does affect the outcome of IFN α treatment in such patients.

Since the discovery of hepatitis C virus (HCV) as a major cause of mixed cryoglobulinaemia (MC),¹ interferon α (IFN α) with or without ribavirin has been reported to be effective in the treatment of this condition.^{2,3} However, owing to a high relapse rate and IFN α side effects,^{2,4} the administration of immunosuppressive agents is often inevitable. Furthermore, IFN α treatment is not recommended for acute exacerbations of the disease.

The HCV population within an individual consists of several variants of the viral genome, the so-called quasispecies.⁵ It is supposed that the evolution of different HCV quasispecies is promoted by the host's immunological pressure.

We report on two patients with worsening of mixed cryoglobulinaemia during IFN α treatment, therefore requiring intravenous pulse cyclophosphamide treatment. The

influence of this immunosuppressive treatment on HCV viral load, alanine aminotransferase (ALT) levels and HCV quasispecies was studied.

METHODS

Case reports

Patient A

A 57 year old male patient presenting with persistent arthralgia, sensory polyneuropathy of the lower legs, and livedo reticularis was diagnosed with type II MC with monoclonal IgM κ . Subsequently, HCV infection, genotype 1b, was detected. Liver biopsy showed an inflammatory activity I^o and fibrosis II^o. Bone marrow biopsy disclosed focal lymphoplasmacytosis without signs of non-Hodgkin's lymphoma. IFN α treatment (5 million IU three times a week) resulted in a normalisation of ALT levels within three months, but HCV RNA remained detectable. Four months after having started IFN α treatment, the patient had haemorrhagic rhinitis and progressive sensory polyneuropathy with pain and burning of the lower legs. Mucosal biopsy showed vasculitic ulcers. Neurological examination disclosed an axonal polyneuropathy with loss of sensory conduction of the sural nerve and reduced motor conduction of the left peroneal nerve. Administration of low dose methylprednisolone (16 mg/day) resulted in an improvement of the mucosal vasculitis, but the polyneuropathy remained unchanged. As treatment failed, IFN α was stopped and cyclophosphamide pulse treatment (1000 mg monthly) was started.

Patient B

A 65 year old female patient was diagnosed as having HCV associated cryoglobulinaemia type II with monoclonal IgM κ , leading to weakness, purpura, and polyneuropathy. The HCV genotype was 1b. Bone marrow biopsy showed no signs of lymphoma and muscle biopsy disclosed an axonal demyelinating polyneuropathy. IFN α treatment (5 million IU three times a week) resulted in a normalisation of ALT levels and a negative HCV polymerase chain reaction after 18 months. Nevertheless, the polyneuropathy worsened, with progressive hypoaesthesia, hypopallaesthesia, and weakness of the legs. Because of recurrent vasculitic purpura, IFN α was reduced to 3 million IU three times a week after six months and intermittently combined with corticosteroid treatment (prednisone up to 75 mg/day). As polyneuropathy persisted and purpura recurred IFN α treatment was stopped. This led to a viral rebound. Liver biopsy showed mild inflammation and fibrosis II^o. Because of severe myalgias, muscular weakness,

Abbreviations: ALT, alanine aminotransferase; HCV, hepatitis C virus; HVR, hypervariable region; IFN α , interferon α ; MC, mixed cryoglobulinaemia

Table 1 Genetic identities and distances of amino acids and nucleotides in the hypervariable region 1 of HCV in the cryoprecipitate before and after six months of pulse cyclophosphamide treatment of cryoglobulinaemic vasculitis in patients A and B, calculated by BioEdit version 5.0.9. The differences were not statistically significant

Patient	HCV clones	Identities (SD)		Distances (SD)	
		Amino acids	Nucleotides	Amino acids	Nucleotides
A	Before pulse cyclophosphamide	0.600 (0.224)	0.760 (0.132)	0.5669 (0.3562)	0.3434 (0.2076)
	After pulse cyclophosphamide	0.650 (0.217)	0.788 (0.138)	0.5101 (0.3735)	0.2982 (0.2183)
B	Before pulse cyclophosphamide	0.905 (0.106)	0.955 (0.047)	0.1035 (0.1180)	0.0490 (0.0516)
	After pulse cyclophosphamide	0.930 (0.102)	0.966 (0.049)	0.0823 (0.1241)	0.0370 (0.0539)

and symmetrical vasculitic purpura, pulse cyclophosphamide treatment (750 mg/month for six months) and low dose prednisone (10 mg/day) was started

Detection and isolation of cryoglobulins

Cryoglobulins were detected and isolated as previously described.⁶ The cryocrit was determined by centrifugation of the serum in packed cell volume tubes at 4°C.

Virological studies

Anti-HCV antibodies were determined by third generation enzyme linked immunosorbent assay (ELISA; Sanofi-Pasteur, France) and confirmed by Western blot (Wellcozyme, Murex Diagnostics, England). HCV RNA was measured by the HCV Amplicor kit (Roche Diagnostic Systems, Branchburg, NJ, USA). Typing of HCV was performed by Inno-Lipa assay (Innogenetics NV, Belgium)

Determination of HCV quasispecies

HCV RNA was extracted and the nucleic acid sequence of the hypervariable region (HVR) 1 was amplified and sequenced as described earlier.⁷ The nucleic acid sequences were aligned and translated with the program BioEdit version 5.0.9, which was also used to calculate the sequence identities and distances.

For phylogenetic analysis Phylogeny Interference Package (PHYLIP) version 3.57c was used: the distances between nucleic acid sequences and amino acid sequences were estimated with Dnadist (Kimura 2 parameter, transition/transversion ratio 2.0) and Protdist (Dayhoff PAM matrix), respectively. Unrooted phylogenetic trees were constructed with Neighbor (Neighbor-joining) and TreeView 1.6.6.⁸ Seqboot was used to create 100 replicates for calculation of bootstrap values.

RESULTS

Clinical effects of pulse cyclophosphamide

Patient A

Cyclophosphamide pulse treatment dramatically decreased cryocrit and complement activation (fig 1). Pain and burning in the lower legs improved gradually, as did the muscular action potential of the peroneal nerve. The sensory conduction of the sural nerve did not improve. However, when immunosuppressive treatment was stopped, cryoglobulin and C3d levels increased again. Residual neuropathic symptoms were controlled with carbamazepine. At follow up, a self limited relapse of vasculitis with purpura, arthralgia, and neuropathic pain occurred after 15 months.

Patient B

The cryocrit slightly decreased after four cycles of cyclophosphamide pulse treatment (fig 1). A temporary response of C3d

was seen. Vasculitic lesions and myalgia completely resolved within four weeks. Despite continuing treatment, two further vasculitic episodes occurred three weeks after the second and fifth cyclophosphamide bolus. Polyneuropathy related symptoms were resistant to treatment. At the end of four months' follow up, no further episode of vasculitic purpura occurred.

Effect of pulse cyclophosphamide on virological and liver parameters

During pulse cyclophosphamide treatment the ALT levels fluctuated in both patients at a low level (fig 1). The viral load increased transiently from 1.5×10^6 to 3.9×10^6 copies/ml (0.4 log) in patient A and from 0.9×10^6 copies/ml to 1.5×10^6 copies/ml (0.2 log) in patient B (fig 1).

Sequence analysis of a fragment that included the HVR1 showed a marked heterogeneity in patient A and a relatively homogeneous viral population in patient B (web extra table W1). After six months' pulse cyclophosphamide treatment a minor non-significant decrease in amino acid and nucleotide sequence distances was seen (table 1). The viral heterogeneity of HCV clones in the supernatant, derived from the analysis before and after treatment, was similar to that of the cryoprecipitate in both patients (data not shown). The phylogenetic reconstruction in fig 2 shows the evolutionary relationships of all viral amino acid sequences of HVR1. The phylogenetic analysis of the HVR1 amino acid sequences of patient A had a tendency to form clusters over time. Additionally, a new distinct variant was found (B2842). The main virus strains did not change in this patient. In patient B the main population was replaced by another after six months. The divergence between both main populations was 16% (calculated as the number of mutations).

DISCUSSION

We report on two patients with chronic hepatitis C and MC, who showed recurrent cryoglobulinaemic vasculitis and worsening of polyneuropathy despite an initial response to IFN α and normalisation of ALT levels. As in our patients, exacerbation of cryoglobulinaemia related ischaemic and neurologic manifestations during IFN α treatment have been reported previously.⁹ Besides the ability to induce polyneuropathy, IFN α also may impair the revascularisation of ischaemic organs.^{2,4} In these instances, immunosuppressive treatment of MC with corticosteroids or cyclophosphamide is often needed.⁹ Pulse cyclophosphamide produced a decrease in the cryocrit and complement activation, a temporary improvement of vasculitis, regression of neuropathy in one patient, but also caused minor flares of hepatitis C. Patients resistant to intravenous pulse cyclophosphamide may respond to oral cyclophosphamide and plasmapheresis, as recently reported.¹⁰ However, as

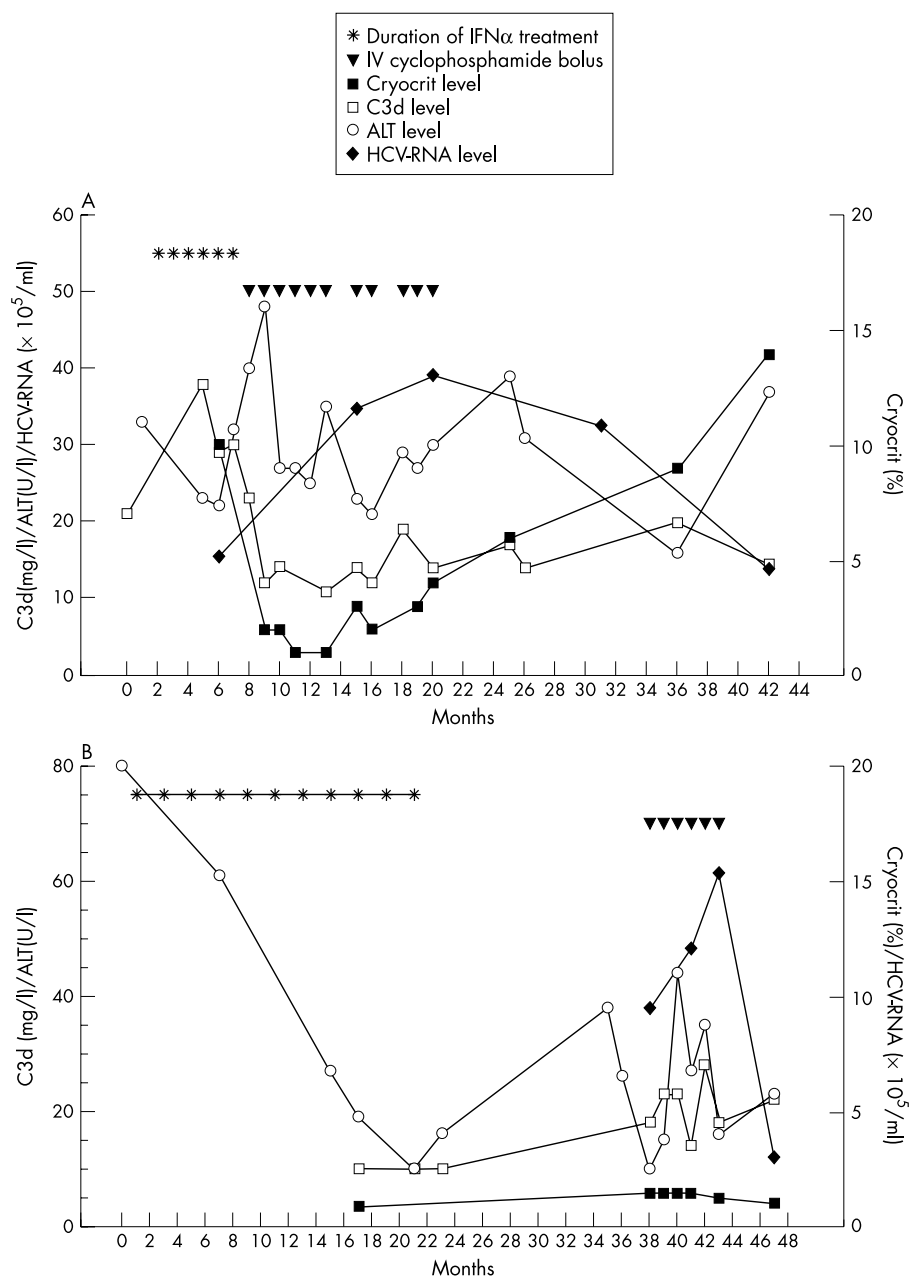


Figure 1 Response of mixed cryoglobulinaemia to pulse cyclophosphamide treatment and effect on virological parameters in patient A (A) and patient B (B). Normal values: C3d <10 mg/l; ALT <18 U/l. HCV-RNA level measured with an HCV AmpliCor kit.

liver function may deteriorate and HCV viraemia may increase during immunosuppression,¹¹ controlled studies have to be performed to assess the optimal treatment for cryoglobulinaemic neuropathy.

The heterogeneity of the HCV population seems to represent a mechanism to evade the host's immune system.⁵ Mutations are most commonly found in the HVR of the envelope protein, which are recognised by neutralising antibodies. A highly heterogeneous quasispecies may lead to increased resistance to IFN α . This concept also held true for both patients: patient A had a high amino acid heterogeneity and no response to IFN α , patient B had a relatively low heterogeneity and a short term response to IFN α , which might have lasted longer if steroids had not had to be applied.

Of special interest are studies in which the evolution of viral quasispecies was analysed over time. In acute hepatitis C, patients with resolving hepatitis showed a decrease in the genetic diversity of HVR1, whereas those with progressing hepatitis had a marked increase in diversity.¹² A significant decrease in viral heterogeneity was seen in immunosup-

pressed patients after liver transplantation,¹³ in those co-infected with HIV and reduced CD4 counts, and in agammaglobulinaemic patients,¹⁴ suggesting that the activity of T helper lymphocytes and the humoral immune system influences the evolution of viral mutants. Pulse cyclophosphamide reduces the activity of both T and B cells. During this short term immunosuppression we did not find an increase or a significant decrease of viral distances, in contrast with the data previously reported after liver transplantation,¹³ suggesting that the potency and duration of immunosuppression might be important. Moreover, phylogenetic analysis showed a change of viral variants during pulse cyclophosphamide treatment. This evolution is not surprising: Complete replacements of previous quasispecies by new quasispecies have been described over several months in five of nine untreated patients with chronic hepatitis C.¹⁵

In conclusion, pulse cyclophosphamide treatment has a temporary effect on HCV associated cryoglobulinaemia. Short term immunosuppression leads to a reversible minor increase of the HCV load, but does not seem to adversely affect the viral

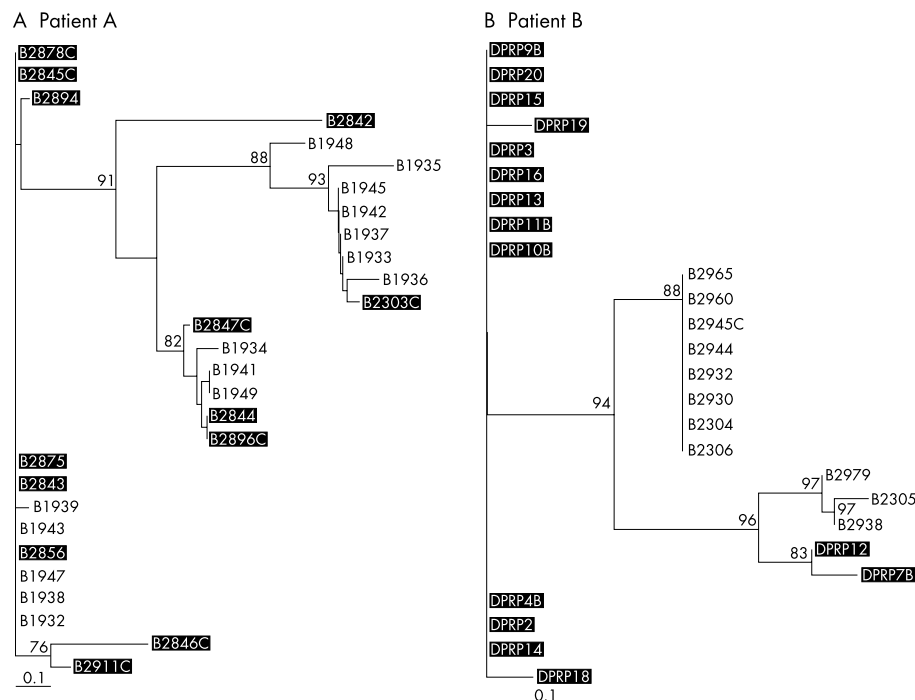


Figure 2 Phylogenetic tree of HCV isolates derived from alignments of amino acid sequences of the hypervariable region 1 in patient A (A) and patient B (B). Branch length is proportional to the evolutionary distances between sequences. Distance scale: 10% sequence dissimilarity. Bootstrap values greater than 70 are shown at the corresponding branch points. Clones derived from the cryoprecipitate after cyclophosphamide treatment are underlined (black), the others represent clones before treatment. The phylogenetic reconstruction showed sequential shifts in the viral population after six months.

heterogeneity. However, new HCV quasispecies appeared during pulse cyclophosphamide. The significance of this finding for future IFN α treatment in these patients has to be evaluated further.

ACKNOWLEDGEMENTS

We particularly thank Sabine Weber for her excellent technical support.



Amino acid sequences of the HVR1 in the cryoprecipitates before and after cyclophosphamide treatment can be seen on the web at www.annrheumdis.com

Authors' affiliations

J Thiel, H H Peter, S M Weiner, Department of Rheumatology and Clinical Immunology, University Hospital Freiburg, Germany
T Peters, B Rösler, Department of Hepatology, Gastroenterology, and Endocrinology, University Hospital Freiburg, Germany
A Mas Marques, Robert Koch-Institut, Berlin, Germany

Correspondence to: Dr S M Weiner, Department of Rheumatology and Clinical Immunology, Medizinische Klinik, Hugstetter Strasse 55, 79106 Freiburg, Germany; weiner@uni-freiburg.de

Accepted 12 March 2002

REFERENCES

- Pascual M, Perrin L, Giostra E, Schifferli JA. Hepatitis C virus in patients with cryoglobulinemia type II. *J Infect Dis* 1990;162:569–7.
- Ferri C, Marzo E, Longombardo G, Lombardini F, LaCivita L, Vanacore R, *et al.* Interferon-alpha in mixed cryoglobulinemia patients: a randomized, crossover-controlled trial. *Blood* 1993;81:1132–6.
- Zuckerman E, Keren D, Slobodin G, Rosner I, Rozenbaum M, Toubi E, *et al.* Treatment of refractory, symptomatic, hepatitis C virus related mixed cryoglobulinemia with ribavirin and interferon α . *J Rheumatol* 2000;27:2172–8.
- Cid MC, Hernandez-Rodriguez J, Robert J, del Rio A, Casademonte J, Coll-Vinent B, *et al.* Interferon-alpha may exacerbate cryoglobulinemia-related ischemic manifestations: an adverse effect potentially related to its anti-angiogenic activity. *Arthritis Rheum* 1999;42:1051–5.
- Kato N, Sekiya H, Ootsuyama Y, Nakazawa T, Hijikata M, Ohkoshi S, *et al.* Humoral response to hypervariable region 1 of the putative envelope glycoprotein (gp70) of hepatitis C virus. *J Virol* 1993;67:3923–30.
- Weiner SM, Berg T, Berthold H, Weber S, Peters T, Blum HE, *et al.* A clinical and virological study of hepatitis C virus-related cryoglobulinemia in Germany. *J Hepatol* 1998;29:375–84.
- Peters T, Schlayer HJ, Hiller B, Rösler B, Blum HE, Rasenack J. Quasispecies analysis in hepatitis C virus infection by fluorescent single strand conformation polymorphism. *J Virol Methods* 1997;64:95–102.
- Page RD. TreeView: an application to display phylogenetic trees on personal computers. *Comput Appl Biosci* 1996;12:357–8.
- Scelsa SN, Herskovitz S, Reichler B. Treatment of mononeuropathy multiplex in hepatitis C virus and cryoglobulinemia. *Muscle Nerve* 1998;21:1526–9.
- Lamprecht P, Gause A, Gross WL. Cryoglobulinemic vasculitis resistant to intermittent intravenous pulse cyclophosphamide therapy. *Scand J Rheumatol* 2000;29:201–2.
- Arend SM, Hagen EC, Kroes AC, Bruijn JA, van der Waude FJ. Activation of chronic hepatitis C virus infection by cyclophosphamide in a patient with cANCA-positive vasculitis. *Nephrol Dial Transplant* 1995;10:884–7.
- Farci P, Shimoda A, Coiana A, Diaz G, Peddis G, Melpolder JC, *et al.* The outcome of acute hepatitis C predicted by the evolution of the viral quasispecies. *Science* 2000;288:339–44.
- Martell M, Esteban JI, Quer J, Vargas V, Esteban R, Guardia J, *et al.* Dynamic behavior of hepatitis C virus quasispecies in patients undergoing orthotopic liver transplantation. *J Virol* 1994;68:3425–36.
- Gómez J, Martell M, Quer J, Cabot B, Esteban JI. Hepatitis C viral quasispecies. *J Viral Hepat* 1999;6:3–16.
- Kurosaki M, Enomoto N, Marumo F, Sato C. Evolution and selection of hepatitis C virus variants in patients with chronic hepatitis C. *Virology* 1994;205:161–9.