

Fulminant necrotising fasciitis developing during long term corticosteroid treatment of systemic lupus erythematosus

N Hashimoto, H Sugiyama, K Asagoe, K Hara, O Yamasaki, Y Yamasaki, H Makino

Ann Rheum Dis 2002;**61**:848–849

Skin manifestations are some of the most common clinical symptoms and signs seen in patients with systemic lupus erythematosus (SLE). However, necrotising subcutaneous infection, in particular necrotising fasciitis, is rarely encountered. It is a rapidly progressive and destructive infection of the subcutaneous tissue, associated with mortality and long term morbidity of the affected patients.¹ We describe a patient with SLE and liver cirrhosis complicated by severe necrotising fasciitis who had been receiving corticosteroid treatment for 20 years. Necrotic skin tissue cultures grew both *Staphylococcus aureus* and *Serratia marcescens*. Despite aggressive treatment, including administration of antibiotics, emergency debridement, and total plasma exchange for severe liver damage, she died of disseminated intravascular coagulation and multiple organ failure owing to serious bacterial infection after two months in hospital. This case suggests that severe necrotising fasciitis may occur in SLE without lupus flare up during long term treatment with low dose corticosteroids.

CASE REPORT

A 58 year old Japanese woman, who had been receiving oral prednisolone treatment for SLE for 20 years, was admitted to our hospital because of a swollen and erythematous left leg. She had taken 5 mg prednisolone daily for more than 10 years and no other immunosuppressive agents. She had had liver cirrhosis due to hepatitis C virus infection five years earlier. In December 1999 she had small wound in her left ankle. There was widespread violaceous discolouration of the skin and scattered bullae over the left knee and thigh with oedema extending from the ankle to mid-calf (fig 1A). On admission, she was in septic shock and had multiple organ failure, including hepatic and renal dysfunction. Her vital signs on arrival were blood pressure 82/62 mmHg, body temperature 38.0°C, pulse rate 80 beats/min, and respiratory rate 18/min. She had jaundice without ascites. She was alert and answered questions properly. Laboratory investigations showed a white blood cell count of $21.6 \times 10^9/l$ with 54% segmented and 29% bands, a haemoglobin level of 131 g/l, a platelet count of $133 \times 10^9/l$, C reactive protein (CRP) 130 mg/l, blood urea nitrogen 17.9 mmol/l of urea, creatinine 216 $\mu\text{mol/l}$, aspartate aminotransferase 135 IU/l, alanine aminotransferase 90 IU/l, and total bilirubin 136 $\mu\text{mol/l}$. Blood glucose was 5.8 mmol/l, and glycohaemoglobin was 0.052. Immunoserological analysis showed C3 0.4 g/l, C4 0.3 g/l, CH₅₀ 18.4 U/ml, and anti-double stranded DNA antibody 5 U/ml. Blood culture was negative for bacteria or fungi. Antibodies to hepatitis C virus and its RNA were both positive. There was no cryoglobulinaemia.

Emergency debridement of the anterior, posterior, and lateral compartments of the left leg was performed. Methicillin sensitive *Staphylococcus aureus* and *Serratia marcescens* were recovered from necrotic tissue culture. Fosfomycin 4 g/day and sultamicillin tosilate 1.125 mg/day were substituted for the initial broad spectrum antibiotics. A skin biopsy specimen including subcutaneous tissue showed extensive infiltration of inflammatory cells along the superficial fascia, a characteristic of necrotising fasciitis (fig 1B). Over the ensuing days her vital signs and renal function improved once. The CRP levels decreased to 30–50 mg/l, but her liver dysfunction worsened

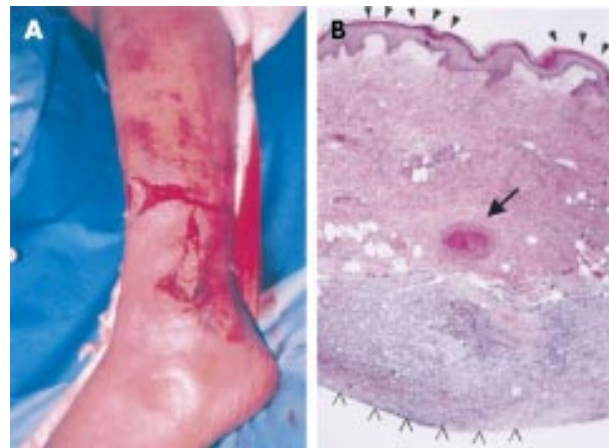


Figure 1 (A) Preoperative appearance of the swollen and erythematous left leg with purpura, skin ulcer, and bullae formation. (B) Light micrograph of skin biopsy specimens including superficial fascia. The arrow indicates thrombosis of subdermal blood vessels. Arrowheads denote epidermal detachment. Blisters show massive inflammatory cell infiltration in subcutaneous tissue and superficial fascia. (Haematoxylin and eosin, original magnification $\times 200$.)

and total plasma exchange was started on the 16th hospital day. She died of disseminated intravascular coagulation and multiple organ failure including hepatic failure eight weeks after the admission to hospital. There was no lupus flare up during the treatment of necrotising fasciitis.

DISCUSSION

Infection is a major cause of death in patients with SLE.² Active SLE itself contains many forms of immunological dysfunction, which may account for the increased susceptibility to infection. The abnormalities include acquired and inherited complement deficiencies, immunoglobulin deficiency, defects in chemotaxis, phagocytic activity, and delayed hypersensitivity. Even in clinical remission, an increased tendency to develop infections has been reported among patients with SLE.³ The decreased complement level in our patient might have been caused by consumption due to severe infection because there were no clinical symptoms of lupus flare up before and after admission to hospital.

Treatment with corticosteroids and other immunosuppressive agents may further have affected the increased susceptibility to infection. Corticosteroids decrease inflammatory response, effector cell response in cell mediated immunity, and immunoglobulin synthesis.⁴ Necrotising fasciitis is uncommon but might occur in SLE during immunosuppression due to high dose corticosteroid treatment.^{5,6} In this condition *Serratia marcescens* might be a potential pathogen causing necrotising fasciitis in susceptible hosts.⁵ In our patient, prolonged steroid administration might have increased the risk of infection and caused the fragility of skin tissue, which in turn allowed easy access of bacteria into the circulation. Liver cirrhosis may be associated with necrotising fasciitis caused by an infection of enteric bacterium such as *Escherichia*

coli or *Klebsiella* species through ascitic fluid.⁷ This possibility is unlikely in our patient because she had no ascites while in hospital. Liver failure instead affected the decreased complement production in our patient.

The case presented here suggests that long term administration of corticosteroids even in a low dose may be a risk factor for fatal infection such as necrotising fasciitis in patients with SLE.

Authors' affiliations

N Hashimoto, H Sugiyama, Y Yamasaki, H Makino, Department of Medicine and Clinical Science (Department of Medicine III), Okayama University Graduate School of Medicine and Dentistry, 2-5-1 Shikata-cho, Okayama 700-8558, Japan

K Asagoe, K Hara, O Yamasaki, Department of Dermatology, Okayama University Graduate School of Medicine and Dentistry

Correspondence to: Dr N Hashimoto; hashid@mail.goo.ne.jp

Accepted 27 March 2002

REFERENCES

- 1 **Ahrenolz DH**. Necrotizing soft tissue infections. *Surg Clin North Am* 1988;68:199–214.
- 2 **Ginzler EM**. Infections in systemic lupus erythematosus. In: Wallace DJ, Hahn BH, eds. *Dubois' lupus erythematosus*. Philadelphia: Williams and Wilkins, 1997:903–13.
- 3 **Staples PJ**, Gerding DN, Decker JL, Gordon RS Jr. Incidence of infection in systemic lupus erythematosus. *Arthritis Rheum* 1974;17:1–10.
- 4 **Boumpas DT**, Paliogianni F, Anastassiou ED, Balow JE. Glucocorticosteroid action on the immune system: molecular and cellular aspects. *Clin Exp Rheumatol* 1991;9:413–23.
- 5 **Mendez EA**, Espinoza LM, Harris M, Angulo J, Sanders CV, Espinoza LR. Systemic lupus erythematosus complicated by necrotizing fasciitis. *Lupus* 1999;9:157–9.
- 6 **Huang JW**, Fang CT, Hung KY, Hsueh PR, Chang SC, Tsai TJ. Necrotizing fasciitis caused by *Serratia marcescens* in two patients receiving corticosteroid therapy. *J Formos Med Assoc* 1999;98:851–4.
- 7 **Ho PL**, Tang WM, Yuen KY. *Klebsiella pneumoniae* necrotizing fasciitis associated with diabetes and liver cirrhosis. *Clin Infect Dis* 2000;30:989–90.

Repeated arthralgia associated with granulocyte colony stimulating factor administration

A Tsukadaira, Y Okubo, S Takashi, H Kobayashi, K Kubo

Ann Rheum Dis 2002;61:849–850

CASE REPORT

We report the case of a 69 year old man with non-small lung cancer, who developed arthralgia and myalgia twice during chemotherapy using 210 mg/day of paclitaxel and 110 mg/day of nedaplatine for every four week cycle. After starting chemotherapy, arthralgia and myalgia accompanied by rising fever suddenly occurred on the fifth consecutive day of subcutaneous administration of 100 µg/day of granulocyte colony stimulating factor (G-CSF; lenograstim). To determine the cause of the polyarthralgia we carried out arthroscopy in the most symptomatic joint. The left elbow and left hand joints were chosen for the biopsy. Microscopic findings of formalin fixed synovial tissue showed severe inflammatory infiltration accompanied by foreign body-type giant cell reaction, but no crystals or rheumatoid nodules (fig 1).

During the second cycle of chemotherapy we obtained the patient's informed consent to keep his serum at –80°C for assessment of drug toxicity. He was treated with the same doses of paclitaxel and nedaplatine as for the first cycle, and G-CSF was also given from day 10 after the start of chemotherapy. On day 5 after G-CSF administration, fever and

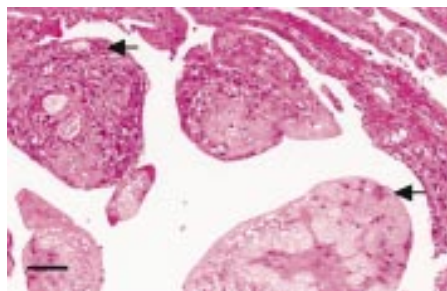


Figure 1 Microscopic findings of synovial tissue in the left elbow joint. The synovial membrane is hypertrophied and fine microvilli can be seen. Amorphous eosinophilic material deposition accompanied by foreign body-type giant cell reaction (arrows) was seen. Haematoxylin and eosin staining, ×100. Bar represents 100 µm.

grade 2 myalgia in the legs suddenly developed. During the attack, granulocytosis (neutrophil cell count $10.4 \times 10^9/l$) and a raised level of C reactive protein (80 mg/l) were seen. Before the two cycles of systemic chemotherapy, gallium scintigraphy and magnetic resonance imaging showed thoracic spinal metastasis. However, thyroid function, parathyroid function, renal function, uric acid serum levels, and electrolytes in the peripheral blood were within normal limits. Rheumatoid factor or autoimmune antibodies in the serum were negative. Neutrophil cell count, C reactive protein and histamine levels, and G-CSF and interleukin 8 (IL8) concentrations in the peripheral blood were examined on days 0, 8, and 16 (during the attack) (table 1).

DISCUSSION

Arthralgia and myalgia are well known side effects of long term infusion of paclitaxel, usually lasting for 2–6 days¹ On the

Table 1 Laboratory findings

	Day 0	Day 8	Day 16
WBC ($\times 10^9/l$)	5.3	1.2	10.4
CRP (mg/l)	2.0	12.6	80
Histamine (pg/ml)	550	960	350
G-CSF (pg/ml)	16.8	31.5	36.6
IL8 (pg/ml)	<10	<10	25.4

Day 0, before infusions of paclitaxel and nedaplatine; day 8, before subcutaneous G-CSF administration; day 16, during the attack. WBC, white blood cells; CRP, C reactive protein; G-CSF, granulocyte colony stimulating factor; IL, interleukin.