

EXTENDED REPORT

Oral pilocarpine for the treatment of ocular symptoms in patients with Sjögren's syndrome: a randomised 12 week controlled study

N Tsifetaki, G Kitsos, C A Paschides, Y Alamanos, V Eftaxias, P V Voulgari, K Psilas, A A Drosos

Ann Rheum Dis 2003;62:1204–1207. doi: 10.1136/ard.2002.003889

Objective: To evaluate the efficacy and side effects of oral pilocarpine for the treatment of ocular symptoms in patients with primary Sjögren's syndrome (SS).

Methods: A 12 week, single centre, randomised controlled study was performed. Twenty nine patients were randomly assigned to receive oral pilocarpine (5 mg twice a day), 28 only artificial tears, and 28 inferior puncta occlusion. Patients receiving oral pilocarpine and those with inferior puncta occlusion also received artificial tears. Patients were evaluated at baseline and throughout the study for their subjective global assessment of dry eyes and for their objective assessment of dry eyes (Schirmer's-I test, rose bengal test, and imprint test).

Results: Patients taking oral pilocarpine had significant improvement in subjective global assessment of dry eyes, as was evaluated by improvement of >55 mm on a visual analogue scale (VAS) for responses to the eye questionnaire, compared with patients treated with artificial tears ($p < 0.001$) and those with inferior puncta occlusion ($p < 0.05$). Furthermore, patients receiving oral pilocarpine also showed greater objective improvement, as measured by the rose bengal test ($p < 0.05$), while Schirmer's-I test showed no differences between the treated groups. Commonly reported adverse events were headache, increased sweating, nausea, and vomiting in the pilocarpine group, while one patient in the inferior puncta occlusion group had blepharitis and was withdrawn from the study.

Conclusion: 10 mg of pilocarpine daily given to patients with SS for 12 weeks had a beneficial effect on subjective eye symptoms, as evaluated by improvement >55 mm on a VAS. Additionally, an improvement of rose bengal staining was noted, but an increase in tear production, as measured by the Schirmer-I test, was not substantiated.

See end of article for authors' affiliations

Correspondence to: Professor A A Drosos, Department of Internal Medicine, Medical School, University of Ioannina, 45110, Ioannina Greece; adrosos@cc.uoi.gr

Accepted 30 March 2003

Sjögren's syndrome (SS) is a chronic autoimmune disease characterised by focal or diffuse lymphocytic infiltration of the exocrine glands, leading to mucosal dryness expressed mainly as dry eyes and dry mouth.^{1,2} The principal ocular complaint is dry eyes with a sandy or gritty feeling under the eyelids. Other symptoms include a burning sensation, decreased tear production, redness, itching, and photosensitivity. These symptoms are attributed to the destruction of corneal and bulbar conjunctival epithelium, defined as keratoconjunctivitis sicca (KCS).^{1,2} Ocular complications are episcleritis, keratitis, bacterial or viral infections, as well as corneal ulcers. Systemic treatment of patients with SS has no beneficial effects on dry eyes. Thus, the mainstay of the treatment of KCS is to replace deficient tears with artificial tears.^{3,4} Other approaches include attempts to decrease the drainage of lachrymal tears through the puncta and nosolachrymal ducts by placing occlusive elements in the inferior or superior puncta, or both.⁵ Recently, it has been suggested that pilocarpine, a cholinergic parasympatheticomimetic agonist given orally, improves sicca symptoms in patients with SS.⁶ In this study we investigated the efficacy and side effects of oral pilocarpine for the ocular symptoms in patients with primary SS.

PATIENTS AND METHODS

Eighty five female patients with SS who fulfilled the preliminary European criteria for SS were included in the study.⁷ The patients were randomly assigned to one of the three treatment groups for a period of 12 weeks. Patients were randomised according to a computer generated schedule. Thus, 29 patients were assigned to receive oral

pilocarpine (5 mg twice a day; Salagen tables, Novartis Pharma Inc), 28 were assigned to be treated with artificial tears only and, finally, 28 patients were assigned to be treated with lachrymal puncta occlusion (fig 1). Patients in the pilocarpine group and those with the lachrymal puncta occlusion also received artificial tears.

There is no single, recognised test for the diagnosis of KCS. Thus, various tests are used in the following order: a dry eyes questionnaire, Schirmer's-I test, the rose bengal test, the break up time test, the fluorophotometer method and, finally, the imprint test. In our study all patients responded to a subjective questionnaire for dry eyes.⁷ Schirmer's-I test without local anaesthesia and rose bengal staining, after slit lamp eye examination, were performed. In addition, conjunctival impression cytology (imprint test) was performed on all patients.⁸ Changes from baseline in ocular symptoms were assessed on a 100 mm visual analogue scale (VAS). The VAS score was defined as an improvement of >55 mm for responses to the eye questionnaire. The clinical examination and the eye questionnaire were done by the same investigator (NT). Eye examination, Schirmer's-I test, and rose bengal staining were all performed by another investigator (GK), who was unaware of the treatment allocation. Furthermore, the imprint test was done by another eye doctor (CAP) who was also unaware of the treatment arms and the results of Schirmer's-I and rose bengal tests. Improvement of the

Abbreviations: KCS, keratoconjunctivitis sicca; SS, Sjögren's syndrome; VAS, visual analogue scale

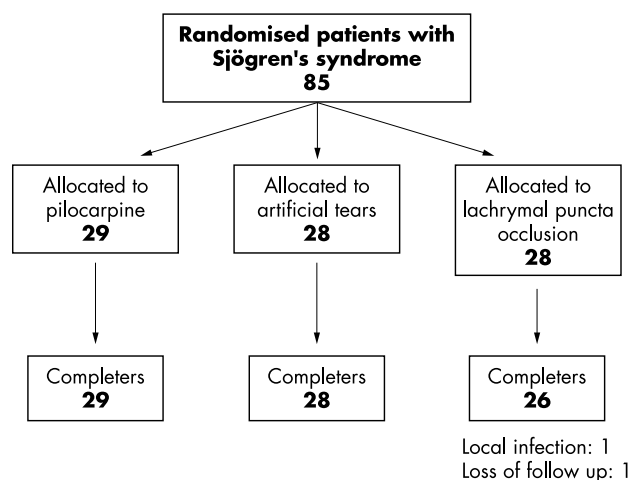


Figure 1 Flow of patients and trial profile.

imprint test was defined as an increase in the cytoplasm/nucleus ratio of the epithelial cells and by the increased number of goblet cells.⁸ The occlusion of the puncta was also performed by the same eye investigator (VE). More specifically, the inferior puncta of both eyes was occluded by the placing of collagen plugs for seven days, followed by permanent collagen plugs for the rest of the treatment (Collagen Plugs, Lacrimedics Inc). The primary efficacy end point was the subjective assessment of a specific questionnaire using a series of VAS. A secondary efficacy end point was the objective measurement of tear flow using Schirmer's-I test. An additional secondary efficacy end point was the objective measurement of the condition of the conjunctival epithelial cells using rose bengal and imprint tests.

Patients were followed up every week for the first month and every month thereafter. The same investigational tests were repeated at the end of the study as an objective measure of treatment efficacy, and patients were also asked to respond to the eye questionnaire for subjective changes in their symptoms. Patients with diabetes mellitus, renal failure, heart and gastrointestinal diseases, multiple sclerosis, and ophthalmological disorders other than SS were excluded from the study.

The estimation of the power of the study was based on a subjective perception of improvement. Preliminary calculations were based on an examination of the first 10 patients

included in each group. Assuming a 90% response rate in the group receiving pilocarpine and a 30% response rate in the group receiving artificial tears, 25 people for each treatment would result in a power of 90% for this comparison.

The subjective perception of improvement was compared between the groups using a two sided χ^2 test, with Yates's correction when appropriate. Differences in the results of the clinical examination were compared among groups using the Kruskal-Wallis test for the overall comparison and the Wilcoxon test for pairwise comparisons.

RESULTS

No significant differences in mean age, mean disease duration, glandular and extraglandular manifestations, or autoantibody profile were found between the three groups (table 1). The subjective ocular improvement was more prominent, with significant difference in the pilocarpine treated group, as compared with the patients treated with artificial tears ($p < 0.001$) and those treated with lachrymal puncta occlusion ($p < 0.05$) (fig 2). For the objective measurement for dry eyes, Schirmer's-I test, no significant difference was found between the three treated groups. Patients treated with pilocarpine had an improvement in the rose bengal test as compared with other treated groups ($p < 0.05$) (table 2).

The wetting of the conjunctival ocular surface, as evaluated by the imprint test, was effective in patients treated with pilocarpine. More specifically, patients treated with pilocarpine presented a decrease in the cytoplasm/nucleus ratio of the epithelial cells and an increase in the number of goblet cells compared with the other treated groups; this was not statistically significant (table 2).

Side effects were as follows: four patients had mild headache, of whom three also presented with nausea, vomiting, and sweating. None of these patients discontinued the study because of side effects. However, one patient of the lachrymal puncta occlusion group discontinued the study because of a local infection of the right eye and one more patient from the same group was lost to follow up (fig 1).

DISCUSSION

SS is a systemic autoimmune exocrinopathy characterised by dysfunction of the lachrymal and salivary glands. This decrease in secretory function leads to the symptoms of dry eyes and dry mouth and the objective findings of KCS and xerostomia. Recent studies support the hypothesis that interaction between immune factors and the neuroendocrine

Table 1 Clinical and laboratory findings of the patients with Sjögren's syndrome

Characteristics	Pilocarpine (n = 29)	Artificial tears (n = 28)	Lachrymal puncta occlusion (n = 28)	p Values
Age (years), mean (SD)	57.0 (11.5)	59.9 (9.9)	57.8 (12.9)	NS
Disease durations (years), mean (SD)	10.5 (6.1)	11.2 (5.0)	10.5 (5.4)	NS
Dry eyes	29 (100)	29 (100)	29 (100)	NS
Dry mouth	24 (83)	25 (86)	26 (90)	NS
Parotid gland enlargement	6 (21)	5 (17)	6 (21)	NS
Extraglandular manifestations* during disease course	7 (24)	6 (21)	6 (21)	NS
Autoantibodies				
IgM RF	12 (48)	14 (48)	15 (52)	NS
ANA	27 (93)	26 (90)	26 (90)	NS
Ro (SS-A)	15 (52)	14 (48)	15 (52)	NS
La (SS-B)	8 (28)	7 (24)	10 (31)	NS
Average focus score (/4 mm ²)	1-8	1-7	1-8	

Results are shown as No (%) unless stated otherwise.

*Extraglandular manifestations = Raynaud's phenomenon, arthralgias or/and arthritis, lymphadenopathy, hepatomegaly.

NS, non-significant; IgM RF, IgM rheumatoid factor; ANA, antinuclear antibodies; Ro (SSA) and La (SSB), antibodies to extractable nuclear antigens.

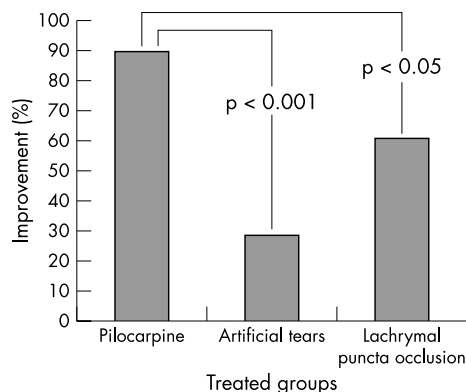


Figure 2 Subjective improvement of ocular symptoms in patients with primary SS.

system may affect the tear producing mechanism of the exocrine glands. Proinflammatory cytokines may be responsible for damaging secretory glands and the presence of autoantibodies may influence the response of the muscarinic M_3 receptors.^{9–10} Thus, the ability to modulate the immune response and stimulate residual glandular elements provides a new therapeutic opportunity for patients with SS. Systemic corticosteroid treatment may increase salivary and tear secretion, but it is associated with significant long term side effects that outweigh its benefit for this purpose.⁴ Systemic agents, including antimalarial drugs,¹¹ cyclosporin A,¹² methotrexate,¹³ and azathioprine,¹⁴ are useful for treating extraglandular manifestations rather than for improving salivary or tear flow rates, in which their effects are minimal. On the other hand, the topical use of cyclosporin A has a beneficial effect on dry eyes in patients with SS, because it significantly reduces the number of activated lymphocytes within the conjunctiva. This compound has been recently approved by the Food and Drug Administration (FDA) of the United States to be used topically in patients with KCS.^{15–16} In addition, oral interferon alfa seems promising for the treatment of dry eyes and mouth in patients with SS.¹⁷

Management of dry eyes encompasses three basic strategies: (a) conservation of the available tears; (b) replacement with artificial tears; and (c) stimulating the production of tears. Methods of conserving tears include the use of moisture chamber panels and glasses, both of which shield the eye from wind currents and decrease tear evaporation, and the occlusion of the puncta of the lower canaliculus with silicone plugs.^{5–18} Stimulation of the production of tears by M_3

receptor agonists like pilocarpine and cevimeline may be effective.^{18–19}

Pilocarpine is a cholinergic parasympathomimetic agonist that binds to M_3 receptors and can cause pharmacological stimulation of exocrine glands. It is through stimulation of exocrine secretions that pilocarpine products increase salivary and lachrymal responses, which may, in turn, alleviate symptoms of dry mouth and dry eyes.^{18–19} Pilocarpine hydrochloride has been shown to be effective and safe for the treatment of xerostomia resulting from radiation damage to salivary glands.^{20–23} Double blind studies have shown that oral pilocarpine and oral cevimeline^{20–24} have a beneficial effect on a dry mouth, and thus both drugs are approved by the FDA for the treatment of xerostomia. However, the efficacy of both muscarinic agonists was minimal in the treatment of dry eyes.^{18–23–24}

For this reason we performed the present randomised controlled study comparing patients with SS who received small doses of oral pilocarpine, with patients treated with artificial tears only and those in whom the inferior puncta was occluded. We found a better subjective eye improvement in the patients treated with pilocarpine than in those treated with artificial tears and those in whom the inferior puncta was occluded. This subjective improvement was associated with the objective findings, as evaluated by improvement of the rose bengal test in patients treated with oral pilocarpine. No improvement in the Schirmer's-I test was found. It is reported that Schirmer's-I test may be influenced by many factors such as patients' hydration status, body and room temperature, the climate, the menstrual cycle in women, and others. Therefore, it is believed that Schirmer's-I test is less sensitive than the rose bengal test.¹

Pilocarpine treatment in patients with SS usually starts with 5 mg at night for a few days, then 5 mg twice daily, morning and night for a week, and then, if the patient does not respond, the dose is increased to 15 or 20 mg a day. This is done specifically to help avoid sweating and other side effects. In some cases (10%) the dose is increased to 30 mg a day.²³ In this study we used oral pilocarpine 5 mg twice daily in order, firstly, to avoid side effects because some side effects are dose dependent, and, secondly, to encourage better compliance of the patients because many patients with SS may take multiple drugs such as non-steroidal anti-inflammatory drugs, proton pump inhibitors, and calcium supplements.

In conclusion, according to our results, oral pilocarpine seems to have a beneficial effect on subjective eye symptoms, as was evaluated by an improvement of >55 mm on the VAS for responses to the eye questionnaire and by improvement of

Table 2 Objective changes of ocular features in the patients with Sjögren's syndrome

Variables	Pilocarpine		Artificial tears		Lachrymal puncta occlusion	
	Baseline	Difference	Baseline	Difference	Baseline	Difference
Schirmer-I (<5 mm/5 min)						
RE	4.5 (2.2)	0.3 (1.1)	5.1 (1.0)	0.2 (0.8)	5.0 (1.0)	0.2 (0.4)
LE	4.4 (1.9)	1.2 (1.3)	4.3 (1.2)	0.6 (0.9)	4.5 (0.9)	0.7 (0.8)
Rose bengal (<4 Bijsterveld's score)						
RE	4.6 (1.9)	-1 (1.3)*	4.2 (2.0)	0.0 (0.5)	4.6 (2.3)	-0.9 (1.2)
LE	4.7 (2.2)	-1.1 (1.0)*	4.2 (1.9)	0.0 (0.7)	4.5 (1.9)	-0.5 (0.9)
C/N ratio (3–4:1)						
RE	4.0 (0.9)	-0.1 (1.3)	3.7 (1.0)	0.0 (1.0)	3.6 (0.8)	0.2 (0.9)
LE	4.0 (1.1)	-0.1 (1.2)	3.6 (0.8)	0.1 (0.9)	3.5 (0.8)	0.1 (0.8)
Goblet cells (n) 100–300/mm ²						
RE	53.1 (42.7)	46.6 (187.2)	90.5 (164.0)	-43.5 (181.9)	92.4 (173.6)	2.5 (188.5)
LE	74.9 (68.7)	6.2 (133.9)	65.9 (116.8)	-23.3 (131.3)	64.6 (125.5)	18.2 (131.7)

Results are shown as mean (SD).

RE, right eye; LE, left eye; C/N, cytoplasm/nucleus ratio of epithelial cells.

* $p < 0.05$ in favour of pilocarpine in comparison with other treated groups.

the rose bengal test. Large multicentre studies with a large number of patients are needed to validate our results.

ACKNOWLEDGEMENTS

We thank Mrs Eleni Horti for her secretarial assistance.

Authors' affiliations

N Tsifetaki, P V Voulgari, A A Drosos, Rheumatology Clinic, Department of Internal Medicine, Medical School, University of Ioannina, Ioannina, Greece

G Kitsos, C A Paschides, V Eftaxias, K Psilas, Department of Ophthalmology, Medical School, University of Ioannina, Ioannina, Greece

Y Alamanos, Department of Hygiene and Epidemiology, Medical School, University of Ioannina, Ioannina, Greece

REFERENCES

- 1 **Talal N**, Moutsopoulos HM, Kassan SS, eds. *Sjögren's syndrome: clinical and immunological aspects*. Berlin: Springer, 1987.
- 2 **Moutsopoulos HM**. Sjögren's syndrome: autoimmune epithelitis. *Clin Immunol Immunopathol* 1994;**72**:162–5.
- 3 **Bell M**, Askari A, Bookman A, Frydrych S, Lamont J, McComb J, et al. Sjögren's syndrome: a critical review of clinical management. *J Rheumatol* 1999;**26**:2051–61.
- 4 **Fox R**. Treatment of Sjögren's syndrome. In: Weinblatt ME, ed. *Therapy of rheumatoid disease*. Philadelphia: Saunders, 1999:66–77.
- 5 **Balaram M**, Schaumberg DA, Dana MR. Efficacy and tolerability outcomes after punctal occlusion with silicone plugs in dry eye syndrome. *Am J Ophthalmol* 2001;**131**:30–6.
- 6 **Wiseman LR**, Faulds D. Oral pilocarpine: a review of its pharmacological properties and clinical potential in xerostomia. *Drugs* 1995;**49**:143–55.
- 7 **Vitali C**, Bombardieri S, Jonsson R, Moutsopoulos HM, Alexander EL, Carsons SE, et al. Classification criteria for Sjögren's syndrome: a revised version of the European criteria proposed by the American-European Consensus Group. *Ann Rheum Dis* 2002;**61**:554–8.
- 8 **de Rojas MV**, Rodriguez MT, Ces Blanco JA, Salorio MS. Impression cytology in patients with keratoconjunctivitis sicca. *Cytopathology* 1993;**4**:347–55.
- 9 **Waterman SA**, Gordon TP, Rischmueller M. Inhibitory effects of muscarinic receptor autoantibodies on parasympathetic neurotransmission in Sjögren's syndrome. *Arthritis Rheum* 2000;**43**:1647–54.
- 10 **Fox RI**, Stern M. Sjögren's syndrome: mechanisms of pathogenesis involve interaction of immune and neurosecretory systems. *Scand J Rheumatol Suppl* 2002;**116**:3–13.
- 11 **Fox RI**, Chan E, Benton L, Fong S, Friedlaender M, Howell FV. Treatment for primary Sjögren's syndrome with hydroxychloroquine. *Am J Med* 1988;**85**:62–7.
- 12 **Drosos AA**, Skopouli FN, Costopoulos JS, Papadimitriou CS, Moutsopoulos HM. Cyclosporin A (CyA) in primary Sjögren's syndrome: a double blind study. *Ann Rheum Dis* 1986;**45**:732–5.
- 13 **Skopouli FN**, Jagiello P, Tsifetaki N, Moutsopoulos HM. Methotrexate in primary Sjögren's syndrome. *Clin Exp Rheumatol* 1996;**14**:555–8.
- 14 **Price EJ**, Rigby SP, Clancy U, Venables PJ. A double blind placebo controlled trial of azathioprine in the treatment of primary Sjögren's syndrome. *J Rheumatol* 1998;**25**:896–9.
- 15 **Hingorani M**, Moodaley L, Calder VL, Buckley RJ, Lightman S. A randomized, placebo-controlled trial of topical cyclosporin A in steroid-dependent atopic keratoconjunctivitis. *Ophthalmology* 1998;**105**:1715–20.
- 16 **Kunert KS**, Tisdale AS, Stern ME, Smith JA, Gipson IK. Analysis of topical cyclosporine treatment of patients with dry eye syndrome: effect on conjunctival lymphocytes. *Arch Ophthalmol* 2000;**118**:1489–96.
- 17 **Ship JA**, Fox PC, Michalek JE, Cummins MJ, Richards AB. Treatment of primary Sjögren's syndrome with low-dose natural human interferon-alpha administered by the oral mucosal route: a phase II clinical trial. IFN Protocol Study Group. *J Interferon Cytokine Res* 1999;**19**:943–51.
- 18 **Fox RI**, Stern M, Michelson P. Update in Sjögren's syndrome. *Curr Opin Rheumatol* 2000;**12**:391–8.
- 19 **Masunaga H**, Ogawa H, Uematsu Y, Tomizuka T, Yasuda H, Takeshita Y. Long-lasting salivation induced by a novel muscarinic receptor agonist SN-2011 in rats and dogs. *Eur J Pharmacol* 1997;**339**:1–9.
- 20 **Vivino FB**, Al-Hashimi I, Khan Z, LeVeque FG, Salisbury PL 3rd, Tran-Johnson TK, et al. Pilocarpine tablets for the treatment of dry mouth and dry eye symptoms in patients with Sjögren's syndrome: a randomized placebo-controlled, fixed-dose, multicenter trial. P92-01 Study Group. *Arch Intern Med* 1999;**159**:174–81.
- 21 **Fox PC**, Mandel ID. Effects of pilocarpine on salivary flow in patients with Sjögren's syndrome. *Oral Surg Oral Med Oral Pathol* 1992;**74**:315–18.
- 22 **Rhodus NL**. Oral pilocarpine HCl stimulates labial (minor) salivary gland flow in patients with Sjögren's syndrome. *Oral Dis* 1997;**3**:93–8.
- 23 **Vivino FB**. The treatment of Sjögren's syndrome patients with pilocarpine tablets. *Scand J Rheumatol* 2001;**30**(suppl 115):1–13.
- 24 **Petrone D**, Condemi JJ, Fife R, Gluck O, Cohen S, Dalgin P. A double-blind randomized, placebo-controlled study of cevimeline in Sjögren's syndrome patients with xerostomia and keratoconjunctivitis sicca. *Arthritis Rheum* 2002;**46**:748–54.

ECHO

Secondary Raynaud's syndrome following radiotherapy



Please visit the *Annals of the Rheumatic Diseases* website [www.annrheumdis.com] for a link to the full text of this article.

Two patients with pre-existing primary Raynaud's phenomenon of the hands developed secondary Raynaud's of the tongue and lip respectively after treatment with radiotherapy for malignancy.

A 69 year old man received 56.7 Gy in 36 fractions to his tongue and deep cervical nodes to treat a poorly differentiated squamous cell carcinoma. Twenty-two months later he developed tingling, then pain over the posterior part of his tongue when inhaling cold air. Colour Doppler ultrasound of the tongue while sucking ice failed to show any change, perhaps because the posterior third of the tongue was not sufficiently cooled. His symptoms remained stable over two years and he developed no other sequela of late tissue radiation injury.

A 48 year old woman received 40.5 Gy in 9 fractions over 11 days to treat a basal cell carcinoma of the upper lip. Thirteen months later she noticed tingling and a blue discoloration precisely located over the irradiated area provoked by cold. A few minutes later the area would become bright red and painful.

No previous report could be found of Raynaud's phenomenon secondary to radiotherapy. It is likely that it is caused by a combination of large vessel narrowing and capillary obliteration provoking tissue hypoxia and an increased vascular contractile response. Also irradiation injury to endothelial cells may alter their functional capacity.

▲ *Postgraduate Medical Journal* 2003;**79**:176–177.