

CONCISE REPORT

Antiphospholipid antibody in localised scleroderma

S Sato, M Fujimoto, M Hasegawa, K Takehara

Ann Rheum Dis 2003;62:771-774

Objective: To investigate the prevalence and clinical correlation of antiphospholipid antibodies in localised scleroderma.

Methods: Antibodies against cardiolipin (aCL) or β_2 -glycoprotein I were examined by enzyme linked immunosorbent assay (ELISA) in 48 patients with localised scleroderma (18 patients with generalised morphoea, 20 with linear scleroderma, and 10 with morphoea). Twenty one of these patients were investigated for lupus anticoagulant (LAC) by screening and confirmatory coagulation tests.

Results: Patients with generalised morphoea, the severest form of localised scleroderma, had significantly raised levels of IgM or IgG aCL relative to normal controls (n=21) and patients with systemic sclerosis (n=20). The IgM isotype was predominant, with the frequency of IgM aCL (61%) higher than that of IgG aCL (28%). Levels of aCL were similar for patients with linear scleroderma or morphoea and normal controls. IgM aCL were associated with a greater number of lesions, especially plaque lesions, wider distribution of lesions, and the presence of immunological abnormalities including antinuclear antibodies, rheumatoid factor, IgM antihistone antibodies, IgG anti-single stranded DNA antibodies, and raised serum interleukin 6 levels in patients with localised scleroderma. LAC was detected in 5/7 (71%) patients with generalised morphoea. However, pulmonary embolism was seen in only one patient with generalised morphoea. None of patients with localised scleroderma exhibited anti- β_2 -glycoprotein I antibodies.

Conclusions: These results suggest that aCL and LAC are the major autoantibodies in patients with generalised morphoea.

Localised scleroderma is a connective tissue disorder that is limited to the skin and the subcutaneous tissues beneath the cutaneous lesions. This disease differs from systemic sclerosis (SSc) in that it is not accompanied by Raynaud's phenomenon, acrosclerosis, and internal organ involvement. Morphologically, localised scleroderma is classified into three variants: morphoea, linear scleroderma, and generalised morphoea.¹

Localised scleroderma is generally considered to have an autoimmune background because it is accompanied by various immunological abnormalities, such as antinuclear antibodies (ANA), anti-single stranded DNA (anti-ssDNA) antibodies, rheumatoid factor (RF), and lupus erythematosus cell phenomenon.² Major antigens recognised by the ANA of patients with localised scleroderma are histones (especially, histones H1, H2A, and H2B).^{2,3}

Antiphospholipid antibodies (aPL) are detected in a variety of autoimmune disorders, including systemic lupus erythematosus, in infectious diseases, in patients receiving drugs, such as procainamide and chlorpromazine, and as an idiopathic

phenomenon.⁴⁻⁶ In this study we investigated whether aPL were detected in patients with localised scleroderma.

PATIENTS AND METHODS

Patients and controls

Serum samples from 48 patients with localised scleroderma (35 women, 13 men; mean (SD) age 26 (18) years; mean (SD) duration 4.5 (6.6) years) were studied. They were classified into 18 patients with generalised morphoea (13 women, 5 men; age 22 (18); duration 2.9 (2.5)), 20 with linear scleroderma (15 women, 5 men; age 21 (13); duration 6.3 (8.9)), and 10 with morphoea (7 women, 3 men; age 42 (16); duration 4.1 (6.3)).¹ Of the 48 patients with localised scleroderma, lupus anticoagulant (LAC) was investigated in 21 patients (12 women, 9 men; age 21 (15); duration 3.1 (3.0)) whose plasma samples were available: 7 patients with generalised morphoea (4 women, 3 men; age 14 (12); duration 2.2 (2.0)), 9 with linear scleroderma (5 women, 4 men; age 16 (9); duration 4.8 (3.2)), and 5 with morphoea (3 women, 2 men; age 39 (14); duration 1.1 (1.9)). Twenty patients with SSc (15 women, 5 men; age 29 (22); duration 5.4 (7.3)), who fulfilled the criteria of the American College of Rheumatology for scleroderma, served as controls⁷; they were classified into 10 patients with limited cutaneous SSc (8 women, 2 men; age 31 (26); duration 7.1 (9.6)) and 10 with diffuse cutaneous SSc (7 women, 3 men; age 27 (20); duration 3.6 (3.8)).⁸ Twenty one healthy volunteers (15 women, 6 men; age 28 (15)) served as normal controls. None of the patients and healthy controls had thyroid or liver diseases, concurrent drug ingestion, a recent history of infection, or a history of birth control.

The number of sclerotic lesions more than 3 cm in diameter was counted.¹ We divided the body into the following seven areas: head and neck; right upper extremity; left upper extremity; anterior trunk; posterior trunk; right lower extremity; and left lower extremity, then we counted the number of affected areas.¹ The protocol was approved by the Kanazawa University Graduate School of Medical Science and Kanazawa University Hospital.

Detection of autoantibodies and interleukin (IL)6

Anticardiolipin antibodies (aCL) were measured with an enzyme linked immunosorbent assay (ELISA; Medical and Biological Laboratories, Nagoya, Japan). β_2 -Glycoprotein I (β_2 GPI) antibodies were also examined with an ELISA (Yamasa, Tokyo, Japan). LAC was determined according to the guidelines recommended by the Subcommittee on Lupus Anticoagulant/Phospholipid Dependent Antibodies.⁹ ANA, antihistone antibodies (AHA), anti-ssDNA, and RF were detected as described previously.² Serum IL6 levels were measured with an ELISA kit (R&D systems, Minneapolis, MN, USA).

Abbreviations: aCL, anticardiolipin antibodies; AHA, antihistone antibodies; ANA, antinuclear antibodies; aPL, antiphospholipid antibodies; β_2 GPI, β_2 -glycoprotein I; ELISA, enzyme linked immunosorbent assay; IL, interleukin; LAC, lupus anticoagulant; RF, rheumatoid factor; SSc, systemic sclerosis; ssDNA, single stranded DNA

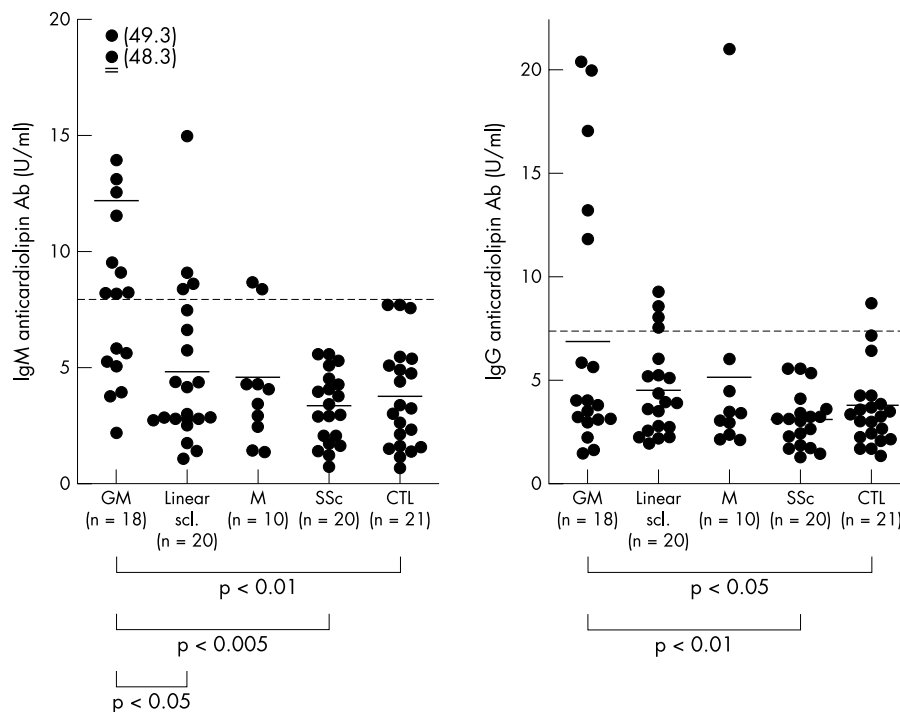


Figure 1 Levels of IgM and IgG aCL determined by ELISA in sera from patients with localised scleroderma. Localised scleroderma was classified into generalised morphoea (GM), linear scleroderma (linear scl.), and morphoea (M). Patients with SSc and normal controls (CTL) were used as controls. The horizontal lines indicate the mean value for each group. The broken line indicates the mean + 2SD of normal controls.

Statistical analysis

Statistical analysis was performed with the Mann-Whitney U test, Bonferroni's test, and Spearman's rank correlation coefficient.

RESULTS

Levels of aCL

IgM and IgG aCL levels tended to be higher in patients with localised scleroderma than in normal controls ($p=0.068$ and $p=0.077$, respectively). Patients with generalised morphoea had significantly raised levels of IgM and IgG aCL relative to normal controls and patients with SSc (fig 1). Patients with generalised morphoea showed significantly raised IgM, but not IgG, aCL levels compared with patients with linear scleroderma. IgM or IgG aCL levels in patients with linear scleroderma, morphoea, or SSc were similar to those in normal controls.

None of patients with localised scleroderma or SSc exhibited IgM or IgG β_2 GPI antibodies and a biological false positive serological test for syphilis (data not shown).

Prevalence of aCL and LAC

When the cut off value was set as the mean + 2SD for normal binding, IgM and/or IgG aCL were positive in 46% of patients with localised scleroderma, with 67% in generalised morphoea, 35% in linear scleroderma, and 30% in morphoea (table 1). None of patients with SSc had aCL. In generalised morphoea, the frequency of IgM aCL (61%) was higher than that of IgG aCL (28%).

IgG and/or IgM AHA were detected in 58% of patients with localised scleroderma, with 89% in generalised morphoea and 40% in linear scleroderma or morphoea, while 20% of patients with SSc were positive for AHA.

LAC activity was determined in 21 patients with localised scleroderma whose plasma samples were available. It was detected in five (24%) patients with localised scleroderma; all five patients had generalised morphoea. Thus, LAC was positive in 71% (5/7) of patients with generalised morphoea. Of the five patients positive for LAC, three patients had both IgM and IgG aCL, one had highest levels (49.3 U/ml) of IgM aCL alone, and one had IgG aCL alone.

Table 1 Frequency of aCL, LAC, and AHA in patients with localised scleroderma (Scl), those with SSc, and normal controls

| | Anticardiolipin antibodies | | | LAC* | AHA | | |
|---------------------------|----------------------------|---------|------------|-----------|---------|---------|------------|
| | IgM | IgG | IgM or IgG | | IgM | IgG | IgM or IgG |
| Localised Scl (n=48) | 17 (35) | 10 (21) | 22 (46) | 5/21 (24) | 22 (46) | 21 (44) | 28 (58) |
| GM (n=18) | 11 (61) | 5 (28) | 12 (67) | 5/7 (71) | 13 (72) | 14 (78) | 16 (89) |
| Linear scleroderma (n=20) | 4 (20) | 4 (20) | 7 (35) | 0/9 | 6 (30) | 5 (25) | 8 (40) |
| Morphoea (n=10) | 2 (20) | 1 (10) | 3 (30) | 0/5 | 3 (30) | 2 (20) | 4 (40) |
| SSc (n=20) | 0 | 0 | 0 | 0/20 | 2 (10) | 3 (15) | 4 (20) |
| Control (n=21) | 0 | 1 (5) | 1 (5) | 0/21 | 0 | 0 | 0 |

Values are the number (%) of patients.

GM, generalised morphoea.

*Of 48 patients with localised Scl examined for aCL, 21 patients whose serum samples were available were determined for LAC activity.

Table 2 Clinical and serological features of patients with localised scleroderma positive for IgM aCL

| | IgM aCL (+) (n=17) | IgM aCL (-) (n=31) |
|------------------------------|--------------------|--------------------|
| Clinical | | |
| Sex (M/F) | 5/12 | 8/23 |
| Age at onset (years) | 21 (17) | 21 (16) |
| Disease duration (years) | 3.2 (4.5) | 5.3 (7.6) |
| No of linear lesions | 1.4 (1.3) | 1.0 (0.9) |
| No of plaque lesions | 5.0 (3.6)** | 1.9 (2.5) |
| Total No of lesions | 6.4 (4.2)** | 2.9 (2.9) |
| No of body areas affected | 3.4 (2.1)* | 2.0 (1.7) |
| Bilateral distribution (%) | 13 (76)** | 8 (26) |
| Muscle involvement (%) | 5 (29) | 5 (16) |
| Serological | | |
| ANA (%) | 15 (88)* | 16 (52) |
| IgM AHA (relative OD) | 0.81 (0.20)** | 0.51 (0.22) |
| IgG AHA (relative OD) | 0.89 (0.23) | 0.74 (0.29) |
| IgG anti-ssDNA (relative OD) | 0.68 (0.28)** | 0.49 (0.18) |
| IgM RF (%) | 10 (59)* | 8 (26) |
| IL6 (pg/ml) | 32.8 (24.5)* | 12.3 (6.9) |

Unless otherwise indicated, values are means (SD).
* $p < 0.05$ and ** $p < 0.01$ v patients without IgM aCL.

The five patients with generalised morphoea positive for LAC and aCL were screened for clinical signs associated with aPL by magnetic resonance imaging scans, ventilation/perfusion pulmonary scintigraphy, electrocardiogram, echocardiogram, and phlebography. Despite the absence of symptoms suggestive for pulmonary embolism, ventilation/perfusion pulmonary scintigraphy disclosed pulmonary embolism of both lungs in one patient with generalised morphoea positive for LAC as well as IgM and IgG aCL. This patient did not have any other risk factors, such as contraceptive use. The remaining four patients with LAC and aCL did not have any evidences of thrombosis. None of the other patients with localised scleroderma with aCL had a history of recurrent miscarriages, thrombocytopenia, and thromboembolic events according to their clinical record. In contrast, LAC was absent in patients with SSc and normal controls.

Correlation of aCL with clinical and immunological features

Patients with localised scleroderma with IgM aCL exhibited significantly higher total number of lesions, number of plaque lesions, number of body areas affected, frequency of bilateral distribution of lesions, frequency of ANA and RF positivity, levels of IgM AHA, IgG anti-ssDNA, and serum IL6 than those without IgM aCL (table 2). Consistently, IgM aCL levels correlated positively with the total number of lesions ($r_s = 0.58$, $p < 0.0001$), number of plaque lesions ($r_s = 0.54$, $p < 0.0005$), and number of affected body areas ($r_s = 0.51$, $p < 0.001$). By contrast, IgG aCL and LAC did not correlate with any clinical and immunological features (data not shown).

DISCUSSION

In this study patients with localised scleroderma exhibited aCL (46%) and LAC (24%) while β_2 GPI antibodies were not detected. In particular, about 70% of patients with generalised morphoea had aCL and LAC. The predominant isotype of aCL was IgM in patients with generalised morphoea. By contrast, no patients with SSc had aCL and LAC. Consistently, a previous study reported that the prevalence of aCL was low (12%) in 476 patients with SSc.¹⁰ Another study reported that LAC was not detected in 24 patients with SSc.¹¹ Therefore, the results indicate that aCL and LAC are some of the major autoantibodies in generalised morphoea.

Generalised morphoea and drug induced lupus share many immunological characteristics. AHA are present in >85% of both disorders.²⁻¹² Anti-ssDNA are also detected in 70–80% of

both disorders, but anti-dsDNA were absent.²⁻¹² LAC and aCL are detected in drug induced lupus or patients without lupus syndrome who have received drugs, including procainamide and chlorpromazine.^{4-6 13 14} The major isotype of this drug induced aCL is IgM and the prevalence of thrombotic episodes is relatively low (0–26%).^{4-6 14} Similarly, patients with generalised morphoea had predominantly IgM aCL and LAC. Furthermore, pulmonary embolism was seen in only one patient with generalised morphoea. Thus, these results indicate that aCL and LAC are also major characteristics of the immunological abnormalities seen in both generalised morphoea and drug induced lupus, suggesting that autoimmunity may be environmentally driven in generalised morphoea.

Despite the high prevalence of aCL and LAC in generalised morphoea, thrombosis was detected in only one patient with generalised morphoea. This low prevalence of thrombotic events may be related to the finding that the major isotype of aCL was IgM because the IgG response has a stronger relationship with the clinical features.⁷ In addition, the absence of anti- β_2 GPI in patients with localised scleroderma may be relevant because anti- β_2 GPI are associated more strongly with a history of thrombosis than aCL.⁴ However, it should be noted that one patient with generalised morphoea developed pulmonary embolism despite a good prognosis of generalised morphoea. Moreover, IgM aCL have been reported to be associated with deep vein thrombosis.¹⁵ Therefore, careful observation and follow up for thrombosis should be required for patients with generalised morphoea with aCL or LAC.

ACKNOWLEDGEMENT

We thank Ms M Matsubara for technical assistance.

Authors' affiliations

S Sato, M Hasegawa, K Takehara, Department of Dermatology, Kanazawa University Graduate School of Medical Science, Kanazawa, Japan

M Fujimoto, Department of Regenerative Medicine, Research Institute, International Medical Centre of Japan, Tokyo, Japan

Correspondence to: Dr S Sato, Department of Dermatology, Kanazawa University Graduate School of Medical Science, 13-1 Takaramachi, Kanazawa, Ishikawa 920-8641, Japan; s-sato@med.kanazawa-u.ac.jp

Accepted 21 January 2003

REFERENCES

- 1 **Sato S**, Fujimoto M, Ihn H, Kikuchi K, Takehara K. Clinical characteristics associated with antihistone antibodies in patients with localized scleroderma. *J Am Acad Dermatol* 1994;31:567-71.
- 2 **Sato S**, Ihn H, Soma Y, Igarashi A, Tamaki T, Kikuchi K, et al. Antihistone antibodies in patients with localized scleroderma. *Arthritis Rheum* 1993;36:1137-41.
- 3 **Sato S**, Fujimoto M, Ihn H, Kikuchi K, Takehara K. Antigen specificity of antihistone antibodies in localized scleroderma. *Arch Dermatol* 1994;130:1273-7.
- 4 **Merrill JT**, Shen C, Gugnani M, Lahita RG, Mongey AB. High prevalence of antiphospholipid antibodies in patients taking procainamide. *J Rheumatol* 1997;24:1083-8.
- 5 **Hess EV**. Is there a phospholipid specificity of lupus anticoagulants (LAC) in patients with autoimmune and drug induced LAC? *J Rheumatol* 1998;25:200-2.
- 6 **Canoso RT**, de Oliveira RM. Chlorpromazine-induced anticardiolipin antibodies and lupus anticoagulant: absence of thrombosis. *Am J Hematol* 1988;27:272-5.
- 7 **ARA**. Subcommittee for Scleroderma Criteria of the American Rheumatism Association Diagnostic and Therapeutic Criteria Committee. Preliminary criteria for the classification of systemic sclerosis (scleroderma). *Arthritis Rheum* 1980;23:581-90.
- 8 **LeRoy EC**, Black C, Fleischmajer R, Jablonska S, Krieg T, Medsger Jr TA, et al. Scleroderma (systemic sclerosis): classification, subsets and pathogenesis. *J Rheumatol* 1988;15:202-5.
- 9 **Brandt JT**, Triplett DA, Alving B, Scharrer I. Criteria for the diagnosis of lupus anticoagulants: an update. On behalf of the Subcommittee on Lupus Anticoagulant/Antiphospholipid Antibody of the Scientific and Standardisation Committee of the ISTH. *Thromb Haemost* 1995;74:1185-90.
- 10 **Renaudineau Y**, Grunebaum E, Krause I, Praprotnik S, Revelen R, Youinou P, et al. Anti-endothelial cell antibodies (AECA) in systemic sclerosis- increased sensitivity using different endothelial cell substrates and association with other autoantibodies. *Autoimmunity* 2001;33:171-9.
- 11 **Rowell NR**, Tate GM. Failure to demonstrate the lupus anticoagulant in systemic sclerosis. *Br J Dermatol* 1988;119:549.
- 12 **Tan EM**. Antinuclear antibodies: diagnostic markers for autoimmune diseases and probes for cell biology. *Adv Immunol* 1989;44:93-151.
- 13 **Gastineau DA**, Holcomb GR. Lupus anticoagulant in drug-induced systemic lupus erythematosus (SLE). *Arch Intern Med* 1985;145:1926-7.
- 14 **Drouvalakis KA**, Buchanan RR. Phospholipid specificity of autoimmune and drug induced lupus anticoagulants; association of phosphatidylethanolamine reactivity with thrombosis in autoimmune disease. *J Rheumatol* 1998;25:290-5.
- 15 **Oger E**, Lerny C, Dueymes M, Le Moigne E, Bressolette L, Escoffre M, et al. Association between IgM anticardiolipin antibodies and deep venous thrombosis in patients without systemic lupus erythematosus. *Lupus* 1997;6:455-61.



Have your say

eLetters

If you wish to comment on any article published in *Annals of the Rheumatic Diseases* you can send an eLetter using the eLetters link at the beginning of each article. Your response will be posted on *Annals of the Rheumatic Diseases* online within a few days of receipt (subject to editorial screening).

www.annrheumdis.com