

## LETTERS

# Extended colonic ulcerations in a patient with microscopic polyangiitis

C-N Tsai, C-M Chang, C-H Chuang, Y-T Jin, M-F Liu, C-R Wang

*Ann Rheum Dis* 2004;**63**:1521–1522. doi: 10.1136/ard.2003.018580

Microscopic polyangiitis is a necrotising vasculitis primarily affecting small vessels, with few or no immune deposits. Patients are characterised by positive antineutrophil cytoplasmic antibodies (ANCA), mainly perinuclear pattern. The spectrum of clinical manifestations is broad, including the kidney, musculoskeletal system, lung, gastrointestinal tract, skin, ear, nose, and throat, and neurological system.<sup>1</sup> Although gastrointestinal disease is noted in half of the patients, the presentation is usually mild.<sup>2</sup> Here, we report a patient with microscopic polyangiitis with initial presentation of extended colonic ulcerations and haemorrhage, characterised by a crypt abscess. To our knowledge, such a finding has not been reported previously.

## CASE REPORT

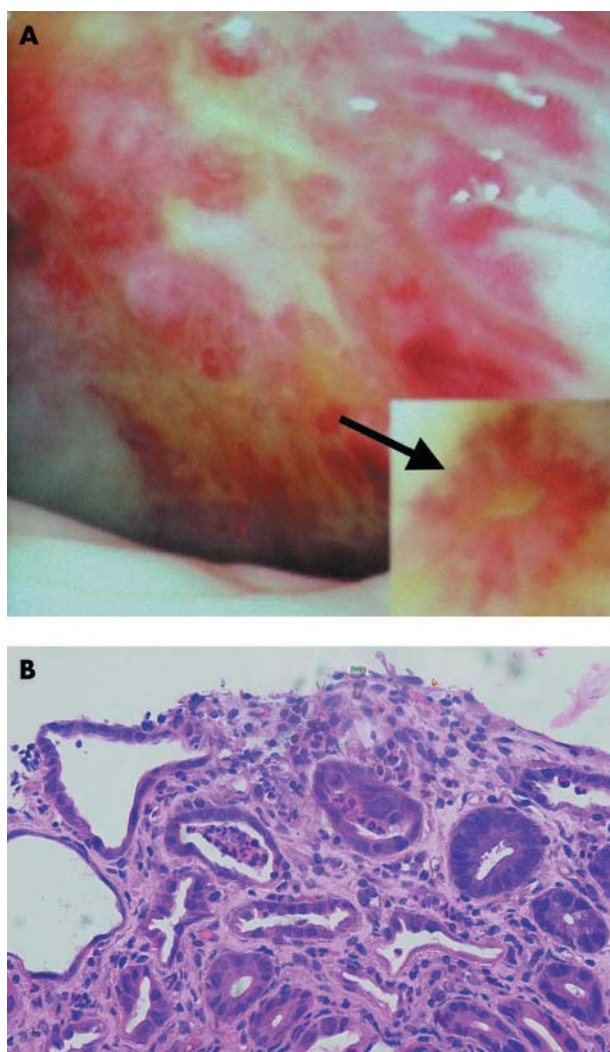
A 69 year old man was admitted to hospital owing to leg oedema and body weight loss in the past 3 months. No systemic disease had previously been noted. He had a poor appetite and abdominal discomfort, but denied bowel habit changes, bloody or tarry stool.

On examination, vital signs were stable. Pale conjunctiva, mild abdominal tenderness, and pitting oedema over the legs were noted. Laboratory tests showed leucocytes  $11.9 \times 10^9/l$ , haemoglobin 67 g/l, albumin 225  $\mu\text{mol/l}$ , C reactive protein 1157 mg/l, and erythrocyte sedimentation rate more than 150 mm/1st h. Daily urinary protein loss was 0.7 g. Stool examination showed positive occult blood. However, the results of panendoscopy and lower gastrointestinal investigations were negative.

Intermittent high fever was noted several days after admission. No infectious focus was identified by repeated blood and stool cultures. Abdominal computed tomography disclosed mild inflammation over the mesentery. Colonoscopy showed markedly swelling mucosa with haemorrhage and ulcers from rectum to the cecum (fig 1A). A pathology examination reported inflammatory infiltrates in the lamina propria, destruction of the mucosal gland, and a crypt abscess (fig 1B). Ulcerative colitis was diagnosed, and mesalazine and prednisolone 30 mg every day were prescribed.

Sudden onset of haemoptysis occurred 1 week later and pulmonary haemorrhage was diagnosed. Intravenous methylprednisolone 20 mg every 8 hours was given, and the haemoptysis disappeared 1 week later. Repeated urinary analysis showed a daily protein loss of 4 g. An autoantibody examination showed negative antinuclear antibodies and antiglomerular basement membrane antibody. ANCA were positive (perinuclear pattern,  $\times 320$ ), and further analysis showed positive antimyeloperoxidase 103 U/ml (normal range  $<20$  U/ml). A renal biopsy showed glomerular necrosis, cellular crescent, interlobular arteritis, diffuse tubular atrophy, and few immune deposits. The final diagnosis was microscopic polyangiitis with a rare presentation of extended colonic ulcerations. Pulse intravenous cyclophosphamide

700 mg was given and steroid was gradually tapered. Proteinuria, hypoalbuminaemia, anaemia and inflammatory measures improved with treatment. He was discharged and received monthly pulse cyclophosphamide treatment thereafter. Neither abdominal pain nor diarrhoea was noted during follow up at the outpatient clinic.



**Figure 1** (A) The mucosa of the sigmoid colon was hyperaemic, oedematous, and markedly uneven, with multiple ulcers and haemorrhage. The ulcers were irregular in shape and varied in size. Some cotton wool-like vascular pattern (arrow) was also noted in the surrounding mucosa. (B) Colonic biopsy specimen showing inflammatory cell infiltrating the lamina propria, destruction of the mucosal gland, and marked crypt abscess (haematoxylin and eosin,  $\times 200$ )

## DISCUSSION

In microscopic polyangiitis, necrotising glomerulonephritis is the most common abnormality and pulmonary capillaritis often occurs. Perinuclear ANCA are present in more than 60% of patients, and antimyeloperoxidase antibody is closely allied.<sup>1</sup> Gastrointestinal involvement is usually mild and there is no report of extended colonic ulcerations and haemorrhage.<sup>2</sup> In addition, colonic biopsy disclosed crypt abscess, which can be found in ulcerative colitis, infectious colitis, radiation induced colitis, and graft versus host disease.<sup>3-5</sup> However, such a finding has not been reported previously in patients with microscopic polyangiitis. Ulcerative colitis was diagnosed initially according to the colonoscopic and pathological findings. Pulmonary vasculitis is very rare in patients with inflammatory bowel diseases.<sup>6</sup> Renal disease with necrotising glomerulonephritis is not commonly seen in patients with ulcerative colitis.<sup>7</sup> In addition, antimyeloperoxidase antibody is usually not detected in such patients.<sup>8</sup> The clinical course of this patient who had lung and renal manifestations did not favour a diagnosis of ulcerative colitis. The final diagnosis was microscopic polyangiitis with gastrointestinal involvement.

Extended colonic ulcerations with haemorrhage have not been reported previously in patients with microscopic polyangiitis. Vasculitis should be considered for differential diagnoses of colonic ulcerations, especially when the presentation is atypical, to avoid delay of prompt treatment.

### Authors' affiliations

C-N Tsai, M-F Liu, C-R Wang, Section of Rheumatology, Department of Internal Medicine, College of Medicine, National Cheng Kung University, Tainan, Taiwan

C-M Chang, Section of Geriatrics, Department of Internal Medicine, College of Medicine, National Cheng Kung University, Tainan, Taiwan  
 C-H Chuang, Section of Gastroenterology, Department of Internal Medicine, College of Medicine, National Cheng Kung University, Tainan, Taiwan  
 Y-T Jin, Department of Pathology, College of Medicine, National Cheng-Kung University, Tainan, Taiwan

Correspondence to: Dr C-R Wang, Section of Rheumatology and Section of Allergy and Immunology, Department of Internal Medicine, College of Medicine, National Cheng Kung University, No 1, University Road, Tainan, Taiwan; wangcr@mail.ncku.edu.tw

Accepted 10 March 2004

## REFERENCES

- Jennette JC, Falk RJ. Small-vessel vasculitis. *N Engl J Med* 1997;**337**:1512-23.
- Guillevin L, Durand-Gasselin B, Cevallos R, Gayraud M, Lhote F, Collard P, et al. Microscopic polyangiitis: clinical and laboratory findings in 85 patients. *Arthritis Rheum* 1999;**42**:421-30.
- Boyd JF. Pathology of the alimentary tract in Salmonella typhimurium food poisoning. *Gut* 1985;**26**:935-44.
- Northway MG, Scobey MW, Geisinger KR. Radiation proctitis in the rat. Sequential changes and effects of anti-inflammatory agents. *Cancer* 1988;**62**:1962-9.
- Epstein RJ, McDonald GB, Sale GE, Shulman HM, Thomas ED. The diagnostic accuracy of the rectal biopsy in acute graft-versus-host disease: a prospective study of thirteen patients. *Gastroenterology* 1980;**78**:764-71.
- Storch I, Sachar D, Katz S. Pulmonary manifestations of inflammatory bowel disease. *Inflamm Bowel Dis* 2003;**9**:104-15.
- Wilcox GM, Aretz HT, Roy MA, Roche JK. Glomerulonephritis associated with inflammatory bowel disease. *Gastroenterology* 1990;**98**:786-91.
- Abad E, Tural C, Mirapeix E, Cuxart A. Relationship between ANCA and clinical activity in inflammatory bowel disease: variation in prevalence of ANCA and evidence of heterogeneity. *J Autoimmun* 1997;**10**:175-80.

# Severe digital ischaemia treated with phosphodiesterase inhibitors

C R Kumana, G T Y Cheung, C S Lau

*Ann Rheum Dis* 2004;**63**:1522-1524. doi: 10.1136/ard.2003.015677

Pulmonary hypertension is associated with autoimmune diseases, giving rise to digital ischaemia, including Raynaud's phenomenon (RP). As sildenafil, a phosphodiesterase-5 (PDE-5) inhibitor, relieves the pulmonary hypertension,<sup>1</sup> we suggested that it might also benefit digital ischaemia and RP symptoms. This report describes the impact of oral sildenafil (Viagra, donated by Pfizer HK) on three women with autoimmune disease and progressively severe digital ischaemia, despite treatment with a variety of drugs, including intravenous iloprost (fig 1). All patients gave written informed consent to try this off-label treatment.

## CASE REPORTS

A 42 year old woman with dermatomyositis "sine myositis" and thyrotoxicosis (case 1) taking prednisolone, hydroxychloroquine, and carbimazole, experienced regression of troublesome RP and ischaemic digital ulceration after receiving diltiazem SR 200 mg/day and thrice monthly iloprost infusions. Ten months later, antituberculosis chemotherapy was started and the steroid dosage reduced, after she developed a febrile illness with cough, pleuropericardial effusions, and sputum culture positive for tuberculosis (TB). Digital gangrene supervened in both hands and both feet despite daily intravenous iloprost infusions for 2 weeks.

A day after starting sildenafil 50 mg three times a day her digital circulation and pain improved markedly; facial flushing was the only adverse reaction. In view of the slightly deteriorating digital ischaemia and experimental evidence,<sup>2,3</sup> we inferred that rifampicin treatment was inducing the metabolism of sildenafil. Its dosage was therefore doubled. Symptomatic improvement continued and ischaemic tissues became demarcated. However, 26 days after starting sildenafil she succumbed to uncontrolled pulmonary TB.

A 28 year old woman with scleroderma/lupus (case 2) who had been receiving diltiazem, domperidone, omeprazole, and penicillamine for about 4 years presented with progressive breathlessness. Computed tomography of the thorax suggested fibrosing alveolitis; prednisolone and azathioprine were started. Thereafter, she incurred occasional chest infections, other complications, and features of autoimmune diseases. She then developed persistent high grade fever, chills, rigors, night sweats, and increasingly severe digital arthralgia, vasculitis, and ischaemia. A polymerase chain reaction (PCR) of blood disclosed disseminated TB. Despite resolution of the sepsis after anti-TB chemotherapy, she developed progressive ischaemia and impending gangrene of her fingers, toes, and feet, despite regular infusions of iloprost for 2 weeks. One day after starting sildenafil 50 mg