

UNUSUAL AND MEMORABLE

Case Number 29: Ochronosis: synovial histopathological characteristics

Series editor: Gary D Wright

Ann Rheum Dis 2004;**63**:130. doi: 10.1136/ard.2003.013912

The patient, a 43 year old woman with a 35 year history of alkaptonuria (fig 1A), presented to the orthopaedic clinic for pain in the right shoulder. Clinical examination demonstrated an important reduction of shoulder mobility with, on radiographic evaluation, a greatly destroyed joint (fig 1B). The patient was admitted to hospital to obtain a shoulder prosthesis.

Ochronosis is a rare autosomal recessive disorder featuring total lack of the enzyme homogentisic oxidase, resulting in an accumulation of homogentisic acid, a metabolite of phenylalanine and tyrosine. Deposition of ochronotic pigment results in darkening of the skin and cartilage, which is first seen in the conchae, antihelix of the ear (fig 1C), and sclerae.¹

Macroscopic inspection of the joint during surgery showed darkening of the cartilage. Histopathological examination of the paraffin embedded sections disclosed brittle pigmented articular cartilage, of which very small fragments were broken off and displaced into the synovial tissue: yellow-brown shards, scattered over the synovium (fig 1D). These typical shards can evoke foreign body reactions with multinucleated giant cells (fig 1E) and induce formation of

new bone tissue called osteochondral bodies. Furthermore, haemosiderin and ochronotic pigment in macrophages (fig 1F), and focal inflammatory infiltrates of lymphocytes and plasma cells with some lining layer hyperplasia and hypervascularity can be seen.^{1 2}

E Kruithof, D Baeten, E M Veys, F De Keyser

Department of Rheumatology, Ghent University Hospital, Belgium

S Suykens, L De Wilde, R Verdonk

Department of Orthopaedics, Ghent University Hospital, Belgium

Correspondence to: Dr E Kruithof, Department of Rheumatology, OK12 IB, Ghent University Hospital, De Pintelaan 185, 9000 Gent, Belgium; elli.kruithof@uGent.be

References

- 1 Schumacher H. Ochronosis, hemochromatosis, and Wilson's disease. In: Koopman WJ, ed. *Arthritis and allied conditions*. Philadelphia: Lippincott Williams & Wilkins, 2001:2435-47.
- 2 Selvi E, Manganelli S, Mannoni A, Benucci M, Minacci C, Marcolongo R. Chronic ochronotic arthritis: clinical, arthroscopic, and pathologic findings. *J Rheumatol* 2000;**27**:2272-4.

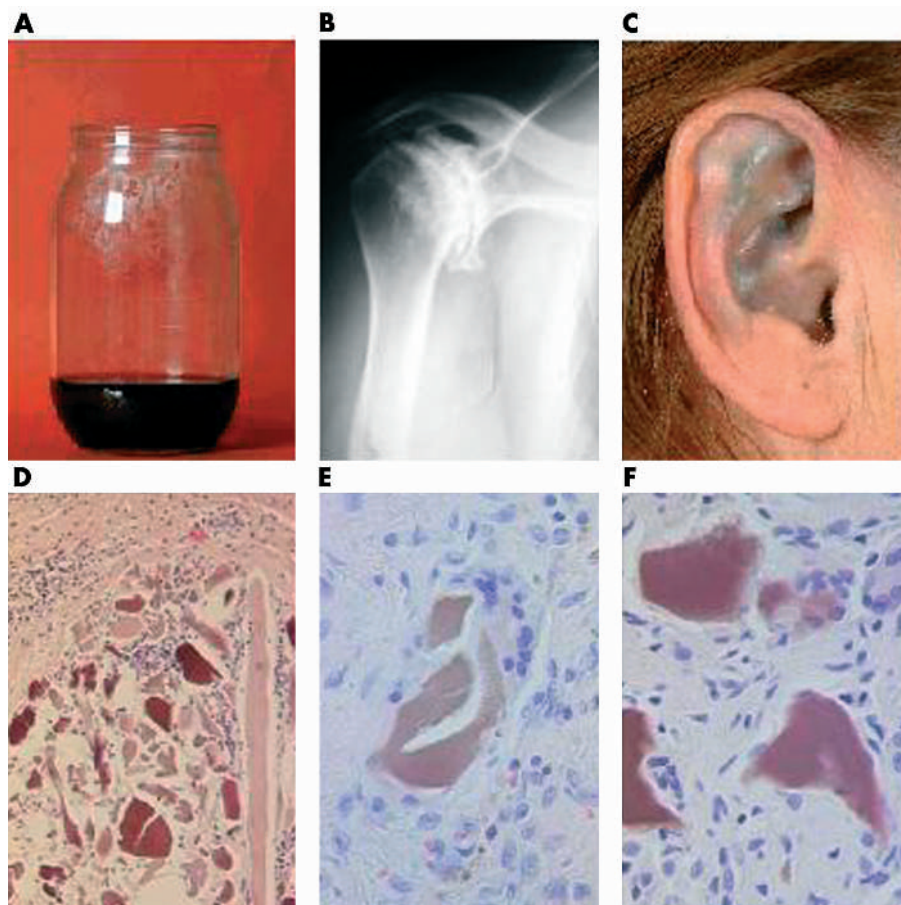


Figure 1 (A) Darkening of the urine by standing; (B) x ray picture of the right shoulder demonstrating a destroyed joint with sclerosis, osteophytosis; (C) slate-blue discolouration of the antihelix of the ear; (D) yellow-brown shards, scattered over the synovium; (E, F) shard evoking a foreign body reaction with multinucleated giant cells and surrounded by pigment loaded macrophages.