

A report of only one other case has been published previously.⁸ To date, five other cases have been reported to the French pharmacovigilance system⁹ over a period of 2 years.

Carulli and Davies suggested that the neuropathy might be due to a neurological vasculitis induced by leflunomide.⁸ In the absence of a neuromuscular biopsy, this hypothesis could not be confirmed, but it is supported by a case report of cutaneous vasculitis induced by leflunomide without any neurological disorder.¹⁰ Moreover, two cases in this case series presented with aspecific vasculitis diagnosed by neuromuscular biopsy when the aetiology of the neuropathy was explored.

Clearly, clinicians should be aware of the possibility of peripheral neuropathy in patients treated with leflunomide, especially when other risk factors are present. This does not detract from the usefulness of this drug in the treatment of rheumatoid arthritis.

Authors' affiliations

K Martin, F Haramburu, Inserm U 657, Bordeaux, France; Centre Régional de Pharmacovigilance, Département de Pharmacologie, CHU de Bordeaux, 33076 Bordeaux, France

F Bentaberry, C Dumoulin, J Dehais, T Schaefferbeke, Service de Rhumatologie, CHU, Bordeaux, France

M Longy-Boursier, Service de Médecine Interne, CHU, Bordeaux, France

F Lifermann, Service de Médecine Interne, CHG Dax, France

K Martin, F Haramburu, B Bégaud, N Moore, Inserm U 657, Bordeaux, France; Département de Pharmacologie, IFR99, Université Victor Segalen, 33076 Bordeaux, France

Correspondence to: Dr K Martin, Inserm U 657, IFR 99; MP2S, Département de Pharmacologie, Zone Nord, Bâtiment 1A, Université

Victor Segalen – CHU, 33076 Bordeaux cedex, France; karin.martin@pharmaco.u-bordeaux2.fr

Accepted 18 September 2004

REFERENCES

- 1 **Strand V**, Cohen S, Schiff M, Weaver A, Fleischmann R, Cannon G, *et al*. Treatment of active rheumatoid arthritis with leflunomide compared with placebo and methotrexate. *Arch Intern Med* 1999;**159**:2542–50.
- 2 **Emery P**, Breedveld FC, Lemmel EM, Kaltwasser JP, Dawes PT, Gömör B, *et al*. A comparison of the efficacy and safety of leflunomide and methotrexate for the treatment of rheumatoid arthritis. *Rheumatology* 2000;**39**:655–65.
- 3 **Smolen JS**, Kalden JR, Scott DL, Rozman B, Kvien TK, Larsen A, *et al*. Efficacy and safety of leflunomide compared with placebo and sulphasalazine in active rheumatoid arthritis: a double-blind, randomised, multicentre trial. *Lancet* 1999;**353**:259–66.
- 4 **Kalden JR**, Scott DL, Smolen JS, Schattenkirchner M, Rozman B, Williams BD, *et al*. European Leflunomide Study Group. Improved functional ability in patients with rheumatoid arthritis—longterm treatment with leflunomide versus sulfasalazine. European Leflunomide Study Group. *J Rheumatol* 2001;**28**:1983–91.
- 5 **Cohen S**, Cannon GW, Schiff M, Weaver A, Fox R, Olsen N, *et al*. Two-year, blinded, randomized, controlled trial of treatment of active rheumatoid arthritis with leflunomide compared with methotrexate. Utilization of Leflunomide in the Treatment of Rheumatoid Arthritis Trial Investigator Group. *Arthritis Rheum* 2001;**44**:1984–92.
- 6 **Scott DL**, Smolen JS, Kalden JR, van de Putte LB, Larsen A, Kvien TK, *et al*. Treatment of active rheumatoid arthritis with leflunomide: two year follow up of a double blind, placebo controlled trial versus sulfasalazine. *Ann Rheum Dis* 2001;**60**:913–23.
- 7 **Kalden JR**, Schattenkirchner M, Sorensen H, Emery P, Deighton C, Rozman B, *et al*. The efficacy and safety of leflunomide in patients with active rheumatoid arthritis: a five-year followup study. *Arthritis Rheum* 2003;**48**:1513–20.
- 8 **Carulli MT**, Davies UM. Peripheral neuropathy: an unwanted effect of leflunomide? *Rheumatology* 2002;**41**:952–3.
- 9 **Moore N**, Biour M, Paux G, Loupi E, Bégaud B, Boismare F, *et al*. Adverse drug reaction monitoring: doing it the French way. *Lancet* 1985;**2**:1056–8.
- 10 **Holm EA**, Balslev E, Jemec GB. Vasculitis occurring during leflunomide therapy. *Dermatology* 2001;**203**:258–9.

Tumour necrosis factor α antagonists and early postoperative complications in patients with inflammatory joint disease undergoing elective orthopaedic surgery

S C Talwalkar, D M Grennan, J Gray, P Johnson, M J Hayton

Tumour necrosis factor α (TNF α) antagonists are now established as therapeutic agents for active rheumatoid arthritis (RA) resistant to conventional drug treatment.¹ However, they decrease resistance to infection, including unusual infections such as tuberculosis,^{2,3} and in an experimental setting have been shown to impair wound healing.⁴ Previous studies have shown that TNF α antagonists do not increase the risk of postoperative surgical complications in patients with Crohn's disease who undergo resective bowel surgery,^{5,6} but the safety of these drugs in patients with RA who undergo elective orthopaedic surgery has not yet been established.

As over 10% of patients with RA at our institution receiving antirheumatic drugs still require some form of elective orthopaedic surgical intervention we carried out a retrospective study of patients who received anti-TNF drug treatment before elective orthopaedic surgery.

Depending on the complexity, operations were divided into major surgery, including joint replacement surgery and lower limb arthrodeses; minor cases, including day case surgery;

Ann Rheum Dis 2005;**64**:650–651. doi: 10.1136/ard.2004.028365

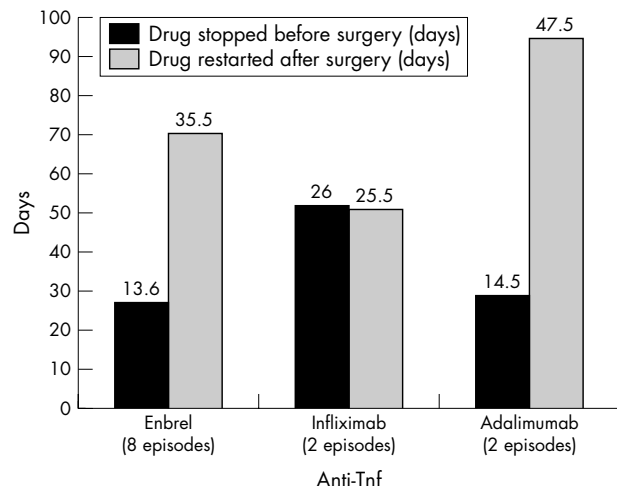


Figure 1 Time at which drug treatment was stopped and restarted.

Table 1 Complications

Group	Complications		Type of surgery
	(n)	Type	
A (n = 4)	2	Reflex sympathetic dystrophy Medial malleolar fracture	Major (wrist replacement) Major (total ankle replacement)
B (n = 12)	1	Hip dislocation	Major (total hip replacement)

and the remaining procedures, which were in an intermediate group.

Patient records were used to identify which anti-TNF α antagonist was used. We reviewed 16 operations in 11 patients who had received an anti-TNF α drug in the perioperative period. Patients comprised six women and five men with a mean age of 57.8 years (range 33–75). Of the patients studied, 10 had RA and one patient had psoriatic arthritis. The average disease duration from diagnosis was 17.6 years (range 6–27).

Two groups of patients were identified. Group A represented patients in whom anti-TNF α drug treatment was continued in the postoperative period, whereas group B comprised patients for whom the drug was stopped before surgery and restarted after the procedure. In group A, infliximab was used in one operation, the patient receiving the injection 3 days before surgery while etanercept (Enbrel) was used in three patients. All the patients in group A underwent joint replacement surgery. Figure 1 shows when the different drugs were stopped and started with reference to surgery in group B. Infliximab, owing to its long half life and different administration schedule, was stopped nearly 4 weeks before surgery, whereas adalimumab and etanercept were stopped at 2 weeks. The timings for restarting the drug were variable and depended on the preference of individual consultants.

Three patients had complications (table 1). The patient who underwent hip replacement surgery required revision surgery to correct the femoral stem and had an inpatient stay of 55 days. In the remaining patients who underwent major surgery the duration of stay was between 6 and 13 days, with an average of 10.6 days.

There was no serious wound or systemic infections in any of the patients on follow up. Postoperatively, one flare up occurred in a patient receiving etanercept in group B, who underwent a triple arthrodesis of the ankle. The flare up developed during the postoperative period and was well controlled once the drug was restarted.

In a previous similar study by the authors, the overall rate of complications and infections in the perioperative period

was found to be 10% in 388 patients.⁷ In the present study none of the patients being treated with an anti-TNF antagonist developed infections. Although two of the three complications were in group A, these were not thought to be to drug related. Therefore in this small study there is no evidence that anti-TNF drug treatment, whether discontinued or continued, increased either the rate of infection or the complication rate.

Authors' affiliations

S C Talwalkar, M J Hayton, Department of Upper Limb Surgery, Wrightington Hospital, Manchester, UK

D M Grennan, Department of Rheumatology, Wrightington Hospital, Manchester, UK

J Gray, P Johnson, Clinical Trials Unit, Wrightington Hospital, Manchester, UK

Correspondence to: Mr S C Talwalkar, 508 Imperial Point, The Quays, Manchester M50 3RA UK; stalwalkar@aol.com

Accepted 18 September 2004

REFERENCES

- 1 **Rosandich PA**, Kelley JT 3rd, Conn DL. Perioperative management of patients with rheumatoid arthritis in the era of biologic response modifiers. *Curr Opin Rheumatol* 2004;**16**:192–8.
- 2 **Keane J**, Gershon S, Wise RP, Mirabile-Levens E, Kasznica J, Schwieterman WD, et al. Tuberculosis associated with infliximab, a tumor necrosis factor alpha-neutralizing agent. *N Engl J Med* 2001;**345**:1098–104.
- 3 **Mohan AK**, Cote TR, Block JA, Manadan AM, Siegel JN, Braun MM. Tuberculosis following the use of etanercept, a tumor necrosis factor inhibitor. *Clin Infect Dis* 2004;**39**:295–9. Epub 16 July 2004.
- 4 **Mooney DP**, O'Reilly M, Gamelli RL. Tumor necrosis factor and wound healing. *Ann Surg* 1990;**211**:124–9.
- 5 **Marchal L**, D'Haens G, Van Assche G, Vermeire S, Noman M, Ferrante M, et al. The risk of post-operative complications associated with infliximab therapy for Crohn's disease: a controlled cohort study. *Aliment Pharmacol Ther* 2004;**19**:749–54.
- 6 **Colombel JF**, Loftus EV Jr, Tremaine WJ, Pemberton JH, Wolff BG, Young-Fadok T, et al. Early postoperative complications are not increased in patients with Crohn's disease treated perioperatively with infliximab or immunosuppressive therapy. *Am J Gastroenterol* 2004;**99**:878–83.
- 7 **Grennan DM**, Gray J, Loudon J, Fear S. Methotrexate and early postoperative complications in patients with rheumatoid arthritis undergoing elective orthopaedic surgery. *Ann Rheum Dis* 2001;**60**:214–17.

Cutaneous vasculitis developed in a patient with breast cancer undergoing aromatase inhibitor treatment

H Shoda, S Inokuma, N Yajima, Y Tanaka, K Setoguchi

Ann Rheum Dis 2005;**64**:651–652. doi: 10.1136/ard.2004.023150

Aromatase inhibitors are used in a newly introduced hormonal regimen for breast cancer.¹ They reduce endogenous oestrogen production, and control the

progression of oestrogen receptor positive breast cancer. Among aromatase inhibitors, anastrozole is a newly developed inhibitor. We treated a patient with cutaneous vasculitis