

CO₂ wedged hepatic venography in the evaluation of portal hypertension

W Debernardi-Venon, J-C Bandi, J-C García-Pagán, E Moitinho, V Andreu, M Real, A Escorsell, X Montanyá, J Bosch

Abstract

Background/claims/methods—During hepatic vein catheterisation, in addition to measurement of hepatic venous pressure gradient (HVPG), iodine wedged retrograde portography can be easily obtained. However, it rarely allows correct visualisation of the portal vein. Recently, CO₂ has been suggested to allow better angiographic demonstration of the portal vein than iodine. In this study we investigated the efficacy of CO₂ compared with iodinated contrast medium for portal vein imaging and its role in the evaluation of portal hypertension in a series of 100 patients undergoing hepatic vein catheterisation, 71 of whom had liver cirrhosis.

Results—In the overall series, CO₂ venography was markedly superior to iodine, allowing correct visualisation of the different segments of the portal venous system. In addition, CO₂, but not iodine, visualised portal-systemic collaterals in 34 patients. In cirrhosis, non-visualisation of the portal vein on CO₂ venography occurred in 11 cases; four had portal vein thrombosis and five had communications between different hepatic veins. Among non-cirrhotics, lack of portal vein visualisation had a 90% sensitivity, 88% specificity, 94% negative predictive value, and 83% positive predictive value in the diagnosis of pre-sinusoidal portal hypertension.

Conclusions—Visualisation of the venous portal system by CO₂ venography is markedly superior to iodine. The use of CO₂ wedged portography is a useful and safe complementary procedure during hepatic vein catheterisation which may help to detect portal thrombosis. Also, lack of demonstration of the portal vein in non-cirrhotic patients strongly suggests the presence of pre-sinusoidal portal hypertension.

(Gut 2000;46:856-860)

Keywords: portal thrombosis; liver cirrhosis; idiopathic portal hypertension; splanchnic haemodynamics

Imaging techniques are very useful in the assessment of the portal hypertensive patient.¹ Apart from providing evidence of the presence of portal hypertension by visualisation of portal-systemic collaterals and/or dilated splenic, mesenteric and portal veins, a correct definition of the portal anatomy is essential to

rule out the presence of portal vein thrombosis, which could be the cause of or complicate portal hypertension due to chronic liver disease.² In addition, imaging techniques are required to evaluate pre-sinusoidal portal hypertension, and before shunt surgery, orthotopic liver transplantation, and hepatic resection.³ Although non-invasive techniques, including duplex Doppler sonography, CT scan, and MR are sufficient in many cases, direct visualisation of the portal venous system using different angiographic techniques is frequently required.⁴⁻⁸

During routine hepatic vein catheterisation, in addition to measurement of hepatic venous pressures, it is possible, easy, and safe to perform retrograde wedged hepatic venography.⁹⁻¹³ However, this is infrequently done because it rarely allows correct visualisation of the portal vein. CO₂ was used for imaging hepatic vessels more than 30 years ago.¹⁴⁻¹⁸ Digital subtraction techniques have greatly improved the results of CO₂ angiography,¹⁹ and wedged hepatic venographies using CO₂ as a radiological contrast have been used to allow visualisation of the intrahepatic portal vein during TIPS procedures.²⁰

The aim of the present study was to investigate the efficacy and safety of CO₂ compared with iodinated contrast media (ICM) for visualisation of the portal vein during wedged hepatic venography. In addition, the role of wedged hepatic venography in the evaluation of portal hypertensive patients was assessed.

Methods

The study was performed in 100 patients (39 female and 61 male) referred for haemodynamic evaluation of portal hypertension and/or performance of a transjugular liver biopsy at the Hepatic Haemodynamic Laboratory, Hospital Clínic of Barcelona. All patients gave written, informed consent before each study. The study was approved by the ethics committee of the hospital clinic in December 1995 and was conducted in accordance with the Helsinki Declaration of 1975, as revised in 1983.

Mean age of the patients was 55 (14) years. Seventy one patients were known to have liver cirrhosis based on clinical, biochemical, ultrasonographic, and/or histological criteria. Thirty five belonged to Child-Pugh class A, 24 to class B, and 12 to class C. The remaining 29

Abbreviations used in this paper: HVPG, hepatic venous pressure gradient; WHVP, wedged hepatic venous pressure; FHVP, free hepatic venous pressure; ICM, iodinated contrast media.

Hepatic
Haemodynamic
Laboratory, Liver
Unit, IMD, Institut
d'Investigacions
Biomèdiques August
Pi I Sunyer
(IDIBAPS), Hospital
Clínic, University of
Barcelona, Spain
W Debernardi-Venon
J-C Bandi
J-C García-Pagán
E Moitinho
V Andreu
A Escorsell
J Bosch

Department of
Radiology, Hospital
Clínic, University of
Barcelona, Spain
M Real
X Montanyá

Correspondence to:
Dr J Bosch, Hepatic
Haemodynamic Laboratory,
Liver Unit, Hospital Clínic,
Villarroel 170, 08036
Barcelona, Spain. Email:
jbosch@medicina.ub.es

Accepted for publication
21 December 1999

Table 1 Aetiology of the patients studied

	Patients (n)
Cirrhotics†	71
Alcoholic	23
Hepatitis C	38
Hepatitis B	1
Autoimmune hepatitis	2
Cryptogenic cirrhosis	5
Biliary cirrhosis	2
Non-cirrhotics	29
Acute liver failure	7
Chronic hepatitis	6
Budd-Chiari syndrome	2
Veno-occlusive disease	1
Myeloid metaplasia*	1
Granulomatous hepatitis*	1
Congenital hepatic fibrosis*	1
Idiopathic portal hypertension*	6
Nodular regenerative hyperplasia*	2
Others	2

†Four patients had an associated portal vein thrombosis.

*Patients with pre-sinusoidal portal hypertension.

patients were non-cirrhotic and were referred because of suspected portal hypertension (n=16) or for a diagnostic transjugular liver biopsy (n=13). The aetiology of cirrhosis and diagnoses in the non-cirrhotic patients are reported in table 1. The final diagnosis in non-cirrhotic patients was based on liver biopsy, mesenteric angiography, haematological, and serological studies, which were performed as required.

PROCEDURES

Wedged hepatic venographies using CO₂ or ICM were performed during hepatic vein catheterisation. This was carried out as previously described²¹ via the right femoral or jugular vein, using a 7-F balloon occlusion catheter (Medi-Tech, Boston Scientific Corp., Boston, Massachusetts, USA). Wedged hepatic venography was obtained after measuring wedged and free hepatic venous pressures (WHVP and FHVP) and the hepatic venous pressure gradient (HVPG—difference between WHVP and FHVP). Firstly, 10 ml of iodine contrast medium (Iohexol 300 mg iodine/ml, Schering AG, Germany) were injected as a forceful hand injection and angiograms were recorded at high speed (four images per second for five seconds) using high definition fluoroscopy (Phillips BV29, Phillips Medical Systems, Netherlands). Afterwards, CO₂ was obtained from a high pressure unit into a 50 ml syringe fitted with three stopcocks and two microfilters (0.2 µm, Millex-FG, Millipore, Molsheim, France). The syringe was rinsed with CO₂, filled to a pressure of 1 bar, and connected to the catheter. Angiography was performed using standard digital subtraction angiography after opening the stopcocks, allowing rapid injection of CO₂. Dynamic images were obtained in the same sequence used for iodine wedged hepatic venography.

The degree of retrograde opacification of each of the intrahepatic portal vein branches, portal vein trunk, splenic vein, superior mesenteric vein, and portal-systemic collaterals was assessed in the CO₂ and iodine wedge hepatic venographs as none, slight, or marked opacification.

Table 2 Degree of retrograde opacification of the portal venous system on CO₂ and iodine wedged hepatic venography in the overall series of patients

	CO ₂ (n)	Iodine (n)	p Value
RPV			
Marked	62	20	
Slight	14	9	
None	24	71	<0.02
LPV			
Marked	64	7	
Slight	10	1	
None	26	92	<0.01
PVT			
Marked	49	5	
Slight	22	2	
None	29	93	<0.001
SV			
Marked	34	1	
Slight	10	1	
None	56	98	<0.0001
MV			
Marked	30	0	
Slight	13	1	
None	57	99	<0.0001
GOC	34	0	<0.01

RPV, right portal vein; LPV, left portal vein; PVT, portal vein trunk; SV, splenic vein; MV, mesenteric vein; GOC, gastroesophageal collaterals.

DATA ANALYSIS

The dynamic portographies were evaluated separately by two members of the team (WD, JCB) who were blinded to the clinical data and results of pressure measurements. Values are shown as mean (SD). Comparisons between groups were performed using Fisher's exact test or the Student's *t* test, as appropriate. Significance was established at $p < 0.05$. All calculations were performed using the SPSS statistical package (SPSS Inc., Chicago, Illinois, USA).

Results

In the overall series of patients, retrograde wedged hepatic venography using CO₂ as the contrast medium was significantly better than venography using ICM for visualisation of the different segments of the portal venous system (table 2). CO₂ venography allowed retrograde opacification of the entire portal vein (intrahepatic and extrahepatic portal vein) in 71 patients (71% *v* 7% with iodine venography; $p < 0.0001$). The splenic and/or mesenteric veins were further demonstrated with CO₂ venography in 44% of patients (*v* 2% with iodine venography; $p < 0.0001$) (fig 1). Extrahepatic collaterals were identified with CO₂ (fig 2) in 34 patients (left gastric vein n=12; umbilical vein n=6; spontaneous splenorenal shunt n=3; others n=13) compared with none with iodine portography ($p < 0.01$).

PATIENTS WITH CIRRHOSIS

In the 71 cirrhotic patients, CO₂ venography offered significantly better results than iodine venography, allowing visualisation of the portal vein and/or its intrahepatic branches in 65 (85%) patients compared with 25 (35%) with iodine venography ($p < 0.001$). There were no significant differences in age, sex, aetiology of cirrhosis, Child-Pugh score, HVPG, or WHVP between patients with or without opacification of the portal vein on CO₂ venography.

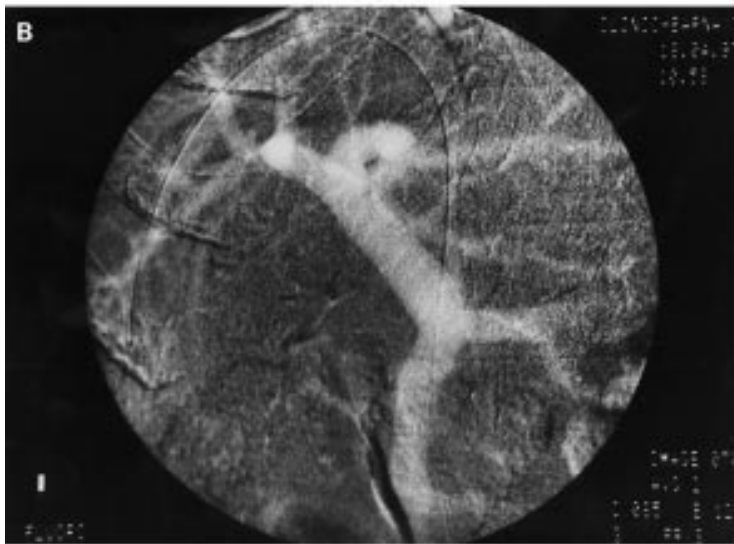
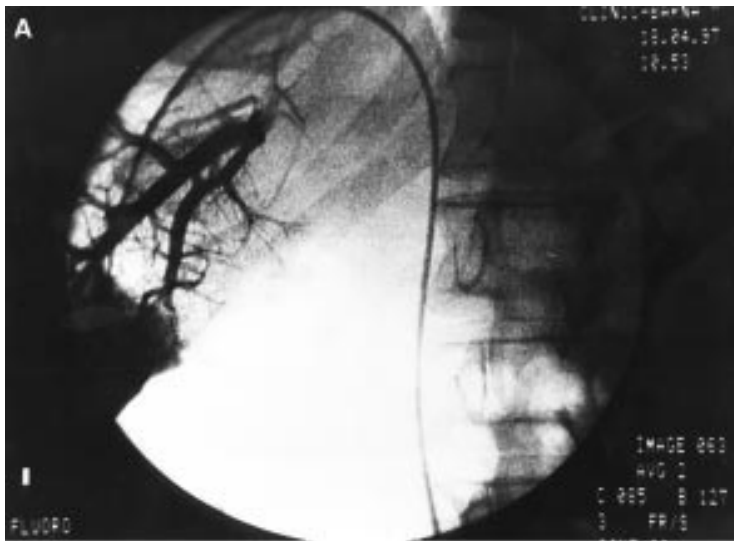

Figure 1 Iodine venography (A) allowed visualisation of the distal branches of the intrahepatic portal vein while CO₂ venography (B) allowed opacification of the whole spleno-mesenteric-portal system.

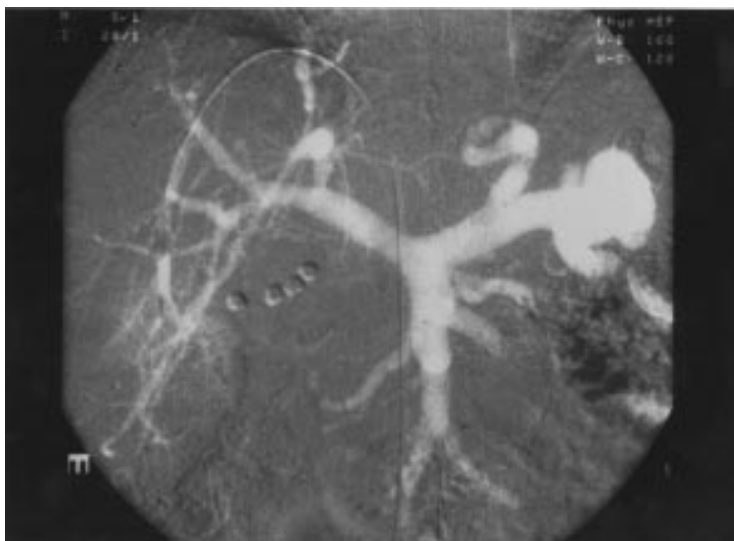

Figure 2 CO₂ venography allowed visualisation of the whole spleno-mesenteric-portal system, including the extrahepatic collaterals.

Of the 11 patients with cirrhosis in whom CO₂ venography did not allow visualisation of the portal vein, four had associated portal vein thrombosis which was confirmed by duplex Doppler ultrasonography and mesenteric angiography. In contrast, a patient suspected of having a portal thrombosis on sonography had a patent portal vein. Another five cirrhotic patients without visualisation of the portal vein on CO₂ venography had communications between different hepatic veins that precluded adequate wedged venography as the injected contrast escaped through another hepatic vein. Such veno-venous communications were uncommon among patients with cirrhosis in whom the portal vein was clearly demonstrated after retrograde CO₂ portography (6.6% *v* 45% in patients without visualisation of the portal vein, $p=0.01$). The remaining two patients in whom CO₂ venography did not demonstrate the portal vein had no particular characteristics.

NON-CIRRHOTIC PATIENTS

CO₂ venography showed the portal vein or its branches in 17 of 29 non-cirrhotic patients (59%). Ten of the 12 non-cirrhotic patients in whom CO₂ venography did not visualise the portal vein had pre-sinusoidal portal hypertension compared with only one (with a granulomatous hepatitis) of 17 patients in whom the portal vein was visualised on CO₂ venography ($p<0.01$). Therefore, in non-cirrhotic patients lack of visualisation of the portal vein trunk or its branches on CO₂ venography was strongly suggestive of pre-sinusoidal portal hypertension (with 90% sensitivity, 88% specificity, 94% negative predictive value, and 83% positive predictive value in the diagnosis) (fig 3). In contrast, ICM venography did not visualise the portal vein trunk or its branches in 80% of non-cirrhotic patients; hence it is of no clinical value in the diagnosis of pre-sinusoidal portal hypertension.

Three patients had post-sinusoidal portal hypertension (two Budd-Chiari syndrome; one veno-occlusive disease). In all, CO₂ venography showed complete opacification of the portal vein trunk.

CO₂ wedged venography was well tolerated. Although 70% of patients experienced moderate abdominal pain immediately after CO₂ injection, it was always transient (less than 10 seconds), disappearing with rapid dissipation of intravascular CO₂. After a short learning period, performing the CO₂ wedged venography did not add more than five minutes to the haemodynamic procedure.

Discussion

Wedged hepatic venography has long been used for radiological visualisation of the portal venous system.¹¹⁻¹³ However, despite its feasibility and safety, this technique is seldom used because the portal vein is rarely completely visualised.^{11, 22} This was confirmed by the present series in which wedged hepatic venography with ICM demonstrated the intrahepatic portal vein in only 29% of patients and the portal vein trunk in only 7%.

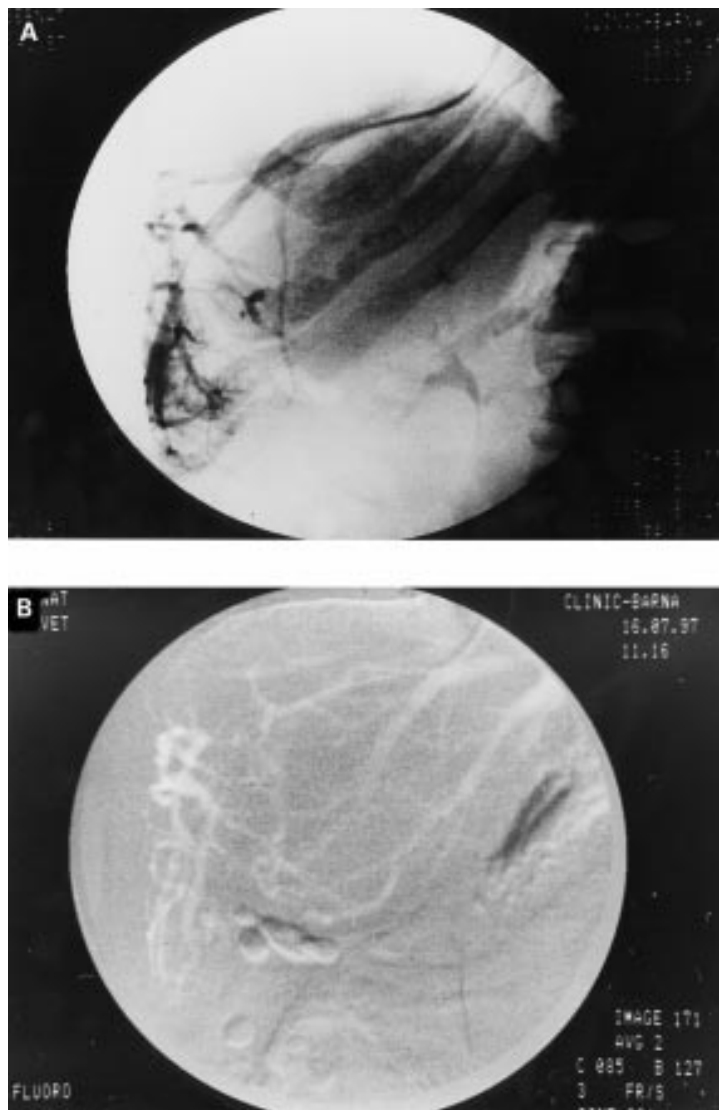


Figure 3 Idiopathic portal hypertension. The portal vein is not opacified either on iodine (A) or CO₂ (B) venography. Several veno-venous communications are seen.

The use of CO₂ as a contrast agent in radiological studies¹⁵⁻¹⁸ has changed this scenario. Although CO₂ venography has been extensively used in other areas, such as renal vascular imaging,²³ there are few reports in patients with portal hypertension. Preliminary studies suggested that CO₂ wedged hepatic venography would be superior than ICM in the evaluation of the intrahepatic portal vein during a TIPS procedure.²⁰ The results of our study demonstrate the superiority of CO₂ over ICM for wedged hepatic portography for that purpose. In addition, our data showed that CO₂ wedged hepatic venography allowed visualisation of the extrahepatic portal vein in more than 70% of cases. This is relevant, as in the diagnosis and evaluation of patients with portal hypertension recognition of portal vein patency is extremely important. The presence of portal thrombosis makes liver transplantation or derivative portal-systemic surgery difficult or even impossible. Although Doppler sonography is the first choice technique for the diagnosis of portal thrombosis, CO₂ wedged hepatic venography may help in those patients with equivocal data

on duplex Doppler examination, avoiding the need for more invasive techniques such as mesenteric arteriography. Indeed, in patients with cirrhosis, non-visualisation of the portal vein on CO₂ wedged hepatic venography, in the absence of venous-venous communications, strongly suggested an associated portal thrombosis. It is important to remark that in two of four patients with cirrhosis and portal thrombosis this was not detected by routine abdominal ultrasonography for screening of hepatocellular carcinoma. In addition, CO₂ portography correctly showed the absence of portal thrombosis in one patient where this was suspected by duplex Doppler ultrasonography.

Among non-cirrhotic patients, 11 had pre-sinusoidal portal hypertension. Of these 11 patients, CO₂ wedged venography did not demonstrate the portal vein in 10, and in the remaining patient only the more peripheral branches of the intrahepatic portal vein were slightly opacified. Thus in a non-cirrhotic patient with signs of portal hypertension, lack of visualisation of the portal vein on CO₂ wedged hepatic venography should indicate pre-sinusoidal portal hypertension. Portal vein thrombosis should be ruled out initially. However, in the presence of a patent portal vein, other causes of pre-sinusoidal portal hypertension should be considered.

Hepatic vein catheterisation is being used extensively worldwide because measurements of HVPG provide useful prognostic information, especially during the pharmacological treatment of portal hypertension.²⁴⁻²⁸ At hepatic vein catheterisation, performing a CO₂ wedged hepatic portography is easy, safe, and will not require a new procedure (it takes just a few extra minutes). In many instances CO₂ venography, in addition to demonstrating the patency of the portal vein, will allow full radiological mapping of the portal venous system which may be extremely helpful in surgical candidates. Hepatic vein catheterisation also offers the possibility of performing a transjugular liver biopsy which has been shown to be safe and useful for the diagnosis of liver diseases.²⁹⁻³⁰ Thus hepatic vein catheterisation has the unique advantage of allowing, in a single procedure, haemodynamic measurements, retrograde CO₂ portography, and transjugular liver biopsy which may permit a full diagnostic workout for portal hypertension within a half-day hospital admission.

Addendum

Since the preparation of the manuscript we have had the opportunity to study three patients with portal vein thrombosis confirming the diagnostic accuracy of the CO₂ wedged venography technique in these patients.

The authors thank A Baringo, L Rocabert, and R Sáez for expert technical assistance and D Bird and E Gutiérrez for secretarial assistance. This study was supported in part by a grant from the Fondo de Investigación Sanitaria (FIS 97/1309).

- 1 Groszmann RJ, Atterbury CE. The pathophysiology of portal hypertension; a basis for its classification. *Semin Liver Dis* 1982;2:177-86.
- 2 Okuda K, Onishi K, Kimura K, *et al*. Incidence of portal vein thrombosis in liver cirrhosis. An angiographic study in 708 patients. *Gastroenterology* 1985;89:279-86.
- 3 Triger DR. Extra hepatic portal venous obstruction. *Gut* 1987;28:1193-7.

- 4 Boyer JL, Sen Gupta KL, Biswas SK, et al. Idiopathic portal hypertension. Comparison with the portal hypertension of cirrhosis and extrahepatic portal vein obstruction. *Ann Intern Med* 1967;66:41-68.
- 5 Matsutani S, Kimura K, Ohto M, et al. Ultrasonography in the diagnosis of portal hypertension. In: Okudak, Benhamou JP, eds. *Portal hypertension*. Tokyo: Springer Verlag, 1991:197-205.
- 6 Barbara L, Okuda K, Taylor KJW, et al. The value of Doppler US in the study of hepatic hemodynamics. Consensus conference. *J Hepatol* 1990;10:353-5.
- 7 Okuda K, Takayasu K, Matsutani S. Angiography in portal hypertension. *Gastroenterol Clin North Am* 1992;21:61-83.
- 8 Williams DM, Cho KJ, Aisens AM, et al. Portal hypertension evaluated by MR imaging. *Radiology* 1985;157:703-6.
- 9 Rappaport AM, Holmes RB, Stolberg HO, et al. Hepatic venography. *Gastroenterology* 1964;46:115-27.
- 10 Novak D, Bützow GH, Becker K. Hepatic occlusion venography with balloon catheter in portal hypertension. *Radiology* 1977;122:623-8.
- 11 Okuda K, Nakashima T, Okudaira M, et al. Anatomical basis of hepatic venographic alterations in idiopathic portal hypertension. *Liver* 1981;1:255-63.
- 12 Futagawa S, Fukazawa M, Morisawa M, et al. Portographic liver changes in idiopathic non-cirrhotic portal hypertension. *Am J Radiol* 1980;134:917-23.
- 13 Schlant RC, Galambos JT, Shuford WH, et al. The clinical usefulness of wedged hepatic venography. *Am J Med* 1963;35:343-8.
- 14 Dockray KT, Burns RR, Moore J. Capnohepatography: intravenous retrograde gas angiography of liver veins with carbon dioxide. *Radiology* 1965;85:740-2.
- 15 Yusuf SW, Whitaker SC, Hinwood D, et al. Carbon dioxide: an alternative to iodinated contrast media. *Eur J Vasc Endovasc Surg* 1995;10:156-61.
- 16 Weaver FA, Pentecost MJ, Yellin AE, et al. Clinical applications of carbon dioxide/digital subtraction arteriography. *J Vasc Surg* 1991;13:266-73.
- 17 Kerns SR, Hawkins IF. Carbon dioxide digital subtraction angiography: expanding application and technical evolution. *Am J Radiol* 1995;164:735-41.
- 18 Sullivan KL, Bonn J, Shapiro MJ, et al. Venography with carbon dioxide as a contrast agent. *Cardiovasc Intervent Radiol* 1995;18:141-5.
- 19 Krasny R, Hollmann JP, Gunther RW. (Initial experiences with CO₂ as a gaseous contrast medium in digital subtraction angiography). *ROFO Fortschr Geb Röntgenstr Nuklearmed* 1987;146:450-4.
- 20 Wilhelm K, Textor J, Strunk H, et al. Carbon dioxide (CO₂) digital subtraction angiography for transjugular intrahepatic portsystemic shunt procedures. *ROFO Fortschr Geb Röntgenstr Neuen Bildgeb Verfahren* 1997;166:238-42.
- 21 García-Pagán JC, Navasa M, Bosch J, et al. Enhancement of portal pressure reduction by association of isosorbide-5 mononitrate to propranolol administration in patients with cirrhosis. *Hepatology* 1990;11:230-8.
- 22 Futagawa S, Fukazawa M, Musha H, et al. Hepatic venography in non-cirrhotic portal hypertension. *Radiology* 1981;141:303-9.
- 23 Hawkins IFJ, Wilcox CS, Kerns SR, et al. CO₂ digital angiography: a safer contrast agent for renal vascular imaging? *Am J Kidney Dis* 1994;24:685-94.
- 24 Groszmann RJ. The hepatic venous pressure gradient: has the time arrived for its application in clinical practice? *Hepatology* 1996;24:739-41.
- 25 Merkel C, Bolognesi M, Bellon S, et al. Prognostic usefulness of hepatic vein catheterization in patients with cirrhosis and esophageal varices. *Gastroenterology* 1992;102:973-9.
- 26 García-Tsao G, Groszmann RJ, Fisher R, et al. Portal pressure, presence of gastroesophageal varices and variceal bleeding. *Hepatology* 1985;5:419-24.
- 27 Groszmann RJ, Bosch J, Grace ND, et al. Hemodynamic events in a prospective randomized trial of propranolol vs placebo in the prevention of first variceal hemorrhage. *Gastroenterology* 1990;99:1401-7.
- 28 Feu F, García-Pagán JC, Bosch J, et al. Relation between portal pressure response to pharmacological therapy and risk of recurrent variceal haemorrhage in patients with cirrhosis. *Lancet* 1995;346:1056-9.
- 29 Trejo R, Alvarez W, García-Pagán JC, et al. The applicability and diagnostic effectiveness of transjugular liver biopsy. *Med Clin (Barc)* 1996;107:521-3.
- 30 Lebrec D, Degott C, Rueff B, et al. Transvenous (transjugular) liver biopsy. An experience based on 100 biopsies. *Am J Dig Dis* 1978;23:302-4.