

Chlamydia pneumoniae Infection Induces Inflammatory Changes in the Aortas of Rabbits

KIRSI LAITINEN,^{1,2} AINO LAURILA,² LIISA PYHÄLÄ,¹
MAIJA LEINONEN,² AND PEKKA SAIKKU^{2*}

National Public Health Institute, Helsinki¹ and Oulu,² Finland

Received 22 April 1997/Returned for modification 29 May 1997/Accepted 1 July 1997

***Chlamydia pneumoniae*, a common human respiratory pathogen, has been associated with atherosclerosis in several seroepidemiological studies. Moreover, its presence in lesions of vessel walls has been demonstrated by culture, immunohistochemistry, PCR, and electron microscopy. In this study, we infected intranasally with *C. pneumoniae* New Zealand White rabbits which had been fed a normal diet. Reinfection was given 3 weeks later. Six of the nine reinfected animals showed inflammatory changes consisting of intimal thickening or fibroid plaques resembling atherosclerosis in 2 to 4 weeks after reinfection. One rabbit had calcified lesions. Immunohistochemistry for *C. pneumoniae* was strongly positive in the three older affected animals. No lesions were seen in the controls. The results suggest that *C. pneumoniae* infection is capable of inducing inflammatory atherosclerosis-like changes in the aortas of infected rabbits.**

Chlamydia pneumoniae, an obligatory intracellular gram-negative bacterium, is a common cause of respiratory tract infections worldwide (21). In addition to causing acute infections, it has been associated with chronic lung processes such as asthma (11) and chronic obstructive pulmonary disease (39). The most important finding, however, appears to be the association of chronic *C. pneumoniae* infection with cardiovascular diseases. The first serological evidence on the association of *C. pneumoniae* infection with both acute myocardial infarction and chronic coronary heart disease (CHD) was published 1988 by a Finnish group (33), after which several groups in different parts of the world have confirmed the serological association between CHD and *C. pneumoniae* (3, 23, 24, 29, 34, 36, 37). More direct evidence on the role of *C. pneumoniae* in CHD was obtained by demonstrating this organism in atherosclerotic lesions, but rarely in healthy tissue, by electron microscopy, immunohistochemistry, PCR, and culture (10, 18–20, 26, 28, 30, 35, 38).

The association between *C. pneumoniae* infection and atherosclerosis has been demonstrated via several different methodological approaches by a number of laboratories around the world. However, the possible causal relationship between chronic *C. pneumoniae* infection and the development of atherosclerosis, and the exclusion of the possibility that it is merely an “innocent bystander,” can be verified only by animal experiments and intervention trials. A frequently used animal model for studying atherosclerosis is the New Zealand White (NZW) rabbit on a high-cholesterol or casein diet with or without arterial denudation (1, 6, 22). Our purpose was to study whether *C. pneumoniae* is capable of infecting vessel walls with the consequence of inflammatory lesions resembling atherosclerosis in these rabbits.

MATERIALS AND METHODS

***C. pneumoniae* strain and inoculation of animals.** *C. pneumoniae* Kajaani 7 (a mycoplasma-free Finnish epidemic strain) was used to inoculate the animals (5). The organisms propagated in an HL cell line (2) were purified by Renographin

gradient ultracentrifugation. The inoculum preparations were stored in aliquots in sucrose-phosphate-glutamate (SPG) buffer at -70°C until used.

The animals used were *Bordetella bronchiseptica* and *Pasteurella* spp.-free male NZW (HsdPoc:NZW) rabbits (5 months old) purchased from Harlan BV (AD Zeist, The Netherlands). The rabbits were fed an Altromin 2113 breeding diet (Christian Pedersen A/S, Ringstedt, Denmark) ad libitum.

The rabbits were sedated with Hypnorm (Duphar BV, Amsterdam, The Netherlands), 0.3 ml/kg of body weight intramuscularly, and inoculated intranasally with a total volume of 0.5 ml of organisms (2×10^7 inclusion-forming units/ml) suspended in SPG medium. The control animals were inoculated with 0.5 ml of sterile SPG medium. The intranasal inoculation was performed with a tuberculin syringe into the nostrils. The rabbits were reinfected in the same manner and with the same dose 3 weeks after the primary inoculation.

Observation of animals and sample collection. The rabbits were observed daily for signs of disease and weighed twice a week. Samples were collected 2 weeks after the primary infection and 1, 2, and 4 weeks after the reinfection (five infected animals and one control animal at each time point). For blood collection, the rabbits were sedated with Hypnorm and the blood was collected by heart puncture. After blood collection, each rabbit was euthanized by an intravenous injection of Mebunat (60 mg/kg; Orion, Helsinki, Finland).

The lungs, heart, aorta, liver, and spleen were removed by using sterile instruments. The aorta was carefully dissected and examined for macroscopic changes. Small tissue pieces were placed in SPG for culture, and the rest were fixed in 10% formalin for histology and immunohistochemistry.

Isolation and culture. Lung, spleen, and liver tissues were homogenized with a Stomacher mechanical blender in SPG in sterile plastic bags. The tissues were centrifuged at $500 \times g$ for 5 min at 4°C to remove tissues debris, and the supernatant was aliquoted for isolation. Culturing was done without delay in a confluent HL cell monolayer grown on coverslips in 24-well plates, using centrifugation at $550 \times g$ for 1 h. The inoculated cells were cultured in Dulbecco modified Eagle medium containing 5% fetal calf serum, 2 mM L-glutamine, cycloheximide (0.5 $\mu\text{g/ml}$), gentamicin (20 $\mu\text{g/ml}$), and vancomycin (20 $\mu\text{g/ml}$) at 35°C with 5% CO_2 . After 72 h, the HL cells were fixed and stained for inclusions with fluorescein isothiocyanate-conjugated *Chlamydia* genus-specific antibody (Pathfinder Chlamydia Confirmation System; Kallestad Diagnostic, Chaska, Minn.).

Serology. Antibodies to *C. pneumoniae* were measured by the microimmunofluorescence test using formalin-fixed whole elementary bodies of the Kajaani 7 strain as an antigen. Immunoglobulin G (IgG) antibodies in pre- and postinoculum sera were detected with fluorescein isothiocyanate-conjugated goat anti-rabbit IgG (Sigma Chemical Co., St. Louis, Mo.).

Histology. The lungs, spleen, liver, heart, and thoracic and abdominal aorta were fixed in 10% buffered formalin immediately after removal. Transverse sections 2 to 3 mm thick were taken from the ascending and abdominal aorta, the aortic arch was embedded as a whole, and a 1- to 2-cm longitudinal section was taken from the thoracic aorta, choosing a macroscopically affected area. Samples were collected to an equal extent from the infected and control animals. Tissue slices were embedded in paraffin, sectioned at 4 μm , and stained with hematoxylin and eosin; the aortic tissue also with Verhoeff's elastin stain.

Immunohistochemistry. A species-specific monoclonal antibody, RR 401 (Washington Research Foundation), was used to demonstrate *C. pneumoniae* antigen in aortic tissue. Immunostaining was performed by the avidin-biotin-

* Corresponding author. Mailing address: National Public Health Institute, P.O. Box 310, FIN-90101 Oulu, Finland. Phone: (358) 8 537 6227. Fax: (358) 8 537 6222. E-mail: Pekka.SaiKKu@ktl.fi.

TABLE 1. Microbiological and histopathological findings in rabbits infected intranasally with *C. pneumoniae*^a

Wk from primary infection	Animal no.	IgG antibody titer	Findings in aorta		
			Macroscopy	Histology	Immunohistochemistry ^b
0	4 ^c	<8	Normal	Normal	—
2	1–5	<8	Normal	Normal	—
3 (reinfection)	6–7 ^d				
4	8–11	32–512	Normal	Normal	—
5	12	128	Pale spots or streaks	Fibroelastic plaques	+/-
	13	128	Pale spots or streaks	Fibroelastic plaques	+/-
	14	128	Normal	Fibroelastic plaques	+/-
	15	64	Normal	Normal	—
7	16	512	Pale spots or streaks	Fibroelastic plaques	+
	17	128	Pale spots or streaks	Fibroelastic plaques	++
	18	256	Pale spots or streaks plus sclerotic lesions	Fibroelastic plaques plus calcified lesion	+
	19	256	Normal	Normal	—
	20	256	Normal	Normal	—

^a At every time point, all animals remained culture negative.

^b —, negative; +/-, equivocal; +, positive; ++, strongly positive.

^c Four control animals, one sacrificed at each time point.

^d Animal 6 died; animal 7 was sacrificed.

peroxidase method of Hsu et al. (13), using the Vectastain ABC kit (Vector Laboratories, Burlingame, Calif.). Diaminobenzidine was used as a chromogen, and hematoxylin was used as a counterstain. *C. pneumoniae*-infected HL cells served as positive and negative controls.

RESULTS

Growth of the experimental animals was clearly retarded after the reinfection. The average weight gain was 800 g per week in the control animals and after the first infection but only 50 g per week after the reinfection. However, no other clinical signs of disease (disturbances in food intake, hydration, and defecation) were observed except in two animals after the reinfection. One animal developed severe lung edema 24 h after the reinfection and died. The other rabbit had diarrhea, oculonasal discharge, and weight loss 2 days after the reinfection and was euthanized. Histopathologic findings showed that this animal had massive pneumonia.

All sample homogenates (lung, liver, and spleen) remained culture negative during the course of the infection. The samples were passaged once in HL cells and still remained culture negative. The preinoculation sera had no *C. pneumoniae* antibodies present. All of the infected animals seroconverted in 3 weeks with serum IgG titers against *C. pneumoniae* from 1:32 to 1:512.

The lungs of the infected animals (except the two with symptoms) were macroscopically normal, and only mild perivascular and peribronchial inflammatory infiltrate consisting mainly of lymphocytes and eosinophilic granulocytes was seen in histology. The control animals showed no macroscopic or histologic changes. The spleens of both the infected and the control animals remained macroscopically and histologically normal during the experiment. In the liver specimens, mild portal inflammation was seen in one animal after the primary infection and in three animals after the reinfection. The livers of the control animals liver were normal.

The amount of pericardial fat was macroscopically increased in the infected animals 2 weeks after the reinfection. In histology, only slight myofibrosis of the cardiac muscle was seen in three animals. Macroscopic changes in the aorta were seen in two animals 2 weeks postreinfection and in three animals 4 weeks postreinfection (Table 1). The changes consisted mainly of pale flat streaks or spot-like thickenings of the vessel wall

and were located in the aortic arch and thoracic aorta. In histology, proliferative lesions with focal intimal thickening and disruption of elastin fibers were seen (Fig. 1a). No foam cells or lipid accumulation was found in any of these lesions. In one of these animals, more advanced, calcified atherosclerotic plaques were found in the aortic arch 4 weeks postreinfection. Histologically, a fibrous plaque with calcification, smooth muscle cell proliferation, and inflammatory cell infiltration was seen (Fig. 1b).

Immunostaining with anti-*C. pneumoniae* antibodies showed an equivocal positive reaction in aortic endothelial cells in three animals 2 weeks after the reinfection (Table 1). Immunostaining was clearly positive in three animals at 4 weeks (Fig. 1c). All these animals also had macroscopic and/or microscopic changes. The controls remained negative.

DISCUSSION

We showed here that infection with *C. pneumoniae*, a respiratory pathogen, led to the formation of *C. pneumoniae* antigen-positive atherosclerosis-like changes in the aorta in healthy rabbits given a normal diet in 5 to 7 weeks. The finding indicates that *C. pneumoniae* is capable of infecting the vessel wall, which may lead to the development of lesions resembling atherosclerosis.

The rabbit model has been widely used for studies on atherosclerosis since the early 20th century (1). The disease is usually induced in normal NZW rabbits with unnatural diets containing lipids or proteins or by aggravating the arteries with mechanical denuding of vascular endothelium (1, 4, 6, 22, 31). In our rabbit model, atherosclerosis-like changes in the aortas of rabbits fed a normal diet were induced simply by giving them infectious chlamydiae intranasally. After the infection, *C. pneumoniae* antigen could be demonstrated in the vessel walls, and its presence was associated with the rapidly developing proliferative lesions. This observation points to the possibility that these lesions in the infected rabbits were caused by the *C. pneumoniae* infection and that the pathogen had not been merely deposited in preformed lesions due to other reasons. The model is comparable to the human situation, where most people become infected by *C. pneumoniae* at least once during

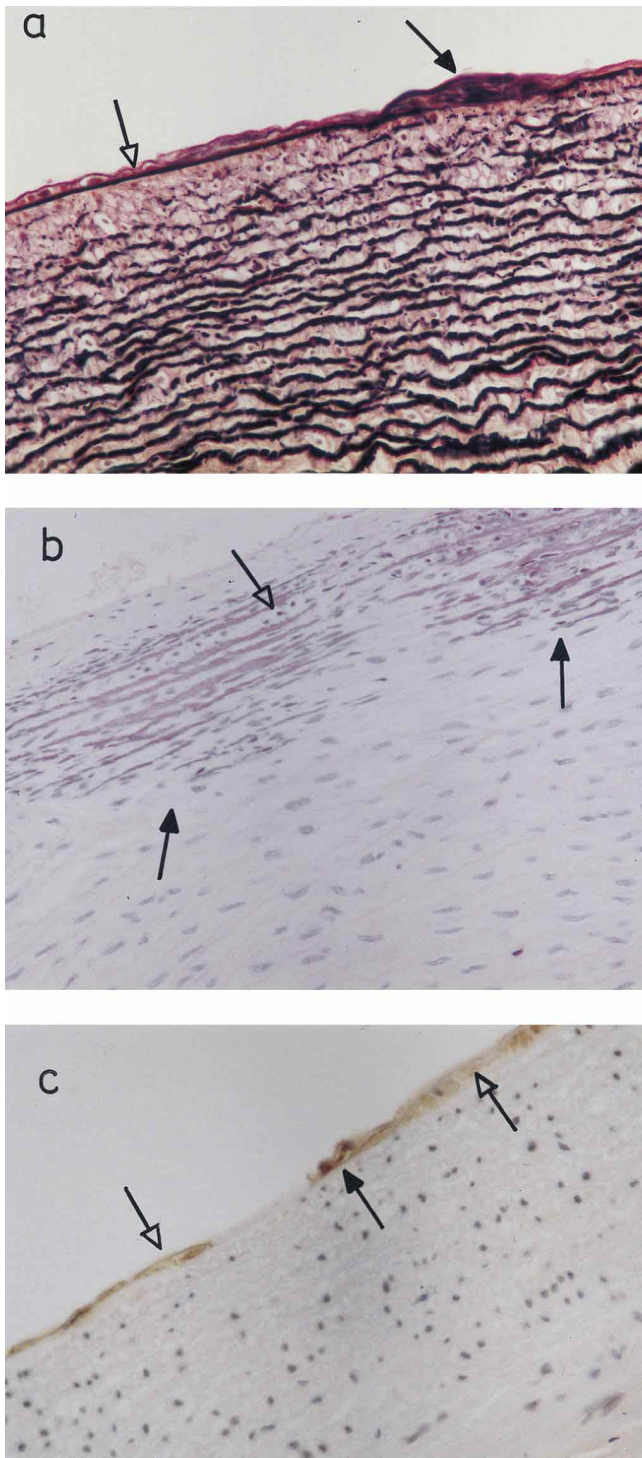


FIG. 1. Histopathology of the aortas of *C. pneumoniae*-infected rabbits. (a) In Verhoeff's elastin staining, focal intimal thickening and disruption of elastin fibers can be seen (dark arrow). Normal intima is thin and sharp (open arrow). (b) In one rabbit, calcified atherosclerotic lesions were found. Dark arrows show calcified streaks. Mononuclear inflammatory cells are found in lesions (open arrow; hematoxylin-eosin staining). (c) Immunohistochemical staining with anti-*C. pneumoniae* antibody shows positive reaction in some endothelial cells (dark arrow). Open arrows point negatively stained cells. Magnification, $\times 364$.

their lifetimes (21), and *C. pneumoniae* can be found in atherosclerotic lesions at a young age (20).

We found no lesions in the control rabbits, nor did Dailey et al. (4) or Richardson et al. (31), who followed up rabbits fed a normal diet up until 6 months. Xu et al., however, found a few mild lesions in 2 (18%) of 11 control rabbits aged 26 to 27 weeks and in 3 (25%) of 12 controls aged 42 to 43 weeks (40). Our animals were 20 to 21 weeks old at the onset of the study, and it is hence possible that some of the lesions were spontaneous. However, spontaneous calcified lesions are very rare.

C. pneumoniae is an obligatory intracellular bacterium capable of multiplying in endothelial and smooth muscle cells and macrophages (8, 9, 14, 15), and it has been shown recently that macrophages can disseminate *C. pneumoniae* (41). It induces the production of cytokines (15, 25) and adhesion molecules (16, 25), and it possesses an endotoxin, a lipopolysaccharide of a gram-negative organism (27) capable of inducing profound responses in the host organism. Furthermore, it can cause a persistent infection (12). Because of these properties, *C. pneumoniae* seems to be a highly suitable candidate for triggering the chronic inflammation found in atherosclerosis (32). However, the presence of *C. pneumoniae* in atherosclerotic lesions has also led to suggestions that it is deposited from blood circulation only in areas rich in oxidized fat as an innocent bystander. This theory is not supported by the fact that *C. pneumoniae* is a nonmotile pathogenic bacterium incapable of multiplying outside living cells (21). The finding of *C. pneumoniae* present in deep-site cells of arterial walls further speaks against passive sedimentation from blood circulation (10, 19, 20, 26, 28, 30, 35, 38).

Fong et al. (7) have recently shown that NZW rabbits infected once with *C. pneumoniae* develop pneumonia, and they also found fatty streaks and grade III atherosclerotic lesions in two of six animals 1 to 2 weeks after infection. In both rabbit models, therefore, atherosclerotic changes developed after infection with *C. pneumoniae*. However, there are some differences. In our animals, no microscopic lipid accumulation or foam cells were found, whereas Fong et al. (7) demonstrated accumulation of foamy macrophages in the aortic arch 1 week after infection. We inspected our rabbits 2 weeks after the primary and secondary infections, and it is thus possible that we have missed some early changes. Furthermore, we did not see any atherosclerotic changes in the rabbits infected only once. Even though the doses used for the infection of the animals were practically the same in both studies, Fong et al. (7) used a catheter to inoculate the bacteria deep in the trachea, whereas we used a syringe into the nostrils. Thus, the number of chlamydiae invading the circulation in our model would be quite low and possibly mimic the situation in humans more closely than the study of Fong et al. (7). The inflammatory reaction of the lungs was also milder in our study than in the study of Fong et al. (7). Interestingly, both pulmonary and arterial lesions, which were severe and lethal in some cases, were only seen in the animals after the reinfection. In humans, the most severe pneumonias caused by *C. pneumoniae* are similarly reinfections (17). Whether reinfections promote or are essential for the development of atherosclerosis in humans remains to be studied.

Our results provide further evidence on the putative role of *C. pneumoniae* in the development of atherosclerosis. It has been demonstrated (10, 18–20, 26, 28, 30, 35, 38) and even isolated in human atherosclerotic lesions (30); it has been cultivated in pure culture; and in the study reported here, when inoculated into rabbits, it induced arterial inflammatory lesions resembling atherosclerosis in experimental animals, and its presence in the produced lesions was demonstrated. The mod-

el that we developed for this study provides possibilities to study the infection-induced atherosclerotic changes, the properties of the infecting chlamydiae, and the effect of antichlamydial therapy. We believe that these results will serve as an impetus to intervention studies with antibiotics effective against chlamydiae. There is a possibility that antibiotics are effective against chronic *C. pneumoniae* infection and, further, against morbidity and mortality from cardiovascular diseases.

ACKNOWLEDGMENTS

We are grateful for Leena Liesirova, Mika Paldanius, and Tuula Hiatalahti, for skillful technical assistance.

We thank the Juselius Foundation for financial support.

REFERENCES

- Anitschkow, N. N., and S. Chalutow. 1913. Über experimentelle cholesterinsteatose und ihre bedeutung für die entstehung einiger pathologische prozesse. *Z. Allg. Pathol. Pathol. Anat.* **24**:1-9.
- Cles, L., and W. Stamm. 1990. Use of HL cells for improved isolation and passage of *Chlamydia pneumoniae*. *J. Clin. Microbiol.* **28**:938-940.
- Dahlén, G. H., J. Boman, L. S. Birgander, and B. Lindblom. 1995. Lp(a) lipoprotein, IgG, IgA and IgM antibodies to *Chlamydia pneumoniae* and HLA class II genotype in early coronary artery disease. *Atherosclerosis* **114**:165-174.
- Dailey, S. J., K. F. Kemp, J. R. Guyton, and K. A. Rogers. 1994. Cholesterol-fed and casein-fed rabbit models of atherosclerosis. *Arterioscler. Thromb.* **14**:105-114.
- Ekman, M. R., J. T. Grayston, R. Visakorpi, M. Kleemola, C. C. Kuo, and P. Saikku. 1993. An epidemic of infections due to *Chlamydia pneumoniae* in military conscripts. *Clin. Infect. Dis.* **17**:420-425.
- Faxon, D. P., V. J. Weber, C. Haudenschild, S. B. Gottsman, W. A. MacGovern, and J. T. Ryan. 1982. Acute effects of transluminal angioplasty in three experimental models of atherosclerosis. *Arteriosclerosis* **2**:125-133.
- Fong, I. W., B. Chiu, E. Viira, M. W. Fong, D. Jang, and J. Mahony. 1997. Rabbit model for *Chlamydia pneumoniae* infection. *J. Clin. Microbiol.* **35**:48-52.
- Gaydos, C. A., J. T. Summersgill, N. N. Sahney, J. A. Ramirez, and T. C. Quinn. 1996. Replication of *Chlamydia pneumoniae* in vitro in human macrophages, endothelial cells, and aortic artery smooth muscle cells. *Infect. Immun.* **64**:1614-1620.
- Godzik, K. L., E. R. O'Brien, S. K. Wang, and C.-C. Kuo. 1995. In vitro susceptibility of human vascular wall cells to infection with *Chlamydia pneumoniae*. *J. Clin. Microbiol.* **33**:2411-2414.
- Grayston, J. T. 1995. *Chlamydia pneumoniae* (TWAR) in atherosclerosis of the carotid artery. *Circulation* **92**:3397-3400.
- Hahn, D. L., R. W. Dodge, and R. Golubjatnikov. 1991. Association of *Chlamydia pneumoniae* (strain TWAR) infection with wheezing, asthmatic bronchitis, and adult-onset asthma. *JAMA* **266**:225-230.
- Hammerschlag, M. R., K. Chirgwin, P. M. Roblin, M. Gelling, W. Dumornay, L. Mandel, P. Smith, and J. Schachter. 1992. Persistent infection with *Chlamydia pneumoniae* following acute respiratory illness. *Clin. Infect. Dis.* **14**:178-182.
- Hsu, S. M., L. Raine, and H. Franger. 1981. A comparative study of the peroxidase-antiperoxidase method and an avidin-biotin complex method for studying polypeptide hormones with radioimmunoassay antibodies. *Am. J. Clin. Pathol.* **75**:734-738.
- Kaukoranta-Tolvanen, S.-S., K. Laitinen, P. Saikku, and M. Leinonen. 1994. *Chlamydia pneumoniae* multiplies in human endothelial cells *in vitro*. *Microb. Pathog.* **16**:313-319.
- Kaukoranta-Tolvanen, S.-S., A.-M. Teppo, K. Laitinen, P. Saikku, K. Linnavuori, and M. Leinonen. 1996. Growth of *Chlamydia pneumoniae* in cultured human peripheral blood mononuclear cells and induction of a cytokine response. *Microb. Pathog.* **21**:215-221.
- Kaukoranta-Tolvanen, S.-S., T. Ronni, M. Leinonen, P. Saikku, and K. Laitinen. 1996. Expression of adhesion molecules on endothelial cells stimulated by *Chlamydia pneumoniae*. *Microb. Pathog.* **21**:407-411.
- Kauppinen, M., and P. Saikku. 1995. Pneumonia due to *Chlamydia pneumoniae*: prevalence, clinical features, diagnosis and treatment. *Clin. Infect. Dis.* **21**:44-52.
- Kuo, C. C., A. M. Gown, E. P. Benditt, and J. T. Grayston. 1993. Detection of *Chlamydia pneumoniae* in aortic lesions of atherosclerosis by immunocytochemical stain. *Arterioscler. Thromb.* **13**:1501-1504.
- Kuo, C. C., A. Shor, L. A. Campbell, H. Fukushi, D. L. Patton, and J. T. Grayston. 1993. Demonstration of *Chlamydia pneumoniae* in atherosclerotic lesions of coronary arteries. *J. Infect. Dis.* **167**:841-849.
- Kuo, C. C., J. T. Grayston, L. A. Campbell, Y. A. Goo, R. W. Wissler, and E. P. Benditt. 1995. *Chlamydia pneumoniae* (TWAR) in coronary arteries of young adults (15-34 years old). *Proc. Natl. Acad. Sci. USA* **92**:6911-6914.
- Kuo, C. C., L. A. Jackson, L. A. Campbell, and J. T. Grayston. 1995. *Chlamydia pneumoniae* (TWAR). *Clin. Microbiol. Rev.* **8**:451-461.
- Lambert, G. F., J. P. Miller, R. T. Olsen, and D. V. Frost. 1958. Hypercholesterolemia and atherosclerosis induced in rabbits by purified high fat rations devoid of cholesterol. *Proc. Soc. Exp. Biol. Med.* **97**:544-549.
- Linnanmäki, E., M. Leinonen, K. Mattila, H. M.-R. Ekman, M. S. Nieminen, V. Valtonen, and P. Saikku. 1993. Presence of *Chlamydia pneumoniae* specific antibodies in circulating immune complexes in coronary heart disease. *Circulation* **87**:1130-1134.
- Miettinen, H., S. Lehto, P. Saikku, S. M. Haffner, T. Rönnemaa, K. Pyörälä, and M. Laakso. 1996. Association of *Chlamydia pneumoniae* and acute coronary heart disease events in non-insulin-dependent-diabetic and non-diabetic subjects in Finland. *Eur. Heart J.* **17**:682-688.
- Molestina, R., R. D. Miller, J. T. Summersgill, and J. A. Ramirez. 1996. *Chlamydia pneumoniae* stimulates secretion of chemokines and adhesion molecules in human endothelial cells, abstr. 243. *In Abstracts of the 96th General Meeting of the American Society for Microbiology 1996*. American Society for Microbiology, Washington, D.C.
- Muhlestein, J. B., E. H. Hammond, J. F. Carlquist, E. Radicke, M. J. Thomson, L. A. Karagounis, M. L. Woods, and J. F. Anderson. 1996. Increased incidence of *Chlamydia* species within the coronary arteries of patients with symptomatic atherosclerotic versus other forms of cardiovascular disease. *J. Am. Coll. Cardiol.* **27**:1555-1561.
- Nurminen, M., M. Leinonen, P. Saikku, and P. H. Mäkelä. 1988. The genus-specific antigen of *Chlamydia*: resemblance to the lipopolysaccharide of enteric bacteria. *Science* **220**:1279-1281.
- Ong, G., B. J. Thomas, A. O. Mansfield, B. R. Davidson, and D. Taylor-Robinson. 1996. Detection and widespread distribution of *Chlamydia pneumoniae* in the vascular system and its possible implications. *J. Clin. Pathol.* **49**:102-106.
- Patel, P., M. A. Mendall, D. Carrington, D. Strachan, E. Leatham, N. Molineaux, J. Levy, C. Blakeston, C. A. Seymour, A. J. Camm, and T. C. Northfield. 1995. Association of *Helicobacter pylori* and *Chlamydia pneumoniae* infections with coronary heart disease and cardiovascular risk factors. *Br. Med. J.* **311**:711-714.
- Ramirez, J., and the *Chlamydia pneumoniae/Atherosclerosis Study Group*. 1996. Isolation of *Chlamydia pneumoniae* from the coronary artery of a patient with coronary atherosclerosis. *Ann. Intern. Med.* **125**:979-982.
- Richardson, M., E. M. Kurowska, and K. K. Carroll. 1994. Early lesion development in the aortas of rabbits fed low-fat, cholesterol-free, semipurified casein diet. *Atherosclerosis* **107**:165-178.
- Ross, R. 1986. The pathogenesis of atherosclerosis—an update. *N. Engl. J. Med.* **314**:488-500.
- Saikku, P., M. Leinonen, K. Mattila, M. R. Ekman, M. Nieminen, P. H. Mäkelä, J. K. Huttunen, and V. Valtonen. 1988. Serologic evidence of an association of a novel *Chlamydia*, TWAR, with chronic coronary heart disease and acute myocardial infarction. *Lancet* **ii**:983-985.
- Saikku, P., M. Leinonen, L. Tenkanen, E. Linnanmäki, M. R. Ekman, M. Manninen, M. Mänttari, and J. K. Huttunen. 1992. Chronic *Chlamydia pneumoniae* infection as a risk factor for coronary heart disease in the Helsinki Heart Study. *Ann. Intern. Med.* **116**:273-278.
- Shor, A., C.-C. Kuo, and D. L. Patton. 1992. Detection of *Chlamydia pneumoniae* in coronary arterial fatty streaks and atheromatous plaques. *S. Afr. Med. J.* **82**:158-160.
- Thom, D. H., J. T. Grayston, D. S. Siscovick, S. P. Wang, N. S. Weiss, and J. R. Daling. 1992. Association of prior infection with *Chlamydia pneumoniae* and angiographically demonstrated coronary artery disease. *JAMA* **268**:68-72.
- Thom, D. H., S. P. Wang, J. T. Grayston, D. S. Siscovick, D. K. Stewart, R. A. Kronmal, and N. S. Weiss. 1991. *Chlamydia pneumoniae* strain TWAR antibody and angiographically demonstrated coronary artery disease. *Arterioscler. Thromb.* **11**:547-551.
- Varghese, P. J., C. A. Gaydos, S. B. Arumugham, D. G. Pham, T. C. Quinn, and C. U. Tuazon. 1995. Demonstration of *Chlamydia pneumoniae* in coronary atheroma specimens from young patients with normal cholesterol from the southern part of India. *Clin. Infect. Dis.* **21**:728. (Abstract.)
- von Hertzen, L., M. Leinonen, H.-M. Surcel, J. Karjalainen, and P. Saikku. 1995. Measurement of sputum antibodies in the diagnosis of acute and chronic respiratory infections associated with *Chlamydia pneumoniae*. *Clin. Diagn. Lab. Immunol.* **2**:454-457.
- Xu, Q., R. Kleindienst, G. Schett, W. Waitz, S. Jindal, R. S. Gupta, H. Dietrich, and G. Wick. 1996. Regression of atherosclerotic lesions induced by immunization with heat shock protein 65-containing material in normocholesterolemic, but not hypercholesterolemic, rabbits. *Atherosclerosis* **123**:145-155.
- Yang, Z. P., C.-C. Kuo, and J. T. Grayston. 1995. Systemic dissemination of *Chlamydia pneumoniae* following intranasal inoculation in mice. *J. Infect. Dis.* **171**:736-738.