

Longevity in Schimke immuno-osseous dysplasia

S Lou, P Lamfers, N McGuire, C F Boerkoel

J Med Genet 2002;**39**:922–925

Schimke immuno-osseous dysplasia (SIOD) is characterised by autosomal recessive inheritance, spondyloepiphyseal dysplasia causing growth retardation, defective cellular immunity, progressive nephropathy leading to renal failure, hyperpigmented macules, and dysmorphic facial features.^{1–16} Half of SIOD patients also have hypothyroidism, half episodic cerebral ischaemia, and a tenth bone marrow failure.³

SIOD is caused by mutations in *SMARCAL1* (SWI/SNF2 related, matrix associated, actin dependent regulator of chromatin, subfamily a-like 1).¹⁷ SNF2 related proteins participate in the DNA nucleosome restructuring which commonly occurs during gene regulation and DNA replication, recombination, methylation, and repair.^{18–19}

Generally SIOD patients surviving past 15–16 years have milder and fewer symptoms than patients dying at younger ages. These older patients do not suffer from hypothyroidism, recurrent infections, bone marrow failure, or central nervous system symptoms such as migraine headaches, transient ischaemic attacks, or strokes but do have spondyloepiphyseal dysplasia, renal disease, and T cell deficiency.³ These older patients have had two *SMARCAL1* alleles with missense mutations, whereas most patients dying at younger ages have had at least one null allele.¹⁷ Based on this, we had hypothesised that patients surviving into adulthood have two hypomorphic alleles of *SMARCAL1* as opposed to null alleles.

Here we review the longevity of 38 patients and the causes of death for 22 patients on whom we have collected detailed clinical data. We also describe a 20 year old woman who has had severe clinical symptoms of SIOD and has two *SMARCAL1* null alleles; this suggests that prolonged survival of severely affected patients with *SMARCAL1* null alleles is possible.

SUBJECTS AND METHODS

Human subjects

Patients referred to this study gave informed consent approved by the Institutional Review Board of Baylor College of Medicine (Houston, TX, USA) or the Hospital for Sick Children (Toronto, ON, Canada). We isolated DNA from peripheral blood. Clinical data, collected from many centres, were obtained from questionnaires, medical records, and summaries completed or provided by the physician responsible.

Mutation screening

We identified mutations in the *SMARCAL1* gene as previously described.¹⁷

CASE REPORT

Patient 570 is a 20 year old woman; she is the oldest child of healthy, consanguineous parents of German, Russian, Irish, and North American native origins. She has a healthy brother.

The proband was born at 36.5 weeks of gestation by spontaneous vaginal delivery. At birth, she was small for gestational age (weight 1814 g (<3rd centile), length 44.5 cm (<3rd centile)). Her subsequent course was complicated by poor growth that initially required nasogastric tube feeding. She has disproportionate short stature (current height 90.8 cm and weight 32.7 kg) with a short neck and trunk. Her

Key points

- Schimke immuno-osseous dysplasia (SIOD, MIM 242900), an autosomal recessive pleiotropic disorder caused by mutations in *SMARCAL1*, has been divided classically into an infantile or severe early onset form and a juvenile or milder later onset form.
- Based on data collected from 33 families, we suggest that the disease severity and onset follow a continuum from early onset and severe symptoms with death early in life to later onset and mild symptoms with survival into adulthood.
- The severity and age of onset do not, however, invariably predict survival because we also report a patient who has survived to 20 years despite having a homozygous *SMARCAL1* nonsense mutation and severe early onset disease.

skeletal radiographs show a spondyloepiphyseal dysplasia with prominent involvement of her acetabula and femoral heads. She had bilateral hip reconstruction at 8 years and bilateral hip replacement at 14 years. Her other features include a broad nasal bridge, bulbous nasal tip, lumbar lordosis, scoliosis, protruding abdomen, and macular hyperpigmented spots on her trunk. Her secondary teeth are small and without roots. Although her development was slowed by chronic illness, she achieved appropriate intellectual, language, social, and motor milestones.

She developed recurrent infections in the first year of life. Her infections have included otitis media, sinusitis, pharyngitis, bacterial pneumonia, respiratory syncytial virus pneumonia, *Pneumocystis carinii* pneumonia, mycoplasma pneumonia, gastroenteritis, herpes zoster, and fungal skin infections as well as an Epstein-Barr virus infection following renal transplantation. Upon evaluation at 5 years of age, she had lymphopenia, severe neutropenia (absolute neutrophil count <54), and anaemia; her bone marrow was hypocellular and showed retarded maturation of myelocytes. Her neutropenia has responded to granulocyte macrophage colony stimulating factor (GM-CSF) and her anaemia to renal transplantation.

By the age of 5 years, she developed proteinuria and by 8 years steroid resistant nephrotic syndrome with hypertension. Her renal biopsy at 7 years of age showed focal segmental glomerulosclerosis, focal tubular atrophy, mesangial hypercellularity and deposits, and segmental capillary loop sclerosis. By 10

Abbreviations: ATR-X, α thalassaemia/mental retardation, X linked; CNS, central nervous system; *ERCC6*, excision repair cross complementing rodent repair deficiency, complementation group 6; PCR, polymerase chain reaction; SIOD, Schimke immuno-osseous dysplasia; *SMARCAL1*, SWI/SNF2 related, matrix associated, actin dependent regulator of chromatin, subfamily a-like 1; *SMARCB1*, swi/snf related matrix associated actin dependent regulator of chromatin subfamily b member 1; SNF2, sucrose non-fermenting yeast homologue 2.

Table 1 Chronology of disease among 37 patients with SIOD

Pedigree No	IUGR	Age (years) at detection of					Cause of death	Current age (years)
		Decreased growth	Recurrent infections	Renal disease	CNS symptoms	Death		
<i>Families with severe disease</i>								
Patients born before 1990								
3	+	0	NA	3.5	5.6	8.5	Stroke	
4a	+	1.5	<3.5	3.5		8	Renal failure	
4b	+	2.5	NA	3		8	Renal failure	
6	+	3.5	+	3.5		5	Pulmonary embolism	
8	+	0	+	4		5.7	Pneumonia	
9	+	5		8		10	CMV encephalitis	
31	+	0		8	11	14	Lymphoproliferative disease	
35	+	0	6	3		8	Renal failure	
39	-	3	4	10	10	15	Stroke	
40	+	0.58		4	5	7	Stroke	
57	+	0	0.25	5	8			20.0
Patients born after 1990								
11	-	2.5	4	3	4	5	Sepsis	
21	-	<5		9	10	12.9	EBV infection	
22	+	<5		6	8	14.6	CMV infection	
23	-	0.5		3.75	4.14			8.7
24	+	0.5	+	5		9	Stroke	
25	+	0.5	+	2	<2			9.7
26	-	2.5	<1	<4	5.25	8	Bone marrow failure	
28	-	2	+	5				11.9
29	+	0	2	2	<3	4	Restrictive lung disease	
30	+	0	5	5	5.7	10	HSV pneumonitis	
32	-	1.66		3	3.8	4.5	Pulmonary embolism	
33a	+	0		1.2		2.75	Bone marrow failure	
33b	+	1		2.25	<1	3.7	Stroke	
38	+	0	2	6.8	+	10.7	Adenovirus	
44	+	0		4				9.5
47	+	0		4				10.7
48	-	0		3	4			6.0
49	+	0	<1	3				7.0
50	+	0		5	4.5			6.5
51	+	0		4.5	5			6.1
53	-	4	5-6	5				10.7
<i>Families with milder disease</i>								
Patients born before 1990								
16	+	0		8				26.1
18a	+	13		11				36.5
18b	+	8		8		12	Pulmonary oedema	
18c	+	12		11				24.0
27	+	<3		10				20.0

CMV, cytomegalovirus; EBV, Epstein-Barr virus; HSV, herpes simplex virus; IUGR, intrauterine growth retardation; NA, information not available; +, symptom present but age of onset not available.
The data from patient 57, whose case history is presented in this manuscript, are shown in bold.

years of age, she required peritoneal dialysis; the same year, she received a living kidney transplant from her father. Her renal transplant has continued to function well despite episodes of graft rejection.

At 8 years of age, she developed symptoms of central nervous system (CNS) vascular impairment including recurrent headaches with nausea, vomiting, blurred vision, hallucinations, and dysosmia. During a hypertensive crisis at 9 years, she had a right occipital stroke. At 15 years, she was diagnosed with a seizure disorder. Although her headaches improved initially with depakote therapy, the headaches subsequently worsened and are now treated with anti-migrainoids.

She has normal thyroid function, a normal karyotype, and no evidence of autoimmune disease except for an isolated raised anti-neutrophil antibody titre. She requires corrective lenses for myopia.

RESULTS

As shown in table 1, the severity of SIOD constitutes a continuum from severe early onset disease to milder later onset disease.¹⁻¹⁶ In our cohort, the subset of patients at the mild end of the spectrum were as likely to have intrauterine growth retardation as those with more severe disease. Except for one

patient who died from pulmonary oedema secondary to nephropathy, the mildly affected patients survived beyond 20 years of age. Although improving medical care might suggest prolonged survival of severely affected patients, dead patients born after 1990 did not live longer (mean 7.7 years) than those born before 1990 (mean 8.9 years). Consistent with improving medical care though, none of the patients born after 1990 died primarily of renal failure, whereas three did before 1990. The patients born after 1990 died of other complications: infection (T cell deficiency), bone marrow failure, and stroke.

As with the severe early onset form of SIOD, patient 570 had growth retardation from birth and developed early recurrent infections, renal failure, and cerebral ischaemia (table 1). Of the patients with severe disease who were born before 1990, she is the only surviving patient whom we have identified. She is homozygous for transition 955C>T and both of her parents are heterozygous (fig 1A). By conceptual translation, 955C>T causes the nonsense mutation Q319X. We did not observe this mutation in 134 North American control chromosomes.

DISCUSSION

The pleiotropy of SIOD suggests mutation of a protein regulating the expression of many genes.²⁰⁻²¹ We recently identified mutations in the SNF2 related protein SMARCA1 as a

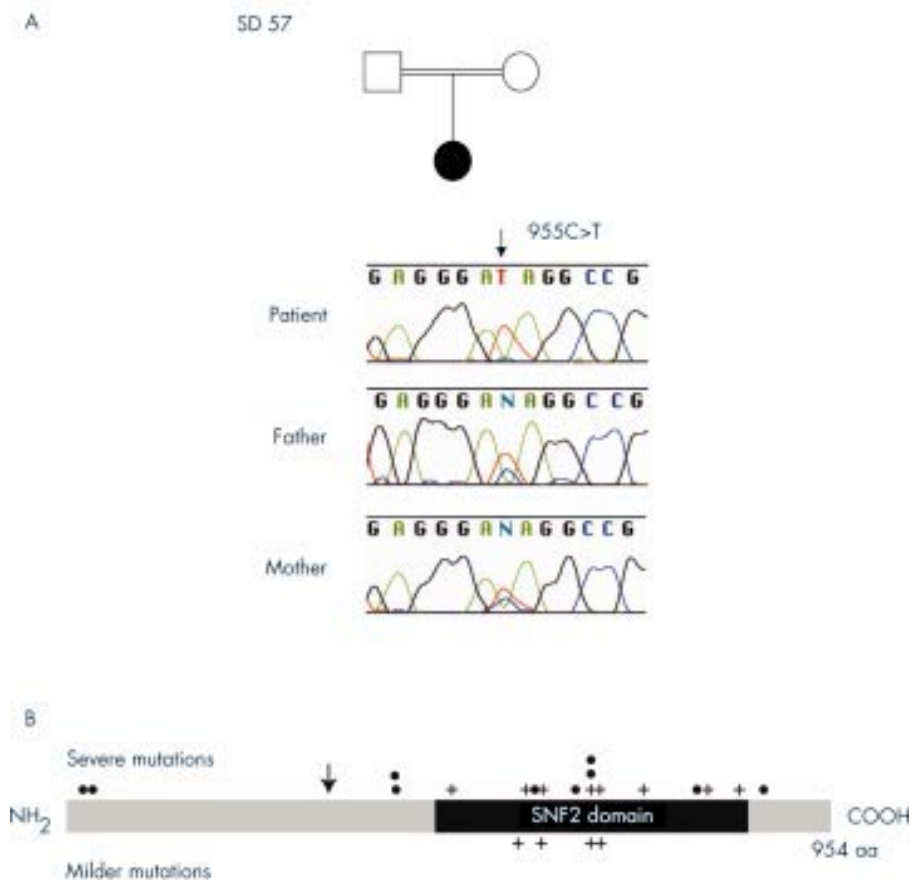


Figure 1 (A) Chromatograms of the *SMARCAL1* alterations identified in family 57. Black symbols indicate SIOD. Patient SD570 is homozygous for mutation Q319X. The parents are second cousins. (B) Diagram of the *SMARCAL1* protein showing the locations of single base mutations that we have identified among SIOD patients. Each mutation is depicted only once regardless of how many independent alleles it was identified in. Nonsense and frameshift mutations are represented by dots and missense mutations by crosses. The location of the nonsense mutation found in patient 570 is shown by an arrow. Large deletions and splicing mutations are not depicted. aa, amino acid; NH₂, amino terminal; COOH, carboxyl terminal.

cause of SIOD and hypothesize that *SMARCAL1* represses or enhances the expression of genes necessary for skeletal development as well as for the maintenance of renal tissue, arterial intima, and T cells.

The identification of SIOD as a disorder of chromatin remodelling has provided the first insight into why SIOD has been refractory to medical therapy and often relentlessly progressive. However, our patient 570 has survived into adulthood with medical support although she has two nonsense mutations in *SMARCAL1* and severe early onset disease. Comparison of her genotype with that of other severely affected patients identified others with similar truncating mutations in *SMARCAL1*, some upstream and some downstream of her mutation (fig 1B). Furthermore, a comparison of her phenotype to that of other severely affected patients did not show a delayed onset for her symptoms of SIOD. These observations show that some patients with severe SIOD survive into adulthood, although we have been unable to identify clinical or genotypic predictors of survival, except that patient 570 received prophylactic antibiotic therapy and her infections were treated early and aggressively.

ACKNOWLEDGEMENTS

We thank the families described for their cooperation. We thank the physicians Jean-Luc André, Paul J Benke, Radovan Bogdanovic, Antoine Burguet, Sandra Cockfield, Isabel Cordeiro, Stefan Fründ, Friederike Illies, Mark Joseph, Ilkka Kaitila, Giuliana Lama, Bruno Leheup, D Ross McLeod, David V Milford, Elizabeth M Petty, Francisco Rodrigo, Jorge M Saraiva, Beate Schmidt, Graham C Smith, Jürgen Spranger,

Anja Stein, Hannelore Thiele, Rosanna Weksberg, and Neza Zupancic for providing data used to define patient longevity. We thank H Bellen for his support and critical review of this manuscript. This study was supported by grants to CFB from the March of Dimes and the National Institute of Diabetes, Digestive, and Kidney Diseases, NIH.

Authors' affiliations

S Lou, C F Boerkoel, Department of Molecular and Human Genetics, Baylor College of Medicine, Houston, Texas, USA
P Lamfers, N McGuire, Mercy Pediatrics and Adolescent Clinic, Clear Lake, Iowa, USA

Correspondence to: Dr C F Boerkoel, Department of Molecular and Human Genetics, One Baylor Plaza, Room T634, Houston, TX 77030, USA; boerkoel@bcm.tmc.edu

REFERENCES

- 1 **Bayer M**, Baxova A, Olejar T, Kozlowski K. Schimke immuno-osseous dysplasia: a case report. *Radiol Med (Torino)* 1998;**95**:369-71.
- 2 **Boerkoel CF**, Nowaczyk MJ, Blaser SI, Meschino WS, Weksberg R. Schimke immunoosseous dysplasia complicated by moyamoya phenomenon. *Am J Med Genet* 1998;**78**:118-22.
- 3 **Boerkoel CF**, O'Neill S, Andre JL, Benke PJ, Bogdanovic R, Bulla M, Burguet A, Cockfield S, Cordeiro I, Ehrich JH, Frund S, Geary DF, Ieshima A, Illies F, Joseph MW, Kaitila I, Lama G, Leheup B, Ludman MD, McLeod DR, Medeira A, Milford DV, Ormala T, Rener-Primec Z, Santavá A, Santos HG, Schmidt B, Smith GC, Spranger J, Zupancic N, Weksberg R. Manifestations and treatment of Schimke immuno-osseous dysplasia: 14 new cases and a review of the literature. *Eur J Pediatr* 2000;**159**:1-7.
- 4 **Bogdanovic R**, Komar P, Cvoric A, Nikolic V, Sinotic M, Zdravkovic D, Ognjanovic M, Abinun M. Focal glomerular sclerosis and nephrotic syndrome in spondyloepiphyseal dysplasia. *Nephron* 1994;**66**:219-24.

- 5 **Ehrich JHH**, Offner G, Shirg E, Helmchen U, Brodel J. Minderwuchssyndrom mit skelettdysplasien und focal segmental sklerosierender glomerulonephritis. *Monatsschr Kinderheilkd* 1988;**136**:6.
- 6 **Ehrich JHH**, Offner G, Schirg E, Hoyer PF, Helmchen U, Brodehl J. Association of spondylo-epiphyseal dysplasia with nephrotic syndrome. *Pediatr Nephrol* 1990;**4**:117-21.
- 7 **Ehrich JHH**, Burchert W, Schirg E, Krull F, Offner G, Hoyer PF, Brodehl J. Steroid resistant nephrotic syndrome associated with spondyloepiphyseal dysplasia, transient ischemic attacks and lymphopenia. *Clin Nephrol* 1995;**43**:89-95.
- 8 **Gilchrist DM**, Harley FL. Schimke immuno-osseous dysplasia. *J Pediatr* 1992;**120**:497.
- 9 **Hashimoto K**, Takeuchi A, Ieshima A, Takada M, Kasagi M. Juvenile variant of Schimke immunoosseous dysplasia. *Am J Med Genet* 1994;**49**:266-9.
- 10 **Lama G**, Marrone N, Majorana M, Cirillo F, Salsano ME, Rinaldi MM. Spondyloepiphyseal dysplasia tarda and nephrotic syndrome in three siblings. *Pediatr Nephrol* 1995;**9**:19-23.
- 11 **Ludman MD**, Cole DEC, Crocker JFS, Cohen MM. Schimke immuno-osseous dysplasia: case report and review. *Am J Med Genet* 1993;**47**:793-6.
- 12 **Petty EM**, Yanik GA, Hutchinson RJ, Alter BP, Schmalstieg FC, Levine JE, Ginsburg D, Robillard JE, Castle VP. Successful bone marrow transplantation in a patient with Schimke immuno-osseous dysplasia. *J Pediatr* 2000;**137**:882-6.
- 13 **Rottenberg GT**, Shaw DG, Hall CM. Spondyloepiphyseal dysplasia with nephrotic syndrome (Schimke immunoosseous dysplasia). *J Pediatr Ortho B* 1997;**6**:7-10.
- 14 **Saraiva JM**, Dinis A, Resende C, Faria E, Gomes C, Correia AJ, Gil J, da Fonseca N. Schimke immuno-osseous dysplasia: case report and review of 25 patients. *J Med Genet* 1999;**36**:786-9.
- 15 **Schimke RN**, Horton WA, King CR. Chondroitin-6-sulfaturia, defective cellular immunity, and nephrotic syndrome. *Lancet* 1971;ii:1088-9.
- 16 **Spranger J**, Hinkel GK, Stoss H, Thoenes W, Wargowski D, Zepp F. Schimke immuno-osseous dysplasia: a newly recognized multisystem disease. *J Pediatr* 1991;**119**:64-72.
- 17 **Boerkoel CF**, Takashima H, John J, Yan J, Stankiewicz P, Rosenbarker L, Andre JL, Bogdanovic R, Burguet A, Cockfield S, Cordeiro I, Frund S, Illies F, Joseph M, Kaitila I, Lama G, Loirat C, McLeod DR, Milford DV, Petty EM, Rodrigo F, Saraiva JM, Schmidt B, Smith GC, Spranger J, Stein A, Thiele H, Tizard J, Weksberg R, Lupski JR, Stockton DW. Mutant chromatin remodeling protein SMARCAL1 causes Schimke immuno-osseous dysplasia. *Nat Genet* 2002;**30**:215-20.
- 18 **Havas K**, Whitehouse I, Owen-Hughes T. ATP-dependent chromatin remodeling activities. *Cell Mol Life Sci* 2001;**58**:673-82.
- 19 **Pazin MJ**, Kadonaga JT. SWI2/SNF2 and related proteins: ATP-driven motors that disrupt protein-DNA interactions? *Cell* 1997;**88**:737-40.
- 20 **Semenza GL**. *Transcription factors and human disease*. New York: Oxford University Press, 1999.
- 21 **Gibbons RJ**, Picketts DJ, Higgs DR. Syndromal mental retardation due to mutations in a regulator of gene expression. *Hum Mol Genet* 1995;**4**:1705-9.

Find out what's in the latest issue
the moment it's published

Email Alerts

Sign up to receive the table of contents by email every month. You can select from three alerts: Table of Contents (full), TOC Awareness (notice only); *Journal of Medical Genetics* related announcements.

www.jmedgenet.com