

Thrombocytopenia-absent radius syndrome: a clinical genetic study

K L Greenhalgh, R T Howell, A Bottani, P J Ancliff, H G Brunner,
C C Verschuuren-Bemelmans, E Vernon, K W Brown, R A Newbury-Ecob

J Med Genet 2002;**39**:876–881

See end of article for authors' affiliations

Correspondence to:
Dr R A Newbury-Ecob,
Department of Clinical
Genetics, Level B, St
Michael's Hill, Southwell
Street, Bristol BS2 8EG,
UK; ruth.newbury-ecob@
ubht.swest.nhs.uk

Revised version received
5 August 2002
Accepted for publication
10 August 2002

The thrombocytopenia-absent radius (TAR) syndrome is a congenital malformation syndrome characterised by bilateral absence of the radii and a thrombocytopenia. The lower limbs, gastrointestinal, cardiovascular, and other systems may also be involved. Shaw and Oliver in 1959 were the first to describe this condition, but it was Hall *et al* in 1969 who reported the first major series of patients. Since then most reports have been based on single or small numbers of cases. We report the results of a clinical study looking at the phenotype of 34 patients with TAR syndrome. All cases had a documented thrombocytopenia and bilateral radial aplasia, 47% had lower limb anomalies, 47% cow's milk intolerance, 23% renal anomalies, and 15% cardiac anomalies. Congenital anomalies not previously described in association with TAR syndrome included facial capillary haemangiomas, intracranial vascular malformation, sensorineural hearing loss, and scoliosis. Karyotype analysis, chromosome breakage studies including premature centromeric separation and fluorescence in situ hybridisation studies looking for a deletion of chromosome 22q11 were undertaken. Two abnormal karyotypes were identified.

Hall *et al*¹ set the current diagnostic criteria for TAR syndrome in 1969 but it was first described by Shaw and Oliver in 1959.² These include bilateral absence of the radii in the presence of both thumbs and a thrombocytopenia (fig 1). The presence of the thumbs distinguishes TAR syndrome from other disorders featuring radial aplasia, which are usually associated with absent thumbs.¹ Bilateral absence of the radii may be accompanied by ulnar or humeral anomalies and the most severe cases exhibit phocomelia.³ Lower limb involvement is variable and includes dislocation of the patella and/or of the hips, absent tibiofibular joint, and lower limb phocomelia.^{1,4} Hall⁵ showed that correlation exists between the severity of upper limb and lower limb abnormalities. Published figures for the frequency of lower limb involvement vary.^{1,4}

Thrombocytopenia, which may be transient, is seen in all cases and will be symptomatic in over 90% of cases within the first four months of life.¹ Gastrointestinal bleeding and occasionally intracerebral bleeding may result. The advent of platelet infusions has helped to prevent the latter, which was previously the main cause of mortality. The platelet count tends to rise as the child gets older and may approach normal levels in adulthood.¹ The aetiology of the thrombocytopenia is unknown. Bone marrow examinations have shown a normal or hypercellular bone marrow with very low, absent, or immature megakaryocytes.^{2,5}

Studies have noted a high incidence (62%) of cow's milk intolerance, which presents as persistent diarrhoea and failure to thrive.^{4,6,7} An episode of thrombocytopenia may be precipitated by introduction of cow's milk, and relieved by its exclusion from the diet.⁶

Between 22 and 33% of children with TAR syndrome are reported as having congenital heart disease, tetralogy of Fallot and atrial septal defects being the most commonly reported lesions.^{1,4}

The genetic basis of TAR syndrome is uncertain. Evidence for autosomal recessive inheritance comes from the reports of 11 families with at least two affected children born to unaffected parents.^{1,2,8–12} Cases associated with consanguinity are rare with only three sib pairs reported.^{8,13,14} Other evidence

casts doubt on this mode of transmission. Boelskov-Edelberg *et al*¹¹ reported a family with a proband affected with typical TAR syndrome. This child had two affected second cousins, one with typical TAR syndrome and one more severely affected with phocomelia. Hall *et al*¹ reported a family with two affected sibs and two unaffected sibs. One of the unaffected subjects had a child affected with typical TAR syndrome. There has also been some suggestion that other family members may have subtle signs of TAR, for example, limited pronation and supination or radial shortening. Schnur *et al*¹⁵ reported TAR in an uncle and nephew. The proband had typical TAR syndrome, while his maternal uncle had bilateral radial aplasia with normal thumbs. A maternal aunt had mild radial hypoplasia. This led the authors to speculate that TAR may be inherited as an autosomal dominant condition with variable penetrance.

In view of the phenotypic overlap with Roberts syndrome, Hall⁵ suggested that TAR and Roberts syndrome might be allelic, TAR being caused by compound heterozygosity for a mild and a severe mutation and Roberts syndrome by homozygosity for the severe mutation.

Considerable overlap occurs between TAR syndrome and other syndromes featuring radial aplasia. In order to provide accurate genetic counselling, it is essential to make a correct diagnosis. A number of published cases do not fulfil Hall's diagnostic criteria.^{8,16} The most important conditions to differentiate from it are Holt-Oram syndrome (HOS),¹⁷ Roberts syndrome,¹⁸ Fanconi anaemia,¹⁹ thalidomide embryopathy,^{1,20} and Rapadilino syndrome.²¹

It is possible that some previous cases of TAR syndrome may have had a deletion of chromosome 22q11 since many were reported before testing became available. Radial aplasia, cardiac defects, particularly conotruncal defects, and thrombocytopenia are all part of the spectrum of this condition.^{22,23}

ASCERTAINMENT

Patients were recruited to the study through Clinical Genetic Services. Inclusion criteria were set as bilateral absence of the radii in the presence of both thumbs and a documented

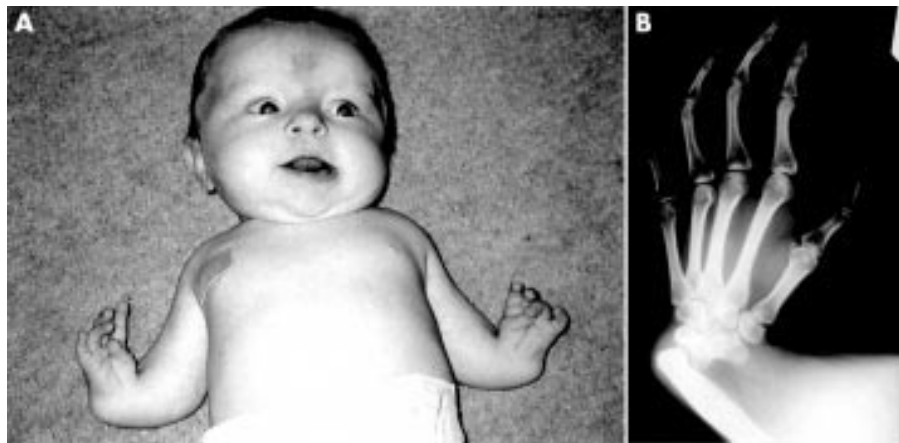


Figure 1 (A) A young affected child. Note the radial deviation of both hands and presence of both thumbs. This child has a capillary haemangioma in the glabellar region. The plaster above her right nipple covers the entry point for a central venous access line. (B) X ray showing radial aplasia in an adult. Note that the bones of the hand appear normal.

thrombocytopenia. The South West Multicentre Research Ethics Committee granted ethical approval. Clinical information, including detailed pedigree analysis, medical history, and examination, were obtained by visiting the patient, correspondence directly with the patient, and from access to medical records. Blood samples were taken for karyotype analysis including fluorescence in situ hybridisation for a chromosome 22q11 deletion, Fanconi anaemia screen, and examination for premature chromosome separation (PCS). A full blood count was also taken.

RESULTS

Haematology

All cases (34) had a documented thrombocytopenia with a platelet count less than 150×10^9 per litre. The platelet count at birth was documented in 17 cases and ranged from 7×10^9 per litre to 92×10^9 per litre. In 14 cases (82%) the platelet count was equal to or below 50×10^9 per litre. The platelet count fluctuates over time in child and adulthood. If there is a strong

clinical suspicion of TAR syndrome with a normal platelet count then this should be repeated, as a thrombocytopenia may be documented at a later date.

Limb abnormalities

All cases had bilateral radial aplasia. Both thumbs were present but were either hypoplastic or proximally placed. The upper limb defects can be divided into three categories according to severity (figs 1 and 2). The first group consists of mildly affected subjects presenting with radial aplasia associated with varying degrees of hypoplasia of the ulna and humerus (20/28 (71%)). These patients tended to have a normal shoulder girdle and therefore near normal upper body strength. The second group of moderately affected patients had a greater degree of limb shortening and hypoplasia of the humerus, associated with underdevelopment of the shoulder girdle and reduced strength (5/28 (18%)). In both groups patients reported difficulties with pronation and supination and often found splints useful for prolonged periods of upper limb activity. The final group of most

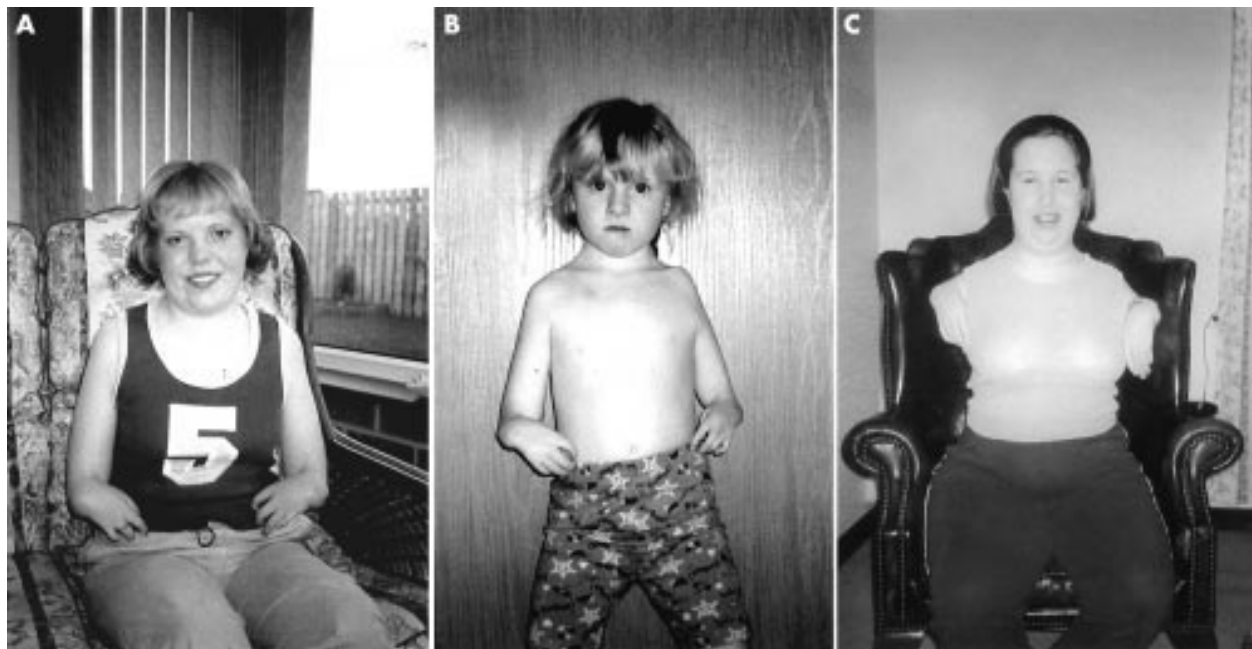


Figure 2 (A) Adult with mild upper limb abnormality. Note the reasonable length of the arms and the well formed shoulder girdle. Also note the high forehead. (B) Child with moderate upper limb abnormality. The shoulder girdle is less well formed than in (A). (C) This child has phocomelia. Note the tall, broad forehead seen in cases of TAR syndrome.

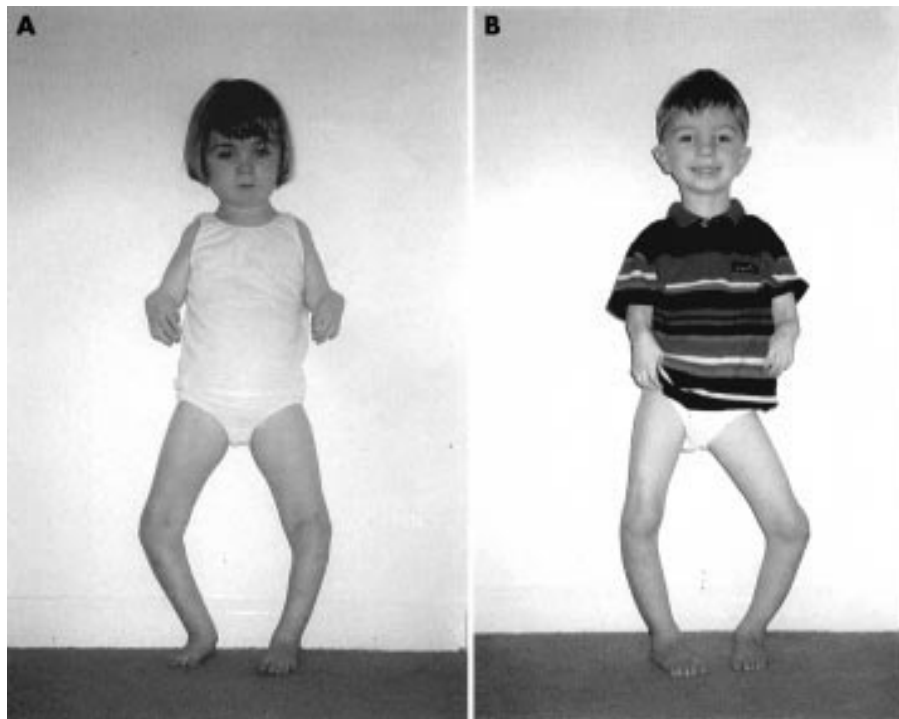


Figure 3 (A, B) Lower limb involvement in two children. Note the severe bowing of the legs. Both of these children wear full length leg braces to stabilise and aid walking.

severely affected patients had severe ulnar and humeral shortening with phocomelia (3/28 (11%)). Cases within all three groups used appliances for various activities of daily living such as dressing and grasping objects. Limb length correlated inversely with independence for daily activities, for example, dressing, toileting, and eating.

Of the 28 cases where details of the lower limbs are known, 13 (47%) had lower leg anomalies (fig 3). These ranged from mild abnormalities, such as a small patella leading to subluxation of the knee joint in four cases, to more severe abnormalities causing bowing of the lower leg, associated with hip, knee, and ankle abnormalities affecting mobility in seven cases. Five cases needed to wear full length leg splints and supportive boots to aid mobilisation. Reduction defects were seen in two cases. The functional consequence of limb reduction depended on the limb length. Owing to the weight bearing function of the lower limbs the lower leg anomalies may be more disabling than those of the upper limbs.

Surgical history was available in 20 cases. Eleven patients (55%) had undergone surgery. Six patients (30%) underwent surgery on their upper limb only. In five cases this was a procedure to centralise the hand on the wrist (a procedure requiring multiple operations) and in one case release of skin webbing in the antecubital fossa. In three cases (15%) surgery was carried out on the lower limb only. The surgical procedures varied but the aim of all three was to realign the leg bones making the leg straighter and more stable. Two cases (10%) had surgery on both upper and lower limbs.

Gastrointestinal system

Gastrointestinal problems were common. Fourteen cases (47%) had cow's milk intolerance, presenting as poor weight gain and vomiting, which necessitated substitution of cow's milk by soy or goat's milk. Moderate intolerance presenting as failure to thrive and diarrhoea requiring complete substitution with non-cow's milk derivative feeds was seen in five cases (17%). A severe intolerance requiring total parenteral nutrition was found in two cases (7%). Nine cases (30%) were described as having an increased susceptibility to gastroenteritis leading to dehydration requiring intravenous fluids.

Gastroenteritis can also precipitate symptomatic thrombocytopenia. Cow's milk intolerance and episodes of gastroenteritis tended to improve with age.

Genitourinary system

Renal anomalies occurred in seven cases (23%) and included one case with duplex ureter, one case with mild renal pelvis dilatation, and two cases of horseshoe kidneys (table 1). One case of TAR syndrome developed a Wilms tumour with a nephrogenic rest in the contralateral kidney. Functional problems included one case of mild ureterovesical reflux and one case of recurrent pyelonephritis requiring a nephrectomy.

Cardiac anomalies

Cardiac anomalies were seen in five (15%) cases and included one patient with an atrial septal defect (ASD), one with a ventricular septal defect (VSD), one with an atrioventriculoseptal defect (AVSD), and one with a VSD and a patent ductus arteriosus (PDA). A fifth patient died in the neonatal period from complex congenital heart disease; further details are not known.

Growth

Growth parameters were available for 21 patients. Sixteen cases (76%) had a head circumference that was at least two centiles larger than their centile for height. Twenty (95%) had a height on or below the 50th centile.

Learning difficulties

Learning difficulties were seen in only one case. She had moderate learning difficulties and additional congenital malformations including absent uterus, ovarian agenesis, asymmetrical breast development, horseshoe kidney, and a possible sacral neural tube defect. Thrombocytopenia was detected in the first few months of life. There was no evidence that this child had suffered from an intracerebral bleed as a neonate. In view of these atypical features further investigation using multi-subtelomere fluorescent in situ hybridisation probes was undertaken and no abnormalities were found.

Table 1 Features of TAR syndrome in 34 patients compared with previous studies

Feature	This study	Previous studies	Reference
Bilateral radial aplasia	100%	100%	1
Thrombocytopenia	100%	100%	1
Cow's milk intolerance	47%	62%	4, 6, 7
Lower leg involvement	47%	40%	4
Cardiac anomaly	15%	22–33%	1, 4
Renal anomaly	23%	3%	1
Cleft palate	3%	1 case	28
Uterine +/- genital anomaly	6%	3%	1
Facial capillary haemangioma	24%		
Intracranial vascular malformation	3%		
Sensorineural hearing loss	3%		
Epilepsy	6%		
Scoliosis	3%		
Neural tube defect	3%	1 case	1

Dysmorphology

Fifty-three percent of cases had dysmorphic features consisting of a combination of micrognathia, a tall, broad forehead, and low, posteriorly rotated ears (figs 1, 2, and 3).

Additional features

This study has identified features previously not associated with TAR syndrome (table 1). Eight cases (24%) had a central facial capillary haemangioma (fig 1). Two cases had epilepsy and one an intracranial vascular malformation. Two cases had absent uterus, which in one case was associated with unilateral ovarian agenesis. One case had a sensorineural hearing loss, one case a cleft palate, and one case a scoliosis.

Natural history

Of the 34 patients in this study, two died prematurely. One case died from complex congenital heart disease in the neonatal period. The second case had a VSD, but the cause of death was an intracerebral haemorrhage at 3 months of age.

Genetics

Thirty-four affected subjects came from 30 families, with 58 offspring in total. In 20 families the proband was the first born. Only 13 families went on to have further children after the birth of an affected child. No consanguinity was identified. Using a similar approach to Thompson *et al.*,²⁴ the empiric recurrence risk was calculated. Thirteen probands had 20 sibs of whom four were affected with TAR syndrome. Hence the empiric recurrence risk was 4/20 or 20%. An increased incidence of females was found with a ratio of 27:7 ($\chi^2=11.8$, $p<0.05$). Two of the three adults included in this cohort reproduced and both had a single unaffected female child. One of these adults was female and she had no pregnancy or delivery complications.

Cytogenetics

Chromosome analysis was carried out on 16 cases. Two abnormal karyotypes were found. One case had a karyotype 46,XY,dup(8)(p23.1p23.1). Parental chromosome analysis showed that the duplication was maternally inherited. This case had typical TAR syndrome with no unusual features. Barber *et al.*²⁵ in 1998 reported this duplication as being of no pathological significance. The second abnormal karyotype was a de novo translocation, 46,XY,t(1;7)(q42;p15). This child developed a Wilms tumour with a nephrogenic rest in the other kidney and was the subject of a case report by Hewitt *et al.*²⁶ in 1991. No microdeletion of chromosome 22q11 was detected in 10 cases examined. Chromosome breakage studies in 14 cases were normal with no evidence of PCS.

DISCUSSION

This study has reiterated the findings of Hall *et al.*¹ as regards the major clinical manifestations and diagnostic criteria of TAR syndrome. The pattern of upper limb anomalies seen is variable, but bilateral radial aplasia is a constant feature. The incidence of lower limb involvement in this study (47%) was similar to that quoted by Hedberg *et al.*⁴ Tetraphocomelia, as severe as that seen in Roberts syndrome, may be seen. This study emphasised the functional disability encountered by those affected with TAR syndrome. The functional ability of the upper limbs depends on the longitudinal length. Most arm movements except pronation and supination can be performed. The functional ability of the lower limbs can be very variable but some cases find that their lower limb anomalies have a greater impact on their lives by affecting their mobility. Surgical procedures and surgical appliances may help to overcome some of the functional problems.

Although all patients had a documented thrombocytopenia, the fluctuating platelet counts over time mean that if there is a strong clinical suspicion of TAR syndrome with a normal platelet count then it should be repeated. A single normal platelet count does not exclude TAR syndrome.

Whitfield and Barr⁶ first reported the association between TAR syndrome and cow's milk intolerance in 1976. Hays *et al.*⁷ estimated this in 1982 as affecting 62% of cases. We have documented a lower incidence of cow's milk intolerance (47%), but the susceptibility to recurrent bouts of gastroenteritis reported in 30% of our cases is an important new finding emphasising involvement of the gastrointestinal tract in TAR syndrome.

Previous studies have shown the incidence of cardiac anomalies to be between 22 and 33% (table 1).^{1,4} In this study, only 15% had a reported cardiac anomaly. The higher figure in previous reports might reflect unidentified cases of 22q11 deletion. In the paper of Hall *et al.*,¹ 9/40 patients had known cardiac defects. Two patients not included in this figure had cardiac murmurs, in one associated with cardiomegaly.¹ ASD and tetralogy of Fallot were each seen in three patients making these the most frequent defect seen in the study of Hall *et al.*¹ ASD and VSD defects were the most frequent cardiac anomaly seen in our study. No patient had tetralogy of Fallot.

This study detected renal malformations in 23% of cases, compared with only 3% in the study of Hall *et al.*¹ This difference could possibly be because of improved investigation by renal ultrasound of children presenting with urinary tract infection. A horseshoe kidney was found in two cases, as described by Bradshaw *et al.*²⁷ in 2000. Two cases had an absent uterus, an abnormality not specifically reported before, although Hall *et al.*¹ stated that 3% of her cohort had genital anomalies.

Other previously described abnormalities include a cleft palate, seen in one case in this study.²⁸ Neural tube defects are not generally recognised as part of the TAR spectrum.

However, Hall *et al*¹ included one case with spina bifida. We identified one case with a sacral neural tube defect. Hall *et al*¹ noted facial capillary haemangiomas, but the frequency of these lesions has not been appreciated. There have been no previous reports of an intracranial vascular malformation, sensorineural hearing loss, or scoliosis (table 1). These additional features may aid understanding of gene expression and be a potential clue for the isolation of the TAR gene.

The pattern of limb abnormality and associated features should allow TAR syndrome to be differentiated from other syndromes involving the radial ray. A number of features distinguish Holt-Oram syndrome (HOS) from TAR.¹⁷ In HOS, radial aplasia is associated with absence of the thumb, thrombocytopenia does not occur, and there is often a family history of heart and limb defects. HOS is an autosomal dominant condition caused by mutations in the *TBX5* gene.^{29–31}

Fanconi anaemia is an autosomal recessive disorder causing bone marrow failure, skeletal defects, cutaneous pigmentation, microcephaly, and short stature.¹⁹ Cases may present with thrombocytopenia. Upper limb abnormalities also involve the radial ray. Hypoplastic thumbs may be accompanied by radial hypoplasia but absence of the radius is associated with absence of the thumbs. Spontaneous chromosome breakage is a consistent feature of Fanconi anaemia and is a reliable diagnostic test.³²

Roberts syndrome is a multiple congenital anomaly syndrome consisting of pre- and postnatal growth retardation, facial clefting, and renal and genital abnormalities. Limb defects may affect the upper or lower limbs or both.¹⁸ The majority (79%) of these children have a characteristic chromosome abnormality, that is, premature centromeric separation (PCS) or “puffing” of the chromosomes caused by repulsion of the heterochromatic regions near the centromeres of chromosomes 1, 9, and 16 with splaying of the short arms of the acrocentric chromosomes and of distal Yp.³³ There is also evidence of abnormal mitosis.¹⁸ Roberts syndrome is thought to be inherited as an autosomal recessive trait. Urban *et al*³³ in 1998 postulated that TAR syndrome and Roberts syndrome might be part of the same condition with TAR syndrome being the milder and Roberts the severer variants.

Thalidomide embryopathy may present with radial anomalies of the upper limb. Malformations of the lower limbs show a less consistent pattern.²⁰ Cases are diagnosed on the phenotype and a history of exposure to thalidomide during pregnancy. It is of note that the use of thalidomide as a therapeutic agent is increasing for the treatment of conditions such as Beçhet’s disease,³⁵ graft versus host disease,³⁶ multiple myeloma,³⁷ and Kaposi’s sarcoma.³⁷

Genetics

The inheritance pattern of TAR remains unclear. Evidence for autosomal recessive inheritance comes from the identification of affected sib pairs born to clinically unaffected parents. The number of affected sib pairs in this study (four in 30 families) is comparable to the Hall study, which identified six sib pairs in 31 families. No consanguinity was present in any of the families in this study. The possibility that recurrences may be the result of germinal mosaicism for a new dominant mutation cannot be excluded. The recurrence risk following the birth of an affected child was calculated as 20%, which is lower than one would expect for an autosomal recessive condition. This figure, however, should be interpreted with caution since the birth of an affected child tended to result in limitation of family size. Over half of the families chose not to have further children after having one child affected with TAR syndrome because of fears of recurrence. In 17 (57%), no further sibs were born after an affected child was diagnosed. Of the four sib pairs included in this study, in three cases the second affected case was detected by antenatal ultrasound diagnosis of bilateral radial aplasia. In the fourth sib pair, the

proband died from complex congenital heart disease. Phenotypic concordance is seen in five of the 11 published recurrences.^{1–9,10} The second case in the family was more severely affected in five cases.^{1,2,8,11,12} In the eleventh case the proband had other features not usually associated with TAR syndrome including microcephaly, pectus excavatum, and 11 pairs of ribs.¹⁴ The second case in this family also had a cystic structure below the calvarium and shortening of the femur. This study showed the same excess of affected females (27:7) as was seen in the study of Hall *et al*¹ (26:14). The excess of affected females might suggest a sex linked dominant inheritance with lethality in males.

Phenotypic overlap, in particular the combination of genitourinary abnormalities, facial capillary haemangiomas, and cleft palate will add to the speculation that TAR syndrome and Roberts syndrome may be allelic, TAR syndrome being caused by compound heterozygosity for a mild and a severe mutation and Roberts’ syndrome being caused by homozygosity for severe mutations.³⁴ This would be analogous to the allelic heterogeneity observed with mutations of *DTDST* (diastrophic dysplasia sulphate transporter gene), where three different chondrodysplasias result from different mutations within the same gene.³⁸ Homozygosity for a mild mutation causes diastrophic dysplasia and homozygosity for a severe mutation causes atelosteogenesis type IB. Heterozygosity for one mild and one severe mutation causes atelosteogenesis type II.

In an attempt to understand the genetic basis of the thrombocytopenia associated with TAR syndrome, Ballmaier *et al*³⁹ in 1997 investigated the pathophysiology of thrombocytopenia focusing on thrombopoietin (TPO), the main regulator of thrombopoiesis, and its receptor. Serum levels of TPO were raised but expression of the thrombopoietin receptor (c-mpl) was similar to that of controls. An absence of *in vitro* reactivity to TPO was shown. The authors suggested that the defective platelet production is not the result of lack of TPO production, but to a lack of downstream response in the c-mpl signal transduction pathway.³⁹ Stripploi *et al*⁴⁰ failed to find mutations in the thrombopoietin receptor gene (c-mpl). Letestu *et al*⁴¹ found that the colony forming unit megakaryocyte number was reduced in bone marrow and that a proportion of megakaryocytes were unable to complete terminal differentiation, suggesting that the defect lies in the early stages of megakaryocyte differentiation.⁴¹

Two abnormal karyotypes were identified in the present study by conventional G banding. The first, 46,XY,dup(8)(p23.1p23.1), was considered to be a normal variant.²⁵ The second, 46,XY,t(1;7)(q42;p15), has been the subject of further investigation involving cloning of the translocation breakpoint at 7p and identification of candidate genes (Brown *et al*, personal communication). This forms part of a molecular genetic study aimed at identifying the gene or genes responsible for TAR syndrome.

ACKNOWLEDGEMENTS

We would like to acknowledge the TAR Syndrome Support Group for their help and support in this study and REACH for funding the work by KLG and RNE. EV and KWB are supported by the Association for International Cancer Research and the Cancer and Leukaemia in Childhood charity.

Authors’ affiliations

K L Greenhalgh, R A Newbury-Ecob, Department of Clinical Genetics, Level B, St Michael’s Hill, Southwell Street, Bristol BS2 8EG, UK

R T Howell, South West Regional Cytogenetics Department, Southmead Hospital, Westbury-on-Trym, Bristol BS10 5NB, UK

A Bottani, Division of Medical Genetics, Geneva University Hospital, Rue Michel Servet 1, 1211 Geneva, Switzerland

P J Ancliff, Department of Haematology, Great Ormond Street Hospital, Great Ormond Street, London WC1N 3JH, UK

H G Brunner, Department of Human Genetics, 417 Geert Grootplein

16, 6525 GA Nijmegen, The Netherlands

C C Verschuuren-Bemelmans, Department of Human Genetics, Academic Hospital Groningen, PO Box 30001, 9700 RB Groningen, The Netherlands

E Vernon, K W Brown, Department of Pathology and Microbiology, University of Bristol, School of Medical Sciences, University Walk, Bristol BS8 1TD, UK

REFERENCES

- Hall JG, Levin J, Kuhn JP, Ottenheimer EJ, van Berkum P, McKusick VA. Thrombocytopenia with absent radius (TAR). *Medicine* 1969;**48**:411-39.
- Shaw S, Oliver RAM. Congenital hypoplastic thrombocytopenia with skeletal deformities in siblings. *Blood* 1959;**14**:374-7.
- Anyane-Yeboah K, Jaramillo S, Grebin B. Tetrachomelia in the syndrome of thrombocytopenia with absent radii (TAR syndrome). *Am J Med Genet* 1985;**20**:571-6.
- Hedberg VA, Lipton JM. Thrombocytopenia absent radii. A review of 100 cases. *Am J Pediatr Hematol/Oncol* 1988;**10**:51-64.
- Hall JG. Thrombocytopenia and absent radius (TAR) syndrome. *J Med Genet* 1987;**24**:79-83.
- Whitfield MF, Barr DGD. Cow's milk allergy in the syndrome of thrombocytopenia with absent radius. *Arch Dis Child* 1976;**51**:337-43.
- Hays RM, Bartoshek LE, Feingold M. New features of thrombocytopenia and absent radius syndrome. *Birth Defects* 1982;**18**:115-21.
- Cellballos-Quintal JM, Pinto-Escalante D, Gorgora-Biachi RA. TAR-like syndrome in a consanguineous Mayan girl. *Am J Med Genet* 1992;**43**:815-17.
- Luthy DA, Hall JG, Graham CG. Prenatal diagnosis of thrombocytopenia with absent radii. *Clin Genet* 1979;**15**:495-9.
- Adeyokunnu AA. Radial aplasia and amegakaryocytic thrombocytopenia (TAR syndrome) among Nigerian children. *Arch Dis Child* 1984;**138**:346-8.
- Boelskov Edelberg S, Cohn J, Brandt NJ. Congenital hypomegakaryocytic thrombocytopenia associated with bilateral absence of the radius - the TAR syndrome. *Hum Hered* 1997;**27**:147-52.
- Dell PC, Sheppard JE. Thrombocytopenia, absent radius syndrome: report of two siblings and a review of the hematological and genetic features. *Clin Orth Rel Res* 1982;**162**:128-34.
- Teufel M, Enders H, Dpofor R. Consanguinity in a Turkish family with thrombocytopenia with absent radius (TAR) syndrome. *Hum Hered* 1983;**63**:94-6.
- Shalev E, Weiner E, Feldman E, Cohen H, Zurkerman H. Micrognathia - prenatal ultrasonographic diagnosis. *Int J Gynaecol Obstet* 1983;**21**:343-5.
- Schnur RE, Eunpu DL, Zackai EH. Thrombocytopenia with absent radius in a boy and his uncle. *Am J Med Genet* 1987;**28**:117-23.
- Labrune PH, Pons JC, Khalil M, Mirlesse V, Imbert MC, Odievre M, Daffos F, Tchernia G, Frydman R. Antenatal thrombocytopenia in three patients with TAR (thrombocytopenia with absent radius syndrome). *Prenat Diagn* 1993;**13**:463-6.
- Newbury-Ecob RA, Leanage R, Raeburn JA, Young ID. Holt Oram syndrome: a clinical genetic study. *J Med Genet* 1996;**33**:306-7.
- Van den Berg DJ, Franke U. Roberts syndrome: a review of 100 cases and a new scoring system for severity. *Am J Med Genet* 1993;**47**:1104-23.
- Gaimpietro PF, Alder-Brecher B, Verlander PC, Pavlakis SG, Davis JG, Auerbach AD. The need for more accurate and timely diagnosis in Fanconi anaemia: a report from the international Fanconi anaemia registry. *Pediatrics* 1993;**91**:1116-20.
- Newman CGH. Teratogen update: clinical aspects of thalidomide embryopathy - a continuing preoccupation. *Teratology* 1985;**32**:133-44.
- Kaariainen H, Ryppy S, Norio R. RAPADILINO syndrome with radial and patellar aplasia/hypoplasia as main manifestations. *Am J Med Genet* 1989;**33**:346-51.
- Digilio MC, Giannotti A, Marino B, Guadagni AM, Orzalesi M, Dallapiccola B. Radial aplasia and chromosome 22q11 deletion. *J Med Genet* 1997;**34**:942-4.
- Ryan AK, Goodship JA, Wilson DI, Philip N, Levy A, Seidel H, Schuffenhauer S, Oechsler H, Belohradsky B, Prieur M, Aurias A, Raymond FL, Clayton-Smith J, Hatchwell E, McKeown C, Beemer FA, Dallapiccola B, Novelli G, Hurst JA, Ignatius J, Green AJ, Winter RM, Bruehl L, Brondum-Nielsen K, Stewart F, Van Essen T, Patton M, Patterson J, Scambler PJ. Spectrum of clinical features associated with interstitial chromosome 22q11 deletions: a European collaborative study. *J Med Genet* 1997;**34**:798-804.
- Thompson EM, Young ID, Hall CM, Pembrey ME. Recurrence risks and prognosis in severe sporadic osteogenesis imperfecta. *J Med Genet* 1987;**24**:390-405.
- Barber JCK, Joyce CA, Collinson MN, Nicholson JC, Willart LR, Dyson HM, Bateman MS, Green AJ, Yates JRW, Dennis NR. Duplication of 8p23.1: a cytogenetic abnormality with no established clinical significance. *J Med Genet* 1998;**35**:491-6.
- Hewitt M, Lunt PW, Oakhill A. Wilms' tumour and a de novo (1;7) translocation in a child with bilateral radial aplasia. *J Med Genet* 1991;**8**:411-12.
- Bradshaw A, Donnelly LF, Foreman JW. Thrombocytopenia and absent radii (TAR) syndrome associated with a horseshoe kidney. *Pediatr Nephrol* 2000;**14**:29-31.
- Van Haeringen A, Veenstra F, Maaswinkel-Mooij PD, van de Kamp JJ. Intermittent thrombocytopenia and absent radii: report of a patient with additional unusual features. *Am J Med Genet* 1989;**34**:202-6.
- Li QY, Newbury-Ecob RA, Terrett JA, Wilson DI, Curtis ARJ, Yi CH, Gebuhr T, Bullen PJ, Robson SC, Strachan T, Bonnet D, Lyonnet S, Young ID, Raeburn JA, Buckler AJ, Law DJ, Brook JD. Holt Oram syndrome is caused by mutations in TBX5, a member of the Brachyury (T) gene family. *Nature* 1997;**15**:21-9.
- Basson CT, Cowley GS, Solomon SD, Weissman B, Poznanski AK, Trill TA, Seidman CE. The clinical and genetic spectrum of the Holt Oram syndrome (heart hand syndrome). *N Engl J Med* 1994;**330**:884-91.
- Fryns JP, Bonnet D, de Smet L. Holt Oram syndrome with associated post axial and central polydactyly: further evidence for genetic heterogeneity in the Holt Oram syndrome. *Genet Couns* 1996;**7**:323-4.
- Howell RT. Chromosome instability syndromes. *Human cytogenetics; malignancy and acquired abnormalities. A practical approach*. 3rd ed. Oxford: Oxford University Press, 2001:227-54.
- Allingham-Hawkins DJ, Tomkins DJ. Heterogeneity in Roberts syndrome. *Am J Med Genet* 1996;**55**:188-94.
- Urban M, Opitz C, Bommer C, Enders H, Tinschert S, Witkowski R. Bilaterally cleft lip, limb defect and haematological manifestations: Roberts syndrome versus TAR syndrome. *Am J Med Genet* 1988;**79**:155-60.
- Kari JA, Shah V, Dillon MJ. Bechet's disease in UK children: clinical features and treatment with thalidomide. *Rheum (Oxford)* 2001;**40**:933-8.
- Arora M, Wagner JE, Davies SM, Blazar BR, Defor T, Enright H, Miller WJ, Weisdorf DF. Randomised clinical trial of thalidomide, cyclosporine, and prednisone versus cyclosporine and prednisone as initial therapy for chronic graft-versus-host disease. *Biol Blood Marrow Transplant* 2001;**7**:265-73.
- Singhal S, Mehta J. Thalidomide in cancer: potential uses and limitations. *Biodrugs* 2001;**15**:163-72.
- Hasbacka J, Superti-Furga A, Wilcox WR, Rimoin DL, Cohn DH, Lander ES. Atelosteogenesis type II is caused by mutations in the diastrophic dysplasia sulfate-transporter gene (DTDST): evidence for a phenotypic series involving three chondrodysplasias. *Am J Hum Genet* 1996;**58**:255-62.
- Ballmaier M, Schulze H, Straub G, Cherkaoui K, Wittner N, Lynen S, Wolters S, Bogenberger J, Welte K. Thrombopoietin in patients with congenital thrombocytopenia and absent radii: elevated serum levels, normal receptor expression but defective reactivity to thrombopoietin. *Blood* 1997;**90**:612-19.
- Strippoli P, Savoia A, Iolascon A, Tonelli R, Savino M, Giordano P, D'Avanzo M, Massolo F, Locatelli F, Borgna C, De Mattia D, Zelante L, Paolucci G, Bagnara GP. Mutational screening of thrombopoietin receptor gene (c-mpl) in patients with congenital thrombocytopenia and absent radii (TAR). *Br J Haematol* 1998;**103**:311-14.
- Letestu R, Vitrat N, Masse A, Le Couedic JP, Lazar V, Rameau P, Wendling F, Vuiller J, Boutrad P, Plouvier E, Plasse M, Favier R, Vainchenker W, Debili N. Existence of a differentiation blockage at the stage of a megakaryocyte precursor in the thrombocytopenia and absent radii (TAR) syndrome. *Blood* 2000;**95**:1633-41.