

ELECTRONIC LETTER

Isolated Robin sequence associated with a balanced t(2;17) chromosomal translocation

N Jamshidi, I Macciocca, P A Dargaville, P Thomas, N Kilpatrick, R J McKinlay Gardner, P G Farlie

J Med Genet 2004;41:e1 (<http://www.jmedgenet.com/cgi/content/full/41/1/e1>)

Robin sequence (RS) is a developmental malformation characterised by micrognathia, cleft palate, and glossoptosis, leading to respiratory and feeding difficulties in the majority of affected neonates.^{1,2} These three features constitute the primary diagnostic criteria of RS, although diagnosis on the basis of any two of these three classical features has been suggested.³ Typically the condition occurs sporadically, but it may be familial, in which case the mode of inheritance is autosomal dominant.^{4,5} However, the pathogenetic and phenotypic variability of RS has hampered efforts to establish a clear set of diagnostic criteria,^{3,6,7} making the classification of this anomaly difficult and complicating the effective management and treatment.^{8,9} Hence, the diagnosis of RS presents a challenge from both a clinical and a developmental perspective.

RS has three different manifestations: (a) as part of a known syndrome; (b) in association with other abnormalities that do not constitute a recognisable syndrome (non-syndromic), and (c) in a classical or isolated form not associated with any other significant findings.^{3,6,10} Approximately 20–40% of reported RS cases occur in an isolated form, while between 35 and 70% of cases are syndromic.^{11–15} The most common syndromes associated with RS include Stickler syndrome and velocardiofacial syndrome.^{15,16} While the underlying genetic factors in a number of the syndromes that include RS have been delineated,^{17–19} the genetic basis for isolated RS remains unclear.

The developmental basis of RS is still contentious and it is conceivable that more than one pathogenic mechanism may be responsible for the full range of RS manifestations. One proposed theory for the origin of RS argues that mandibular hypoplasia, resulting from a developmental anomaly in either growth or placement of the mandible, is the primary defect.²⁰ The cleft palate and apnoea could thus be a consequence of reduced oropharyngeal volume. This is supported by the elimination of both cleft palate and/or glossoptosis in the definition for PRS by some authors.^{10,21–23} Further support for this hypothesis comes from an experimental paradigm of RS in which mandibular hypoplasia and relative macroglossia precede palatal closure.²⁴ An alternative developmental sequence for RS centres on the hindbrain region regulating oro-oesophageal motor function.^{25–28} According to this theory, oral motility required for mandibular growth is disrupted in the early fetal period, and mandibular hypoplasia is a secondary consequence of these neuronal or neuromuscular deficits.²⁹ This model is supported by experimental findings of cleft palate and mandibular hypoplasia in an induced model of oropharyngeal muscular degeneration.³⁰

While non-genetic aetiologies for RS have been proposed,^{31,32} there are a number of reported cases describing chromosomal abnormalities associated with the non-syndromic or isolated RS^{33–37} implicating an underlying genetic component (table 1). Vintiner *et al* reported a balanced translocation t(5;17)(q15;q23) in all affected individuals of a single family during screening for Stickler syndrome.³³

Key points

- Robin sequence (RS) is a developmental anomaly characterised by micrognathia, cleft palate, and glossoptosis. To date, no known genes have been demonstrated to cause isolated RS.
- We report a family with isolated RS in which this condition co-segregates with a balanced reciprocal t(2;17)(q24.1;q24.3) translocation over three generations.
- The breakpoints were localised using fluorescence *in situ* hybridisation walking to a region between probes RP11-157M22 and RP11-611G1 on chromosome 2, and RP11-147L13 and RP11-261A13 on chromosome 17.
- We propose that this reciprocal translocation has disrupted a putative gene or a regulatory element at one or both translocation breakpoints.
- This family represents a unique resource for the molecular genetic study of craniofacial development and has the potential to enable the identification of the developmental progression leading to RS.

However, together with RS, the clinical phenotype of the family included arthropathy of varying severity among the affected individuals, a feature not typical of classical RS. Additional reports have also indicated that there may be an RS locus at 17q23.3–25^{34,36} although no gene has been isolated. Moreover, Houdayer *et al* reported a case of non-syndromic RS that co-segregated with an unbalanced reciprocal translocation involving an interstitial deletion of chromosome 2 (2q32.3–q33.2), and suggested this locus as a candidate region for non-syndromic RS.³⁵ This hypothesis is further strengthened by a previous report indicating involvement of the 2q32 locus in the pathogenesis of isolated cleft palate.³⁸

In addition to reports of cytogenetic abnormalities, a recent study provides support for the existence of multiple genetic loci for RS with the identification of sequence variations in the *COL2A1*, *COL11A1*, and *COL11A2* genes in a number of unrelated patients with non-syndromic RS.³⁹ The role for these variations in the aetiology of RS has yet to be clarified, but their discovery along with evidence of distinct cytogenetic anomalies highlights the aetiological heterogeneity associated with RS. Thus, several promising loci associated with isolated RS await further characterisation.

Abbreviations: BAC, bacterial artificial chromosome; FISH, fluorescent *in situ* hybridisation; RS, Robin sequence

We identified a family in which a balanced reciprocal translocation (2;17)(q24.1;q24.3) co-segregates with the classical isolated form of RS across three generations. Characterisation of the cytogenetic anomaly in this family has narrowed the breakpoint to a defined region delineated by two bacterial artificial chromosome (BAC) probes on each chromosome. We anticipate that the identification of a disrupted gene(s) due to the translocation in this family will enable further genetic studies that may elucidate the underlying aetiology of RS, leading to a better understanding of this aspect of craniofacial development.

MATERIALS AND METHODS

Family study

The family came to our notice when the proband (III:1) was born at term with the classical features of RS. The parents were not consanguineous. Family history revealed that the father (II:1) and other members of his family had had RS as children (figs 1 and 2). Clinical assessment was undertaken by personal examination, perusal of childhood photographs provided by the family, and review of medical records. These were performed with the informed consent of the adult family members, and the study was approved by the RCH Ethics in Human Research Committee. The clinical presentation in all affected individuals is summarised in table 2. Pregnancy histories were unremarkable. At birth, the proband presented with micrognathia, cleft palate, and moderate airway obstruction requiring prone positioning. A

nasopharyngeal tube was required for airway support for 7 days and nasogastric feeding was continued until 9 months of age. Birth weights and neonatal indices were otherwise essentially normal. The external ears were normal in shape and placement and no other malformations were identified beyond that due to the micrognathia. No other skeletal abnormalities were noted in the family and a skeletal survey of the proband was unremarkable, indicating normal ribs and scapula. Developmental progress and school achievement has been apparently normal. Ophthalmological examination in members I:2, II:1, II:8, II:9 with specific reference to the possibility of Stickler syndrome gave uniformly normal findings.

Cytogenetic and fluorescent in situ hybridisation studies

Peripheral blood samples for chromosome analysis were processed according to standard techniques, and preparations were analyzed using G-banding. Dual colour fluorescent in situ hybridisation (FISH) was performed on metaphase chromosome spreads of the patients with the (2;17) translocation using BAC clones according to the method of Pinkel *et al* with some modifications.⁴⁰ The BAC clones were obtained from BACPAC Resources at the Murdoch Institute, Melbourne, Australia. Images were captured using a Zeiss Axioscope fluorescence microscope equipped with a cooled CCD camera (Photometrics, Huntingdon Beach, CA, USA)

Table 1 Clinical findings in reported cases with chromosomal rearrangement involving chromosome 2 and/or 17

Classical RS phenotype	Other findings	Cytogenetics	FISH data	References
+	None	t(2;17)(q23;q23.3)	t(2;17)(q24.1;q24.3)	Present case
+	Limb, ear abnormalities	t(2;21)(q33.2;q21.2)	t(2;21)(q32.3-q33.2)	Houdayer <i>et al</i> ⁵
+	Other skeletal abnormalities	t(13;17)(q22.1;q23.3)	Not described	Stalker <i>et al</i> ⁶
+	None	t(3;17)(q25-qter)	Not described	Luke <i>et al</i> ⁴
+	Ear abnormalities	t(5;17)(q15;q23)	Not described	Vintiner <i>et al</i> ³

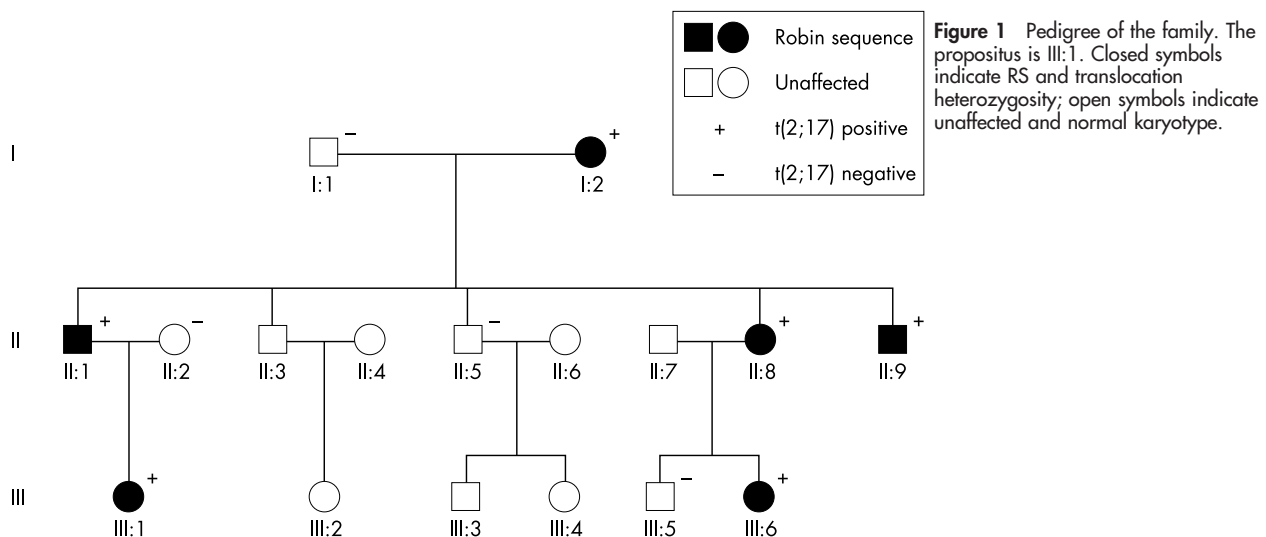

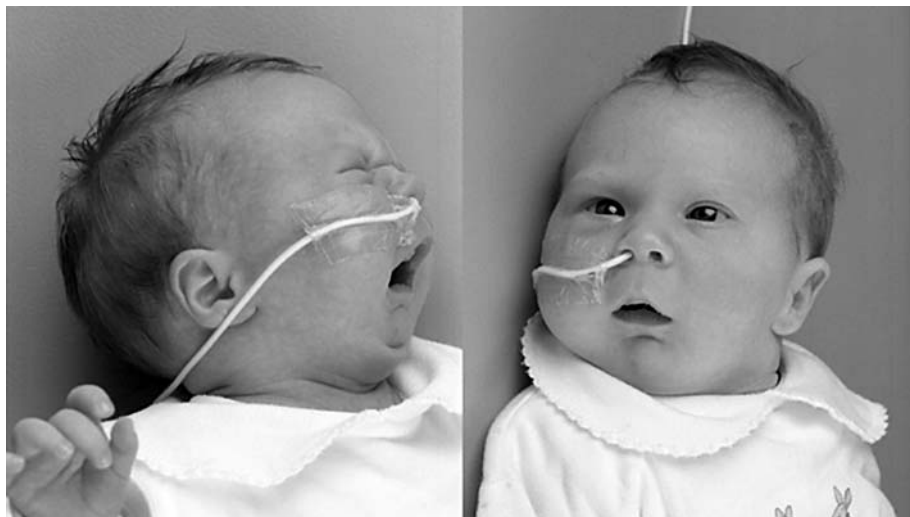


Figure 2 Lateral and frontal view of proband illustrating pronounced micrognathia.

and analyzed by IPlab Software (Scanalytics, Fairfax, VA, USA).

RESULTS

Conventional cytogenetic examination on the G-banded metaphase chromosomes of the proband showed an apparently balanced translocation involving the long arms of chromosomes 2 and 17, 46XX,t(2;17)(q23;q23.3). The father carried the same translocation, while the maternal karyotype was normal. Subsequent investigation revealed the translocation in all the other family members with isolated RS (I:2, II:1, II:8, II:9, III:6), but in none of the unaffected family members who was tested. This translocation appeared identical in each case.

Further detailed mapping of the breakpoints was performed by FISH using BAC clones from the RP11 library that have been mapped to the chromosomal regions 2q21.3–q25.1 and 17q21.2–q25.3. BAC clones were selected by searching the NCBI Human Genome Database (www.ncbi.nlm.nih.gov). The BAC clone RP11-157M22 produced a signal on both normal chromosome 2 and the derivative chromosome 2 (der(2)), while RP11-611G1 hybridised to both the normal 2 and der(17) chromosomes (fig. 3A,B). The BAC clone RP11-147L13 revealed hybridisation signals on the normal 17 and

der(17) chromosomes, while RP11-261A13 shows a signal on both normal 17 and der(2) chromosomes (fig 3C,D). The FISH analysis did not indicate any deletion, and confirmed the nature of the reciprocal translocation.

DISCUSSION

We have identified a balanced (2;17) translocation segregating in the reported family for three generations. The balanced reciprocal chromosome translocation involving chromosomes 2 and 17 was present in all six family members with isolated RS, and in none of the unaffected members who were tested. This complete co-segregation of karyotype with respect to phenotype in the six individuals strongly points to a causal connection, and we thus draw the conclusion that an RS locus exists at one or other of the translocation breakpoints. The FISH analysis indicated that the breakpoint on chromosome 2 mapped to the interval between BAC clones RP11-157M22 and RP11-611G1 on the band q24.1, while the breakpoint on chromosome 17 was located between RP11-147L13 and RP11-261A13 on band q24.3. This is the first detailed description of a balanced chromosomal translocation involving chromosomes 2 and 17 in a family with isolated RS.

Previous reports indicate that a distinct, clinically recognisable syndrome involving deletions of chromosome 2q23–24.3 region may exist.⁴¹ Furthermore, there are a number of cases reported with similar craniofacial abnormalities associated with microdeletions on chromosome 17 (q21–q24).⁴² Micrognathia and palatal defects commonly feature in patients harbouring deletions on both chromosomes, although the phenotypes described are much broader than that in the family described here. These findings further support the contention that one or more genes involved in craniofacial development are harboured at these loci, although micrognathia may also be viewed as a common, non-specific feature of such deletions.⁴³

There is only a single reported case of non-syndromic RS implicating 2q32³⁵ but no evidence of a locus at 2q23–24. In contrast, four examples of RS including the current study have been described with translocations involving the 17q23.3–17q25 region^{33 34 36} (table 1). So far, there have been no available data defining the exact breakpoint region on chromosome 17. Thus, while the involvement of a locus on chromosome 2q24 cannot be excluded, the case does seem stronger in favour of the location of the gene responsible for isolated RS to be at chromosome 17q24.1.

Table 2 Summary of clinical features of the affected members of the present family with the chromosomal translocation

Clinical appearance	I:2	II:1	II:8	II:9	III:1*	III:6
Micrognathia at birth	+	+	+	+	+	+
Cleft palate†						
Complete						+
Incomplete	+					
Soft	+	+	+		+	
Glossoptosis	ND	+	–	+	–	–
Airway obstruction	–	–	–	+	–	–
Marked neonatal feeding and swallowing problems	–	–	–	+	–	–
Nasopharyngeal incompetence	ND	+	+	+	–	+

*Proband.

†Classification according to the definitions provided by Abadie *et al.*²⁹ Complete CP: all secondary palate absent; incomplete CP: part of the secondary palate absent; soft CP: whole bony palate present. ND, not described.

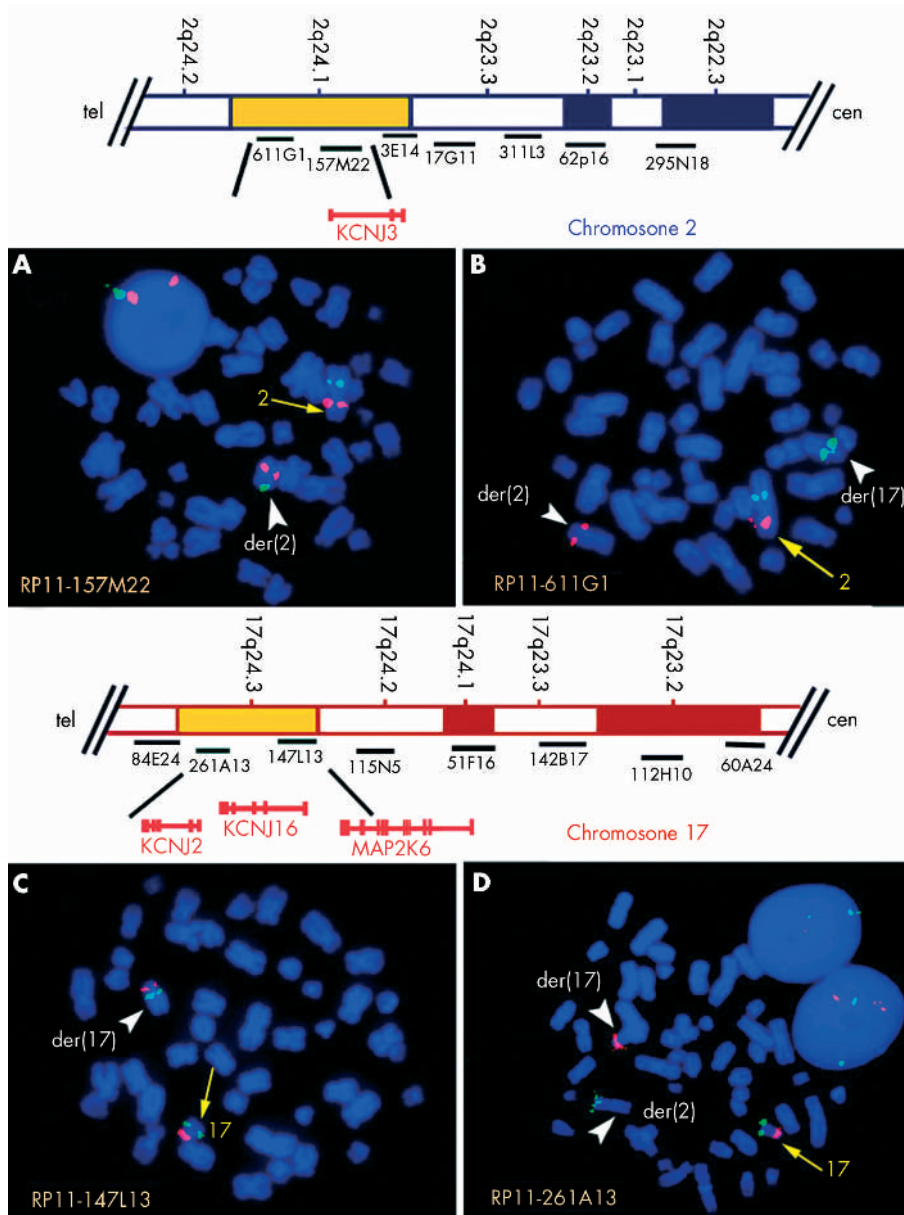


Figure 3 FISH analysis of BACs spanning the breakpoint from the father (II:1) of the proband. Ideogram illustrations of chromosome 2 and 17, respectively indicating the position of breakpoints and BAC probes. The known genes in the vicinity of the breakpoints are also included. Chromosome 2: Hybridisation of the BAC probes corresponding to RP11-157M22 and RP11-611G1 onto metaphase chromosomes from the affected individual (II:1). The test probes, RP11-157M22 and RP11-611G1, labelled with digoxigenin-11-dUTP were detected with fluorescein-conjugated antibodies and are visualised as green signals. The reference probe for chromosome 2p14, RP11-340F16, labelled with biotin-16-dUTP, is detected with Texas Red and visualised as a red signal. (A) RP11-157M22 remains on the derivative chromosome 2 while (B) RP11-611G1 hybridises to the translocated derivative chromosome 17. Chromosome 17: Hybridisation of BACs RP11-147L13 and RP11-261A13 to metaphase chromosomes from the affected individual. The reference probe for chromosome 17p11.2 is RP11-273K13, which appears as a red signal; RP11-147L13 and RP11-261A13 are both visualised as green signals. (C) RP11-147L13 remains on the derivative chromosome 17 while (D) RP11-261A13 is translocated to derivative chromosome 2. Yellow arrows show normal chromosome 2 or 17; arrowheads indicate derivative chromosomes.

As the first step towards positional cloning of the putative gene affected by this t(2;17) translocation, we have defined the 2q24.1 translocation breakpoints within a region less than 1 Mb in length flanked by BACs RP11-157M22 and RP11-611G1, and the 17q24.3 breakpoint within a 2 Mb region between BACs RP11-147L13 and RP11-261A13 (fig 3). These results provide a scaffold for the cloning of the translocation breakpoints and identification of a disrupted gene.

Mutations in the *SOX9* gene cause skeletal abnormalities that often include cleft palate.⁴⁴ The location of the breakpoint in this family close to the *SOX9* region at 17q24–25 raised the possibility that disruption of the *SOX9* gene or its regulatory elements was responsible for the occurrence of RS. FISH analysis using BACs centromeric to *SOX9* revealed a signal on the normal chromosome 17 as well as the derivative chromosome 2, thereby demonstrating that the *SOX9* region was not affected by the breakpoint. In addition, the findings of Melkonian *et al*³⁹ regarding collagen gene mutations in RS

patients are not relevant in this case, as none of these genes reside on chromosome 2 or 17.

This left a number of potential candidate genes located in the breakpoint regions (fig 3). It is interesting that the known genes in the region are highly expressed in neuronal and skeletal muscle tissues, in particular *MAP2K6*, *KCNJ16*, and *KCNJ2* on chromosome 17 and *KCNJ3*, located on chromosome 2. Further molecular characterisation of these breakpoints is currently underway in our laboratory to identify the putative gene for isolated RS in this family. We anticipate that its discovery will contribute substantially to the understanding of the pathogenesis of RS, and to a wider knowledge of oro- and cranio-facial development.

ACKNOWLEDGEMENTS

N Jamshidi is an NH and MRC Australia scholar. We are most grateful to the family for their participation in this study. We thank Dr L Sheffield for the clinical follow-up and Dr D Newgreen for helpful comments on the manuscript. We also wish to thank Dr

H Slater for the cytogenetic support, as well as Dr J Craig and Ms E Earle for the technical advice on the FISH technique.

Authors' affiliations

N Jamshidi, P G Farlie, N Kilpatrick, Craniofacial Sciences Consortium, Murdoch Children's Research Institute, Royal Children's Hospital, Parkville, Victoria, Australia

I Macciocca, R J McKinlay Gardner, Genetic Health Services Victoria, Royal Children's Hospital, Parkville, Victoria, Australia

P Thomas, Pituitary Research Unit, Murdoch Children's Research Institute, Royal Children's Hospital, Parkville, Victoria, Australia

P A Dargaville, Department of Neonatology, Royal Children's Hospital, Parkville, Victoria, Australia

Correspondence to: Dr P Farlie, Craniofacial Sciences Consortium, Murdoch Children's Research Institute, Royal Children's Hospital, Parkville, Victoria, Australia; farliep@cryptic.rch.unimelb.edu.au

Received 2 May 2003

Accepted 31 July 2003

REFERENCES

- 1 **Robin P**. Glossoptosis due to atresia and hypotrophy of the mandible. *Am J Dis Child* 1934;**48**:541-7.
- 2 **Mallory SB**, Paradise JL. Glossoptosis revisited: on the development and resolution of airway obstruction in Pierre Robin Syndrome. *Pediatrics* 1979;**64**:946-8.
- 3 **Cohen MM Jr**. Robin sequences and complexes: causal heterogeneity and pathogenetic/phenotypic variability. *Am J Med Genet* 1999;**84**:311-15.
- 4 **Marques IL**, Barbieri MA, Bettiol H. Etiopathogenesis of isolated robin sequence. *Cleft Palate Craniofac J* 1998;**35**:517-25.
- 5 **Sidhu SS**, Deshmukh RN. Pierre Robin syndrome: autosomal dominant inheritance with pleiotropic effect. *Indian J Pediatr* 1989;**56**:413-17.
- 6 **Cohen MM Jr**. The Robin anomalad—its nonspecificity and associated syndromes. *J Oral Surg* 1976;**34**:587-93.
- 7 **Cohen MM Jr**. Interface between Robin sequence and ordinary cleft palate. *Am J Med Genet* 2001;**101**:288.
- 8 **Shprintzen RJ**. Pierre Robin, micrognathia, and airway obstruction: the dependency of treatment on accurate diagnosis. *Int Anesthesiol Clin* 1988;**26**:64-71.
- 9 **Marques IL**, DeSousa TV. Clinical experience with infants with Robin Sequence: A prospective study. *Cleft Palate Craniofac J* 2001;**38**:171-8.
- 10 **Pasyayan HM**, Lewis MB. Clinical experience with the Robin sequence. *Cleft Palate J* 1984;**21**:270-6.
- 11 **Tomaski SM**, Zalzal GH, Saal HM. Airway obstruction in the Pierre Robin sequence. *Laryngoscope* 1995;**105**:111-14.
- 12 **Shprintzen RJ**. The implications of the diagnosis of Robin sequence. *Cleft Palate Craniofac J* 1992;**29**:205-9.
- 13 **Witt PD**, Myckatyn T, Marsh JL, Grames LM, Downton SB. Need for velopharyngeal management following palatoplasty: an outcome analysis of syndromic and nonsyndromic patients with Robin sequence. *Plast Reconstr Surg* 1997;**99**:1522-9.
- 14 **Sheffield LJ**, Reiss JA, Strohm K, Gilding M. A genetic follow-up study of 64 patients with the Pierre Robin complex. *Am J Med Genet* 1987;**28**:25-36.
- 15 **van den Elzen AP**, Semmekrot BA, Bongers EM, Huygen PL, Marres HA. Diagnosis and treatment of the Pierre Robin sequence: results of a retrospective clinical study and review of the literature. *Eur J Pediatr* 2001;**160**:47-53.
- 16 **Glander K 2nd**, Cisneros GJ. Comparison of the craniofacial characteristics of two syndromes associated with the Pierre Robin sequence. *Cleft Palate Craniofac J* 1992;**29**:210-19.
- 17 **Dixon MJ**, Read AP, Donnai D, Colley A, Dixon J, Williamson R. The gene for Treacher Collins syndrome maps to the long arm of chromosome 5. *Am J Hum Genet* 1991;**49**:17-22.
- 18 **Snead MP**, Yates JR. Clinical and molecular genetics of Stickler syndrome. *J Med Genet* 1999;**36**:353-9.
- 19 **Jerome LA**, Papaioannou VE. DiGeorge syndrome phenotype in mice mutant for the T-box gene, *Tbx1*. *Nat Genet* 2001;**27**:286-91.
- 20 **Hanson JW**, Smith DW. U-shaped palatal defect in the Robin anomalad: developmental and clinical relevance. *J Pediatr* 1975;**87**:30-3.
- 21 **Vegter F**, Hage JJ, Mulder JW. Pierre Robin syndrome: mandibular growth during the first year of life. *Ann Plast Surg* 1999;**42**:154-7.
- 22 **Elliott MA**, Studen-Pavlovich DA, Ranalli DN. Prevalence of selected pediatric conditions in children with Pierre Robin sequence. *Pediatr Dent* 1995;**17**:106-11.
- 23 **Lewis MB**, Pashayan HM. Management of infants with Robin anomaly. *Clin Pediatr*, 1980;**19**:525-8.
- 24 **Ricks JE**, Ryder VM, Bridgewater LC, Schaalje B, Seegmiller RE. Altered mandibular development precedes the time of palate closure in mice homozygous for disproportionate micromelia: an oral clefting model supporting the Pierre-Robin sequence. *Teratology* 2002;**65**:116-20.
- 25 **Baudon JJ**, Renault F, Goutet JM, Flores-Guevara R, Soupre V, Gold F, Vazquez MP. Motor dysfunction of the upper digestive tract in Pierre Robin sequence as assessed by sucking-swallowing electromyography and esophageal manometry. *J Pediatr* 2002;**140**:719-23.
- 26 **Baujart G**, Faure C, Zauouche A, Viarme F, Couly G, Abadie V. Oroesophageal motor disorders in Pierre Robin syndrome. *J Pediatr Gastroenterol Nutr* 2001;**32**:297-302.
- 27 **Renault F**, Flores-Guevara R, Soupre V, Vazquez MP, Baudon JJ. Neurophysiological brainstem investigations in isolated Pierre Robin sequence. *Early Hum Dev* 2000;**58**:141-52.
- 28 **Couly G**. A new concept of Pierre Robin syndrome and disease: dysneurulation of the rhombencephalon. *Rev Stomatol Chir Maxillofac* 1983;**84**:225-32.
- 29 **Abadie V**, Morisseau-Durand MP, Beyler C, Manach Y, Couly G. Brainstem dysfunction: a possible neuroembryological pathogenesis of isolated Pierre Robin sequence. *Eur J Pediatr* 2002;**161**:275-80.
- 30 **Grieshammer U**, Lewandoski M, Prevette D, Oppenheim RW, Martin GR. Muscle-specific cell ablation conditional upon Cre-mediated DNA recombination in transgenic mice leads to massive spinal and cranial motoneuron loss. *Dev Biol* 1998;**197**:234-47.
- 31 **Aggarwal S**, Kumar A. Fetal hydrocolpos leading to Pierre Robin sequence: an unreported effect of oligohydramnios sequence. *J Perinatol* 2003;**23**:76-8.
- 32 **Taylor MR**. The Pierre Robin Sequence: a concise review for the practicing pediatrician. *Pediatr Rev* 2001;**22**:125-30.
- 33 **Vintiner GM**, Temple IK, Middleton-Price HR, Baraitser M, Malcom S. Genetic and clinical heterogeneity of Stickler syndrome. *Am J Med Genet* 1991;**41**:44-8.
- 34 **Luke S**, Bennett HS, Pitter JH, Verma RS. A new case of monosomy for 17q25-qter due to a maternal translocation t(3;17)(p12;q24). *Ann Genet* 1992;**35**:48-50.
- 35 **Houdayer C**, Portnoi MF, Vialard F, Soupre V, Crumiere C, Taillemite JL, Couderc R, Vazquez MP, Bahuau M. Pierre Robin sequence and interstitial deletion 2q32.3-q33.2. *Am J Med Genet* 2001;**102**:219-26.
- 36 **Stalker HJ**, Gray BA, Zori RT. Dominant transmission of a previously unidentified 13/17 translocation in a five-generation family with Robin cleft and other skeletal defects. *Am J Med Genet* 2001;**103**:339-41.
- 37 **Frydman R**, Tachdjian G. De novo interstitial direct duplication 1(q23.1q31.1) in a fetus with Pierre Robin sequence and camptodactyly. *Am J Med Genet* 2002;**108**:153-9.
- 38 **Brewer CM**, Leek JP, Green AJ, Holloway S, Bonthron DT, Markham AF, FitzPatrick DR. A locus for isolated cleft palate, located on human chromosome 2q32. *Am J Hum Genet* 1999;**65**:387-96.
- 39 **Melkonieni M**, Koillinen H, Mannikko M, Warman ML, Pihlajamaa T, Kaariainen H, Rautio J, Hukki J, Stoffko JA, Cisneros GJ, Krakow D, Cohn DH, Kere J, Ala-Kokko L. Collagen XI sequence variations in nonsyndromic cleft palate, Robin sequence and micrognathia. *Eur J Hum Genet* 2003;**11**:265-70.
- 40 **Pinkel D**, Straume T, Gray JW. Cytogenetic analysis using quantitative, high-sensitivity, fluorescence hybridization. *Proc Natl Acad Sci USA* 1986;**83**:2934-8.
- 41 **Mickelson EC**, Robinson WP, Hrynchak MA, Lewis ME. Novel case of del(17)(q23.1q23.3) further highlights a recognizable phenotype involving deletions of chromosome (17)(q21q24). *Am J Med Genet* 1997;**71**:275-9.
- 42 **Maas SM**, Hoovers JM, van Seggelen ME, Menzel DM, Hennekam RC. Interstitial deletion of the long arm of chromosome 2: a clinically recognizable microdeletion syndrome? *Clin Dysmorphol* 2000;**9**:47-53.
- 43 **McMilin KD**, Reiss JA, Brown MG, Black MH, Buckmaster D, A. Durum CT, Gunter KA, Lawce HJ, Berry TL, Lamb OA, Olson CL, Weeks FF, Yoshitomi MJ, Jacky PB, Olson SB, Magenis RE. Clinical outcomes of four patients with microdeletion in the long arm of chromosome 2. *Am J Med Genet* 1998;**78**:36-43.
- 44 **Bi W**, Huang W, Whitworth DJ, Deng JM, Zhang Z, Behringer RR, de Crombrugge B. Haploinsufficiency of *Sox9* results in defective cartilage primordia and premature skeletal mineralization. *Proc Natl Acad Sci USA* 2001;**98**:6698-703.