

SHORT REPORT

Familial isolated hyperCKaemia associated with a new mutation in the caveolin-3 (CAV-3) gene

L Merlini, I Carbone, C Capanni, P Sabatelli, S Tortorelli, F Sotgia, M P Lisanti, C Bruno, C Minetti

J Neurol Neurosurg Psychiatry 2002;**73**:65–67

An 18 year old man and his mother both presented with persistent, isolated raised serum creatine kinase (hyperCKaemia) without muscle symptoms. Analysis of caveolin-3 protein expression in muscle biopsy of the propositus showed a reduction in the protein. Genetic analysis revealed a new heterozygous mutation in the caveolin-3 (CAV-3) gene: a C→T transition at nucleotide position 83 in exon 1 leading to a substitution of a proline for a leucine at amino acid position 28 (P28L). This is the first pathogenic mutation in the CAV-3 gene associated with isolated familial hyperCKaemia. It expands the genetic heterogeneity in patients with caveolin-3 deficiency and confirms that caveolin-3 deficiency should be considered in the differential diagnosis of isolated hyperCKaemia.

Raised serum creatine kinase (hyperCKaemia) is a hallmark of hereditary neuromuscular disorders.¹ However, several acquired conditions (for example, infections, alcoholism, drugs, intramuscular injections) may also cause a rise in creatine kinase, and as the enzyme is now often included in routine blood tests the number of apparently healthy individuals with persistent hyperCKaemia has increased.² The criteria for the diagnosis of isolated hyperCKaemia have been revised in recent decades, with emphasis on the importance of a thorough muscle biopsy study.^{2–4}

Caveolin-3, a muscle specific caveolin related protein, is the principal structural protein of caveolar membrane domains in skeletal muscle and in the heart.⁵ Mutations within the coding sequence of the human caveolin-3 gene have been so far associated with different muscle disorders: an autosomal dominant form of limb girdle muscular dystrophy (LGMD-1C),⁶ an idiopathic form of hyperCKaemia,⁷ and recently, a rare skeletal muscle disorder characterised by mechanical hyperirritability (rippling muscle disease, RMD).^{8,9}

We previously described a sporadic heterozygous mutation in the CAV-3 gene in two unrelated asymptomatic children with isolated persistent hyperCKaemia.⁷ Here, we present two members of another family with persistent hyperCKaemia without any signs or symptoms of myopathy, in whom muscle biopsy revealed partial caveolin-3 deficiency and genetic analysis identified a new mutation in the caveolin-3 gene.

METHODS

Case 1

The propositus, an 18 year old man, was referred for further evaluation of a raised serum creatine kinase discovered during a routine blood test. Motor milestones were normal. He never complained of muscle weakness, cramps, or premature fatigue, even after exercise. Neurological examination showed no muscle intolerance, signs of mechanical hyperirritability, or central nervous system impairment. There was no calf hypertrophy or contractures. Resting serum creatine kinase was

2600 IU/l (normal value < 175 IU/l), while other routine laboratory investigations were normal. Electromyography (EMG) and nerve conduction studies were normal. An electrocardiogram was normal. Computed tomography of the shoulder, abdominal, hip, and leg muscles was normal. The patient was not taken any drugs or receiving intramuscular injections.

Case 2

A 49 year old woman, the mother of case 1, denied any myalgia or cramps. General physical examination was normal. Neurological examination and electrophysiological studies were unremarkable. Resting serum CK was 550 IU/l. Extensive routine laboratory investigations were normal.

Investigations

In both cases, serum CK levels were raised on multiple occasions; the father and the 24 year old sister had normal values.

A muscle biopsy was obtained from the quadriceps muscle of the propositus. Routine histological and histochemical techniques, including staining for myophosphorylase, phosphofructokinase, and myoadenylate deaminase, were performed by standard methods. For immunohistochemistry and western blot analysis, muscle samples were processed as previously described.⁶ Genomic DNA was extracted from peripheral blood leucocytes using the standard phenol/chloroform method. The full length coding region and the intron-exon boundaries of the CAV-3 gene were screened for mutations by direct sequencing of polymerase chain reaction products using specific primers, as described.⁶

RESULTS

Muscle biopsy showed a mild increase in variability of fibre size with some hypertrophic fibres, few internal nuclei, and one necrotic fibre. On immunofluorescence microscopy, the intensity of staining for caveolin-3 at the cell surface was reduced (fig 1). On western blot analysis the caveolin-3 protein expression levels were reduced by 65% (data not shown). Other membrane proteins involved in different forms of muscular dystrophy (dystrophin, α -, β -, γ -, and δ -sarcoglycan, α 2-laminin) had normal immunostaining patterns.

Sequence analysis of the CAV-3 gene in the propositus identified a novel heterozygous C→T transition at nucleotide position 83 in exon 1, leading to a substitution of a proline for a leucine at amino acid position 28 (P28L) (fig 1). The mutation was confirmed in the mother by direct sequencing analysis. This mutation was not observed in 50 other patients with different myopathies or in 100 normal controls.

DISCUSSION

We describe a novel heterozygous mutation—a C→T transition at nucleotide position 83 in exon 1 of the CAV-3 gene in two adult family members, a young man and his mother—

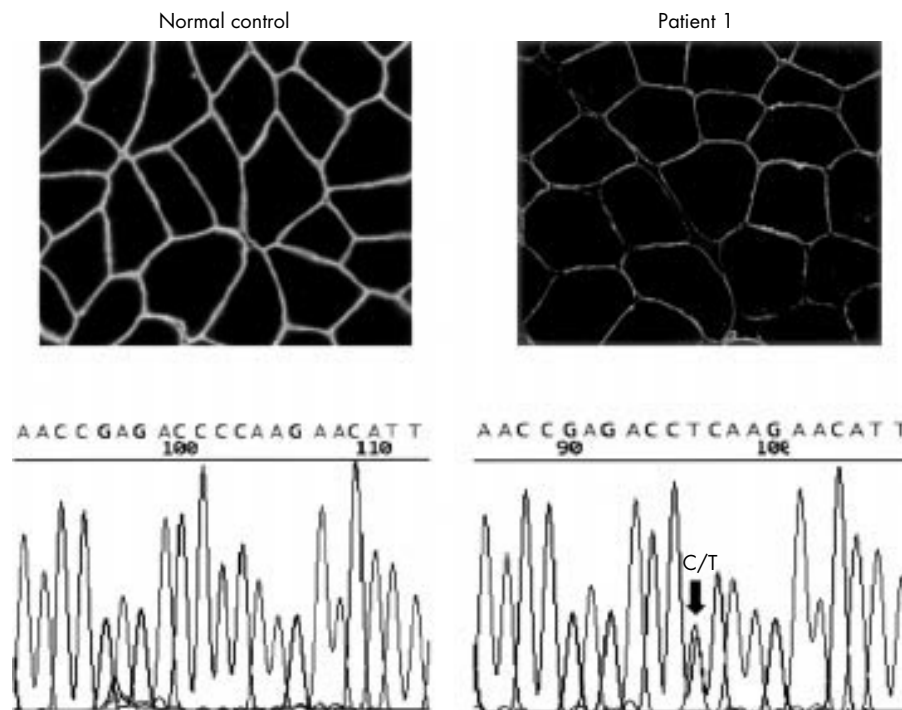


Figure 1 Upper panels: Immunolocalisation of caveolin-3 in muscle biopsy. Left: fluorescent immunohistochemical labelling of caveolin-3 in normal muscle, revealing strong positive staining at the sarcolemmal membrane. Right: immunohistochemical labelling of caveolin-3 in patient 1 showing reduced staining at the sarcolemma. Lower panels: Sequence analysis of the CAV-3 gene. Left: sequence DNA of caveolin-3 in a normal control (exon 1). Right: heterozygous C→T mutation at nucleotide position 83 (arrow) in patient 1, leading to a proline to leucine substitution (P28L).

associated with isolated persistent hyperCKaemia (three- to 15-fold above normal values). Neither of these individuals had muscle symptoms, and we excluded the other known causes of hyperCKaemia.^{1,2,3} To our knowledge, this is the first report of a mutation in the CAV-3 gene associated with familial hyperCKaemia, confirming that caveolin-3 deficiency should be considered in the differential diagnosis of isolated hyperCKaemia. We believe this mutation is likely to be pathogenic, for the following reasons: first, leucine at amino acid position 28 is a highly conserved residue across evolution, suggesting a central role for this amino acid in the normal structure and function of the enzyme; second, there was co-segregation with hyperCKaemia in a dominant mode of inheritance over two generations; third, there was co-segregation with the reduction in the protein expression; and fourth, the anomaly was not found in any of 100 controls.

Different mutations in the CAV-3 gene have been associated with various clinical phenotypes.^{6,7,8,9,10,11,12} We previously identified a missense mutation and a microdeletion in eight patients from two different families with a specific form of limb girdle muscular dystrophy (LGMD-1C).⁶ We then

reported a novel sporadic mutation in two unrelated children associated only with persistent hyperCKaemia without any symptoms of myopathy.⁷ Recently, four mutations in the CAV-3 gene have been identified in five families with hereditary rippling muscle disorders (RMD), an autosomal dominant human disease characterised by mechanically triggered contraction of skeletal muscle.^{8,9}

Interestingly, same mutations have been associated with different phenotypes, implying that other genes or factors are involved in the clinical expression (table 1). In addition, a de novo CAV-3 mutation (R26Q) localised in the N-terminal domain was found in three different patients,^{7,9} suggesting that this region of the first exon of the CAV-3 gene may be a genetic hot spot for the development of a common sporadic mutation.

We note that the reduction of caveolin-3 protein expression observed on western blot in patients with hyperCKaemia, either sporadic or familial, is less severe than that detected in LGMD-1C. A possible explanation may be that mutations in LGMD-1C involve the scaffolding domain or the membrane

Table 1 Summary of mutations in the CAV-3 gene

Mutation	Location	Base pair variation	Nucleotide position	Phenotypes	Reference
R26Q	EXON 1	G→A	77	IHCK/RMD	7, 9
P28L	EXON 1	C→T	83	FHCK	Present report
A45T	EXON 2	G→A	133	LGMD 1C/RMD	8, 11
A45V	EXON 2	C→T	134	RMD	8
G55S	EXON 2	G→A	163	LGMD 1C	10
‡TFT (63–65)	EXON 2	9 bp deletion	186–194	LGMD 1C	6
C71W	EXON 2	C→G	213	LGMD 1C	10
P104L	EXON 2	C→T	311	LGMD 1C/RMD	6, 8
R125H	EXON 2	G→A	374	LGMD 1C	12

bp, base pair; FHCK, familial hyperCKaemia; IHCK, isolated hyperCKaemia; LGMD, limb girdle muscular dystrophy; RMD, rippling muscle disease.

spanning domain of caveolin-3, which are essential for caveolin homo-oligomerisation and for the formation of caveolae at the cell membrane. In contrast, a mutation involving other parts of the caveolin-3 protein, as observed in our patients with hyperCKaemia, may have less severe consequences for caveolin-3 protein expression at the plasmalemma. However, these mutations may still partially destabilise the muscle cell plasma membrane, resulting in asymptomatic release of creatine kinase.

Although the absolute number of patients examined is still too small to define the genotype-phenotype correlation, our familial cases and the two sporadic patients previously reported by us indicate that caveolin-3 deficiency may present with persistent isolated hyperCKaemia that is clinically silent.

Irrespective the clinical course of the disease, we recommend performing immunohistochemical evaluation of caveolin-3 protein expression and molecular genetic analysis of the CAV-3 gene in sporadic or familial cases of isolated persistent hyperCKaemia.

ACKNOWLEDGEMENTS

This work was supported by grants from EC project Myo-Cluster (to LM, contract No QLGI-CT-1999-00870), Telethon-Italia (to CM, project GP027/y01), and the Italian Ministry of Health (Istituto Ortopedico Rizzoli, and Istituto Giannina Gaslini, Ricerca Finalizzata).

.....

Authors' affiliations

L Merlini, Neuromuscular Disease Unit, Istituto Ortopedico Rizzoli, Bologna, Italy

C Capanni, Laboratory of Cellular Biology and Electron Microscopy, Istituto Ortopedico Rizzoli,

P Sabatelli, Institute of Citomorphology, CNR, Bologna, Italy

M P Lisanti, Department of Molecular Pharmacology, The Albert Einstein College of Medicine, Bronx, New York, USA

I Carbone, S Tortorelli, F Sotgia, C Bruno, C Minetti, Neuromuscular Disease Unit, Department of Paediatrics, University of Genova, Gaslini Institute, Genova, Italy

Correspondence to: Dr C Minetti, Servizio Malattie Neuro-Muscolari, Dipartimento di Pediatria dell'Università di Genova, Istituto G Gaslini, Largo G Gaslini 5, I-16147 Genova, Italy; minettic@unige.it

Received 17 January 2002

Accepted 4 March 2002

REFERENCES

- 1 Rowland LP, Willner J, Cerri C, *et al.* Approaches to the membrane theory of Duchenne muscular dystrophy. In: Angelini C, Danielli GA, Fontanari D, eds. *Muscular dystrophy research: advances and new trends*. Amsterdam: Excerpta Medica, 1980:3-13.
- 2 Afifi AK. Idiopathic hyperCKemia revisited. *J Child Neurol* 1998;**13**:251-2.
- 3 Reijneveld JC, Notermans NC, Linszen WHJP, *et al.* HyperCKemia revisited. *Neuromusc Dis* 2001;**11**:163-4.
- 4 Bruno C, Bertini E, Santorelli FM, *et al.* HyperCKemia as the only sign of McArdle's disease in a child. *J Child Neurol* 2000;**15**:137-8.
- 5 Galbiati F, Razani B, Lisanti MP. Caveolae and caveolin-3 in muscular dystrophy. *Trends Mol Med* 2001;**7**:435-41.
- 6 Minetti C, Sotgia F, Bruno C, *et al.* Mutations in the caveolin-3 gene cause autosomal dominant limb-girdle muscular dystrophy. *Nat Genet* 1998;**18**:365-8.
- 7 Carbone I, Bruno C, Sotgia F, *et al.* Mutation in the CAV3 gene causes partial caveolin-3 deficiency and hyperCKemia. *Neurology* 2000;**54**:1373-6.
- 8 Betz RC, Shoser BGH, Kasper D, *et al.* Mutations in CAV3 cause mechanical hyperirritability of skeletal muscle in rippling muscle disease. *Nat Genet* 2001;**28**:218-19.
- 9 Vorgerd M, Ricker K, Ziemssen F, *et al.* A sporadic case of rippling muscle disease caused by a de novo caveolin-3 mutation. *Neurology* 2001;**57**:2273-7.
- 10 McNally EM, de Sa Moreira E, Duggan DJ, *et al.* Caveolin-3 in muscular dystrophy. *Hum Mol Genet* 1998;**7**:871-7.
- 11 Herrmann R, Straub V, Blank M, *et al.* Dissociation of the dystroglycan complex in caveolin-3-deficient limb girdle muscular dystrophy. *Hum Mol Genet* 2000;**9**:2335-40.
- 12 De Paula F, Vainzof M, Bernardino AL, *et al.* Mutations in the caveolin-3 gene: when are they pathogenic? *Am J Med Genet* 2001;**99**:303-7.