

PAPER

Diagnostic value of MHC class I staining in idiopathic inflammatory myopathies

J van der Pas, G J D Hengstman, H J ter Laak, G F Borm, B G M van Engelen

J Neural Neurosurg Psychiatry 2004;**75**:136–139

See end of article for authors' affiliations

Correspondence to:
Dr G J D Hengstman,
Neuromuscular Centre
Nijmegen, Institute of
Neurology, University
Medical Centre Nijmegen,
PO Box 9101, 6500 HB
Nijmegen, Netherlands;
g.hengstman@
neuro.umcn.nl

Received 22 April 2003
In revised form
25 June 2003
Accepted 28 June 2003

Background: Identification of mononuclear cellular infiltrates in skeletal muscle tissue is the histological cornerstone of the diagnosis of idiopathic inflammatory myopathy (IIM). However, these infiltrates are not always present.

Objective: To determine whether MHC class I antigen expression on the sarcolemma, which is absent in normal muscle tissue, is upregulated in IIM and could serve as an additional diagnostic test.

Methods: Expression of MHC class I antigens was studied in 224 muscle samples of 61 adult patients with IIM (9 dermatomyositis, 23 polymyositis, 29 inclusion body myositis) and 163 controls (normal subjects and patients with various neuromuscular disorders) in a prospective blinded manner.

Results: The sensitivity of the test for diagnosing IIM was 78% (95% confidence interval (CI), 66% to 88%), with a specificity of 95% (91% to 98%). The sensitivity before the start of immunosuppressive treatment was 89% (76% to 96%). The sensitivity was not changed by including all patients who had been on immunosuppressive treatment for less than four weeks before muscle biopsy (sensitivity 90% (79% to 97%)). False positive results were found in only seven controls (4%), six of whom had a muscular dystrophy.

Conclusions: Detection of sarcolemmal MHC class I is a valid test for IIM. It is not affected by the short term use of immunosuppressive agents (less than four weeks) and it should be incorporated in the histological evaluation when the diagnosis of IIM is under consideration or needs to be excluded.

The idiopathic inflammatory myopathies (IIM) encompass a group of disorders that include dermatomyositis, polymyositis, and inclusion body myositis.¹ The histological cornerstone of the diagnosis is the identification of mononuclear cellular infiltrates in skeletal muscle tissue.¹ It is well known, though, that these infiltrates can be absent in the presence of the disease, especially after immunosuppressive treatment has been initiated.²

MHC class I expression on the sarcolemma, which is absent in normal muscle tissue, is upregulated in IIM.¹ The immunohistological detection of MHC class I on the sarcolemma might thus serve as a diagnostic test for the diagnosis of IIM.

Up to now, three large studies have been carried out on the diagnostic value of MHC class I staining in myopathies.^{3–5} These studies produced conflicting results. Appleyard *et al* and McDouall *et al* found staining in all patients with IIM and muscular dystrophy,^{3, 5} while Karpati *et al* found staining in all IIM patients but in only a few with muscular dystrophy.⁴ The three studies differed markedly in their methodology, thus leaving the issue of the potential diagnostic value of MHC class I staining for the diagnosis of IIM uncertain. We undertook the present study to determine the validity of this test for the diagnosis of IIM.

METHODS

We studied 224 patients in all—61 cases of IIM and 163 controls. The IIM cases included nine with dermatomyositis, 23 with polymyositis, and 29 with inclusion body myositis. They were seen between 1987 and 2000 at the Neuromuscular Centre Nijmegen, were evaluated clinically and immunohistologically, and were diagnosed according to established criteria.^{1, 6} The controls comprised 69 patients with a muscular dystrophy (Duchenne (35), Becker (3), various limb girdle dystrophies (15), facioscapulohumeral dystrophy (3), oculopharyngeal muscular dystrophy (7),

various distal myopathies (6)); 20 with a metabolic myopathy (mitochondrial myopathy (6), myoadenylate deaminase deficiency (5), McArdle disease (3), acid maltase deficiency (6)); 11 with a congenital myopathy (nemaline rod myopathy (7), central core myopathy (4)); 19 with neurogenic disorders; 24 with a miscellaneous neuromuscular disorder; and 20 healthy controls.

Muscle samples (both open and needle biopsy material) had been kept at -24°C at our neuromorphological laboratory. Cryostat samples were incubated for 60 minutes in a humid atmosphere with the primary mouse monoclonal antibody W6/32 (Dako monoclonal mouse, anti-human HLA class I antigen, clone W6/32; Dako Inc, Carpinteria, California, USA) which is specifically directed against a monomorphic epitope on the 45 kDa polypeptide products of the HLA-A, -B and -C loci. The W6/32 antibody was used in a dilution of 1:20. After incubation for one hour, the samples were washed in phosphate buffered saline (PBS) and the Histostain Plus kit (Zymed, San Francisco, California, USA) was used. First, biotinylated second antibody was applied for 10 minutes. After washing in PBS, sections were incubated with streptavidin-peroxidase conjugate for 10 minutes and then washed again. Sections were finally developed in a solution with hydrogen peroxide and aminoethylcarbazole, washed, and mounted in gelatine/glycerine.

The technical quality of the muscle samples was scored as sufficient or insufficient by a neurobiologist (HJtL). Judgement was based on the numbers of muscle fibres, the integrity of the cryostat sample, the direction in which the muscle biopsies were sliced (transverse satisfactory, oblique unsatisfactory), and the intensity of the staining (not too dark or too light). Samples of insufficient quality were excluded.

All muscle samples of sufficient quality were scored blindly by the same investigator (JvdP) for MHC class I expression (negative (-), only capillaries stained; positive (+), both

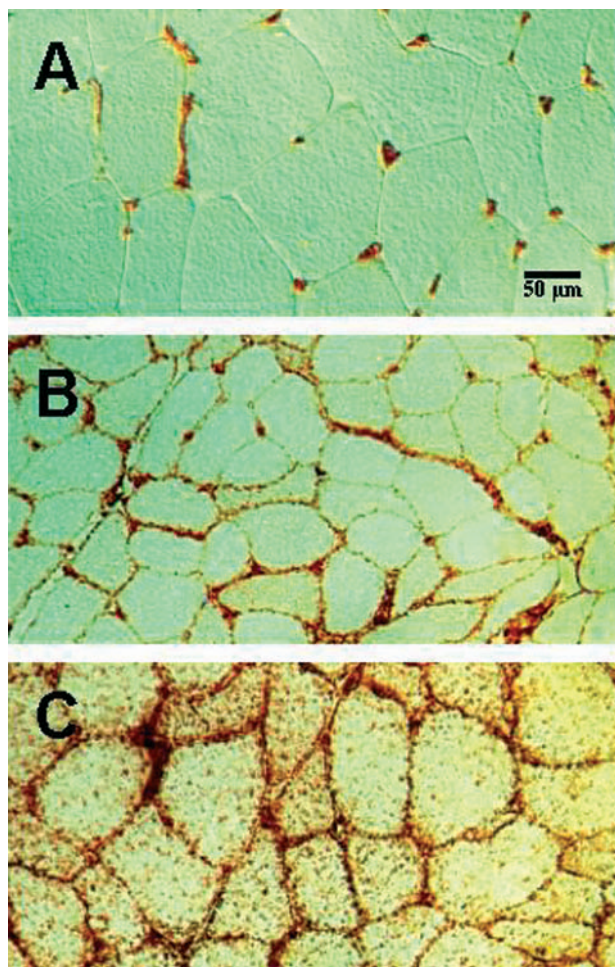


Figure 1 Illustrations of sarcolemmal MHC class I expression in muscle biopsies. (A) Negative (–): only capillaries stain MHC class I positive. (B) Positive (+): both capillaries and sarcolemma are MHC class I positive but the capillaries can still be identified easily. (C) Positive (+): both capillaries and sarcolemma are MHC class I positive but capillaries can no longer be identified.

capillaries and sarcolemma positive for MHC class I antigen (fig 1)).

To evaluate the reproducibility of this diagnostic test, intraobserver and interobserver studies were done. The first 50 samples were scored twice by the same investigator (JvdP) and subsequently by an experienced neurobiologist (HJtL). Both the intraobserver and interobserver results were very favourable: intraobserver reproducibility was 92% and interobserver reproducibility, 90%.

To determine the diagnostic value of the test, estimates and 95% confidence intervals (CI) for the sensitivity and specificity were calculated.

After completion of the analysis, data were compared with the clinical data (particularly the type and duration of immunosuppressive treatment) and other histological data.

RESULTS

Of the 224 stained muscle samples, 16 (7%) were of insufficient quality. The remaining 208 samples were used for MHC class I analysis (fig 2). A diffuse pattern of staining was observed in all samples showing positive staining of the sarcolemma. Expression of MHC class I was found in 67% of muscle biopsies from patients with dermatomyositis, in 61% with polymyositis, and in 96% with inclusion body myositis. No expression was detected in any of the patients with

congenital or metabolic myopathies or neurogenic disorders, or in the healthy controls. Expression of MHC class I was found in 11% of the biopsies from patients with muscular dystrophy and in 4% of those with a miscellaneous neuromuscular disorder.

Of the 13 false negative IIM patients, eight had been on chronic immunosuppressive treatment (for more than four weeks) before muscle biopsy (table 1). The remaining five false negative patients had no clinical or histological feature that distinguished them from the other IIM patients. All the IIM patients who were on short term immunosuppressive treatment (less than four weeks) before muscle biopsy (n = 6) had positive MHC class I staining (table 1).

Most of the false positive patients (n = 7) had a muscular dystrophy (three of Duchenne type; two with limb girdle dystrophy; one with oculopharyngeal dystrophy). None of these patients had clinical or histological features that distinguished them from the other patients with muscular dystrophy. The one patient from the miscellaneous disorders group with a positive MHC class I stain was a young woman with minimal symmetrical proximal muscle weakness, slightly raised creatine kinase, and a normal muscle biopsy, who did not meet the diagnostic criteria for any neuromuscular disorder.

The sensitivity for the detection of MHC class I expression on the sarcolemma for a diagnosis of IIM was 78% (95% CI, 66% to 88%), with a specificity of 95% (91% to 98%). The sensitivity before starting immunosuppressive treatment was 89% (76% to 96%). The sensitivity was unchanged by the inclusion of all patients who had been on immunosuppressive treatment for less than four weeks before muscle biopsy (sensitivity 90% (79% to 97%)).

In six patients, all fulfilling the established diagnostic criteria for IIM, no inflammatory infiltrates were found on muscle biopsy. In all six, the biopsy stained positive for MHC class I.

DISCUSSION

Histological confirmation, especially the identification of mononuclear cellular infiltrates, remains the cornerstone of the diagnosis idiopathic inflammatory myopathies.¹ However, this typical histological characteristic can be absent in the presence of disease.² MHC class I expression on the sarcolemma is upregulated in IIM and probably plays a key role in the pathogenesis of these diseases.^{1–7} The immunohistological detection of MHC class I antigens on the sarcolemma might thus serve as a diagnostic test for the diagnosis IIM. Another potential benefit of using the MHC class I staining of the sarcolemma as a diagnostic tool is that the MHC class I antigens are still detectable after immunosuppressive treatment has been initiated and in patients with chronic myositis, unlike the inflammatory infiltrates.⁸

The main findings of this study are the high sensitivity (90%) and specificity (95%) of MHC class I staining for the diagnosis of IIM when applied to patients who had not received immunosuppressive treatment for longer than four weeks before muscle biopsy. The main reason for a false negative test result was chronic (months to years) immunosuppressive treatment before biopsy. A short (days to weeks) duration of immunosuppressive treatment before biopsy was not associated with false negative test results, thus confirming the observations by Nyberg *et al.*⁸ False positive test results were rarely found in Duchenne and limb girdle dystrophies.

It is of interest that six patients, in whom the diagnosis IIM was based on typical clinical characteristics and histological hallmarks other than the presence of inflammatory infiltrates, showed positive MHC class I staining without mononuclear cellular infiltrates in the muscle biopsy. This can be

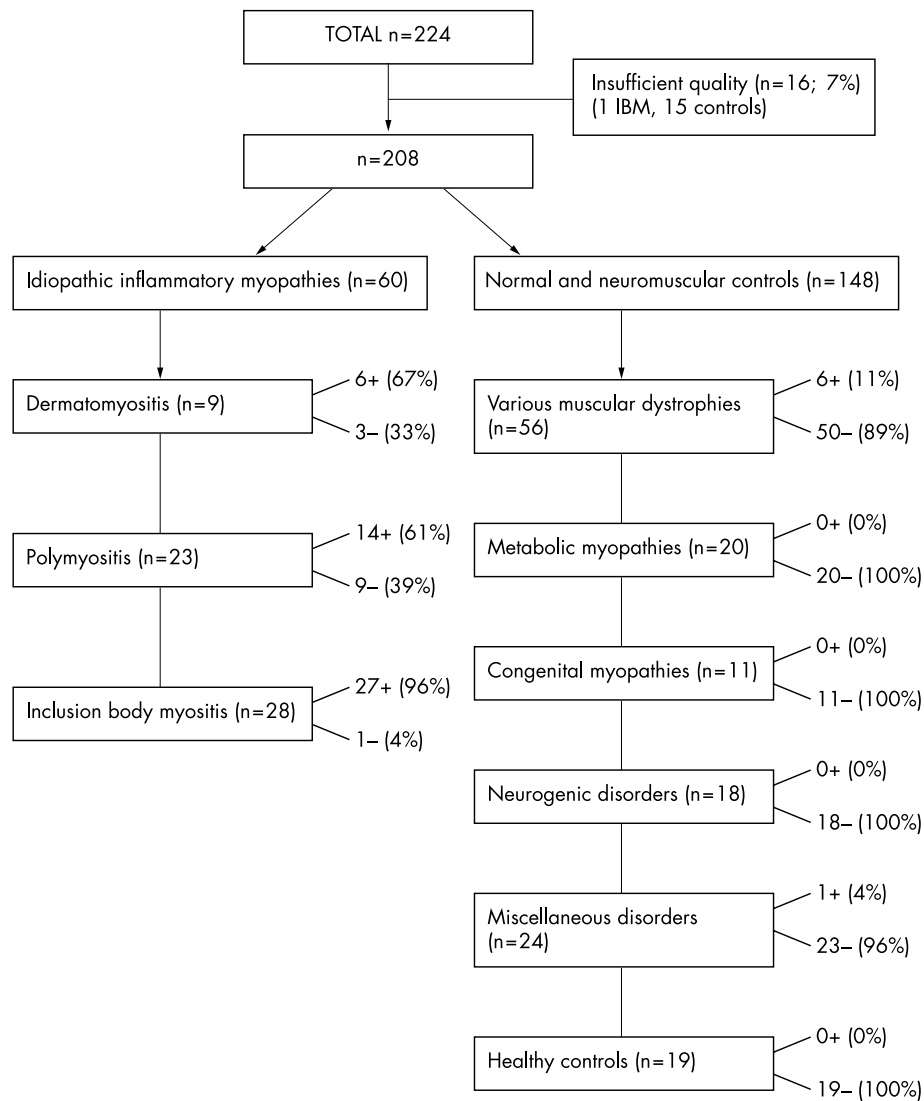


Figure 2 Design and outcome of the semiquantitative study on sarcolemmal MHC class I expression in 224 skeletal muscle samples from patients with idiopathic inflammatory myopathies (IIM), controls with various other neuromuscular problems, and healthy individuals. Numbers and percentages of samples with positive MHC class I staining (+) and negative staining (–) are listed on the right of the corresponding box.

explained by the fact that MHC class I staining is diffuse throughout the entire biopsy and is thus not affected by potential sampling errors.⁵

The three previous studies on MHC class I staining and IIM produced conflicting results, partly because of major differences in methodology.^{3–5} In the first place, Karpati *et al* used

the PHM4 antibody for their staining technique⁴ while Appleyard *et al* and McDouall *et al* used the W6/32 antibody,^{3, 5} as we did in this study. Second, in the studies by Karpati and Appleyard, the authors did not describe their method of assessing the stain. Third, Appleyard *et al* only assessed three patients with IIM, while McDouall *et al* only assessed five

Table 1 Results of MHC class I staining in relation to the diagnosis of idiopathic inflammatory myopathies and the influence of the immunosuppressive treatment before muscle biopsy

Diagnosis	No IS		IS <4 weeks (short term)		IS >4 weeks (chronic)	
	MHC-I+	MHC-I–	MHC-I+	MHC-I–	MHC-I+	MHC-I–
DM (n=9)	5	3	1	0	0	0
PM (n=23)	12	2	2	0	0	7
IBM (n=28)	24	0	3	0	0	1
Total (n=60)	41	5	6	0	0	8

Use of immunosuppressive treatment before muscle biopsy indicated by: No IS, none; IS <4 weeks, short term; IS >4 weeks, chronic. Values are absolute numbers.

DM, dermatomyositis; IBM, inclusion body myositis; IS, immunosuppressive treatment; PM, polymyositis; MHC-I–, negative MHC class I staining of the sarcolemma; MHC-I+, positive MHC class I staining of the sarcolemma.

patients with polymyositis and three with inclusion body myositis. Finally, none of the three studies mentioned whether the patients had received immunosuppressive treatment before muscle biopsy.

Conclusions

Our study shows that the detection of sarcolemmal MHC class I is a valid test for IIM and that it is not affected by the short term use of immunosuppressive agents. It should be incorporated in the histological evaluation when the diagnosis of IIM is under consideration or needs to be excluded.

Authors' affiliations

J van der Pas, G J D Hengstman, H J ter Laak, B G M van Engelen, Neuromuscular Centre, Institute of Neurology, University Medical Centre, Nijmegen, Netherlands

G F Borm, Department of Statistics, University of Nijmegen

Competing interests: none declared

REFERENCES

- 1 **Dalakas MC.** Polymyositis, dermatomyositis, and inclusion-body myositis. *N Engl J Med* 1991;**325**:1487–98.
- 2 **Matsubara S,** Hirai S, Sawa Y. Pulsed intravenous methylprednisolone therapy for inflammatory myopathies: evaluation of the effect by comparing two consecutive biopsies from the same muscle. *J Neuroimmunol* 1997;**76**:75–80.
- 3 **Appleyard ST,** Dunn MJ, Dubowitz V, *et al.* Increased expression of HLA ABC class I antigens by muscle fibres in Duchenne muscular dystrophy, inflammatory myopathy, and other neuromuscular disorders. *Lancet* 1985;i:361–3.
- 4 **Karpati G,** Pouliot Y, Carpenter S. Expression of immunoreactive major histocompatibility complex products in human skeletal muscles. *Ann Neurol* 1988;**23**:64–72.
- 5 **McDovall RM,** Dunn MJ, Dubowitz V. Expression of class I and class II MHC antigens in neuromuscular diseases. *J Neurol Sci* 1989;**89**:213–26.
- 6 **Verschuuren JJ,** Badrising UA, Van Engelen BGM, *et al.* Inclusion body myositis. In: Emery AEH, eds. *Diagnostic criteria for neuromuscular disorders*. London: Royal Society of Medicine, 1997:81–3.
- 7 **Nagaraju K,** Raben N, Loeffler L, *et al.* Conditional up-regulation of MHC class I in skeletal muscle leads to self-sustaining autoimmune myositis and myositis-specific autoantibodies. *Proc Natl Acad Sci USA* 2000;**97**:9209–14.
- 8 **Nyberg P,** Wikman A, Nennesmo I, *et al.* Increased expression of interleukin 1 α and MHC class I in muscle tissue of patients with chronic, inactive polymyositis and dermatomyositis. *J Rheumatol* 2000;**27**:940–8.