

- patients with pulmonary tuberculosis. *Chest* 1992;102:195-7.
- 5 Balbi B, Valle MT, Oddera S, Giunti D, Manca F, Rossi GA, et al. T lymphocytes with  $\gamma\delta$ +V $\delta$ 2+ antigen receptors are present in increased proportions in a fraction of patients with tuberculosis or with sarcoidosis. *Am Rev Respir Dis* 1993;148:1685-90.
  - 6 Ueta C, Tsuyuguchi I, Kawasumi H, Takashima T, Toba H, Kishimoto S. Increase of  $\gamma/\delta$  T cells in hospital workers who are in close contact with tuberculosis patients. *Infect Immun* 1994;62:5434-41.
  - 7 Barnes PF, Grisso CL, Abrams JS, Band H, Rea Th, Modlin RL.  $\gamma\delta$  T lymphocytes in human tuberculosis. *J Infect Dis* 1992;165:506-12.
  - 8 Tazi A, Bouchonnet F, Valeyre D, Cadranel J, Battesti JP, Hance AJ. Characterization of  $\gamma/\delta$  T lymphocytes in the peripheral blood of patients with active tuberculosis. *Am Rev Respir Dis* 1992;146:1216-21.
  - 9 Munk ME, Emoto M. Functions of T-cell subsets and cytokines in mycobacterial infections. *Eur Respir J* 1995;Suppl 20:668-75s.

*Thorax* 1997;52:377-379

## Bronchoalveolar lavage cell profile in methotrexate induced pneumonitis

A Schnabel, C Richter, S Bauerfeind, W L Gross

### Abstract

**Background** - Pneumonitis is a rare but potentially life threatening side effect of methotrexate treatment for rheumatoid arthritis which needs to be distinguished from interstitial lung disease due to rheumatoid arthritis.

**Methods** - To examine the value of bronchoalveolar lavage (BAL) in diagnosing methotrexate pneumonitis, the BAL cell profile of four patients with methotrexate pneumonitis was compared with findings in 16 patients with rheumatoid arthritis treated with methotrexate without clinical or radiological evidence of lung disease and eight patients with interstitial lung disease secondary to rheumatoid arthritis treated with methotrexate.

**Results** - Methotrexate pneumonitis was associated with an increase in the lymphocytes in the BAL fluid to 33-68% of total BAL cells. BAL lymphocytosis was also found in five patients in each of the two control groups. The four patients with methotrexate pneumonitis had a disproportionate increase in CD4+ cells to 72-84% of total lymphocytes and in the CD4/CD8 ratio to 17.0, 6.6, 8.7, and 4.0, respectively, figures which exceeded those of the two control groups.

**Conclusions** - Methotrexate pneumonitis was associated with lymphocytic alveolitis with a preferential increase in CD4+ cells. This pattern differs from that in interstitial lung disease due to rheumatoid arthritis and may therefore assist in making an early diagnosis of methotrexate pneumonitis.

(*Thorax* 1997;52:377-379)

Keywords: rheumatoid arthritis, methotrexate, lung, pneumonitis.

Pneumonitis is a potentially life threatening side effect of treatment with methotrexate that

requires immediate discontinuation of the drug.<sup>1</sup> Characteristically, patients experience a prodromal phase with progressive cough, dyspnoea, and malaise which can last from a few days up to several weeks. At this stage incipient methotrexate pneumonitis needs to be distinguished from interstitial lung disease due to rheumatoid arthritis.<sup>1</sup> This is usually made on clinical grounds such as the presence or absence of constitutional symptoms, the rate of progression, and the response to withdrawal of the drug. While interstitial lung disease due to rheumatoid arthritis is usually a chronic disorder which takes a slowly progressive course and is associated with minor constitutional complaints,<sup>2</sup> methotrexate pneumonitis is an acute and rapidly progressive disorder accompanied by prominent constitutional symptoms.<sup>1</sup>

The value of bronchoalveolar lavage (BAL) in this situation is unclear. We have therefore performed a study of the BAL cell profile and the immunophenotype of BAL lymphocytes in patients with rheumatoid arthritis with methotrexate pneumonitis and compared our findings with those of methotrexate treated patients with rheumatoid arthritis, with and without interstitial lung disease, to see whether characteristics of the BAL fluid help in distinguishing between these disorders.

### Methods

Three women and one man aged 59, 66, 60 and 57 years, respectively, with an established diagnosis of seropositive rheumatoid arthritis were diagnosed as having methotrexate-induced pneumonitis. Three of the patients were diagnosed according to the criteria of Carson *et al*,<sup>3</sup> comprising a clinical course consistent with a hypersensitivity reaction, resolving infiltrates on the chest radiograph after discontinuing methotrexate, exclusion of infection or other pulmonary disease, and pathology consistent with drug-induced injury. The presence of any three of these criteria was

Rheumatologische  
Poliklinik,  
Medizinische  
Universität Lübeck,  
Germany  
A Schnabel  
C Richter  
W L Gross

Medizinische  
Krankenhausabteilung  
A Schnabel  
C Richter  
W L Gross

Abteilung für  
Labormedizin  
S Bauerfeind

Rheumaklinik Bad  
Bramstedt, Oskar-  
Alexander-Straße 26,  
D-24576 Bad  
Bramstedt, Germany

Corresponding author:  
Dr A Schnabel,  
Rheumaklinik Bad  
Bramstedt, Oskar-Alexander-  
Straße 26, D-24576 Bad  
Bramstedt, Germany.

Received 18 July 1996  
Returned to authors  
30 October 1996  
Revised version received  
20 November 1996  
Accepted for publication  
20 November 1996

Table 1 Pulmonary findings in patients with rheumatoid arthritis with methotrexate induced pneumonitis, patients with rheumatoid arthritis treated with methotrexate without lung disease (methotrexate controls), and methotrexate treated patients with interstitial lung disease due to rheumatoid arthritis (methotrexate + ILD). Values of the control groups are presented as median (95% confidence intervals)

Patient groups	Lung function (% predicted)			Po <sub>2</sub> (kPa)	PCO <sub>2</sub> (kPa)	BAL cell recovery (10 <sup>4</sup> cells/ml)	BAL cell profile (%)				
	VC	FEV <sub>1</sub> /VC	TLCO/VA				Lymphocytes	Neutrophils	Eosinophils	Macrophages	
Methotrexate pneumonitis											
Patient 1	86	70	58	7.9	4.1	15.1	68	1	1	30	
Patient 2	86	91	80	11.6	4.5	21.5	62	3	0	35	
Patient 3	107	76	99	9.6	4.4	31.9	33	2	4	61	
Patient 4	104	60	76	11.2	4.5	14.3	40	0	0	60	
Methotrexate controls (n=16)	101 (89-108)	81 (78-84)	87 (73-97)	11.7 (10.0-12.8)	4.6 (4.4-4.8)	22.8 (9.2-60.6)	10 (7-18)	2 (1-3)	0		89 (74-92)
Methotrexate + ILD (n=8)	83 (68-109)	81 (58-90)	89 (5-129)	11.1 (8.8-15.1)	4.8 (4.1-5.1)	23.2 (13.4-52.8)	21 (8-33)	3 (2-9)	0		76 (67-79)

VC = vital capacity; FEV<sub>1</sub>/VC = forced expiratory volume in one second/vital capacity; TLCO/VA = carbon monoxide transfer factor corrected for haemoglobin and alveolar volume; Po<sub>2</sub>, PCO<sub>2</sub> = blood gas tensions; BAL = bronchoalveolar lavage.

required to make a diagnosis of methotrexate pneumonitis. Three patients also had scattered ground glass opacities on high-resolution computed tomographic (HRCT) scanning. Patient no. 3 had a normal chest radiograph and no pathological diagnosis was made but widespread ground glass opacities were seen on the HRCT scan. Current doses of methotrexate were 15 mg/week in patients 1, 2, and 4 and 25 mg/week in patient 3. Further characteristics are presented in table 1.

The first control group comprised 11 women and five men with rheumatoid arthritis who were being treated with methotrexate without clinical, radiological, or functional evidence of interstitial lung disease (methotrexate controls). Their median age was 59 (95% confidence interval 53-61) years, the disease duration was 90 (48-96) months, and the methotrexate dose was 22.5 (15-22.5) mg/week (table 1). The second control group included eight patients (four men) with rheumatoid arthritis who were being treated with methotrexate and who had developed interstitial lung disease secondary to rheumatoid arthritis (methotrexate + ILD). Their median

age was 62 (55-69) years, the disease duration was 78 (14-152) months, and the methotrexate dose was 15 (10-25) mg/week. These patients had mild or moderate exertional dyspnoea, which was essentially stable over time, a decreased vital capacity or carbon monoxide transfer factor, and increased interstitial markings on the chest radiograph. None had any appreciable constitutional symptoms suggestive of drug hypersensitivity. At the time of examination the four patients with methotrexate pneumonitis, seven of the eight with interstitial lung disease, and eight of the 16 methotrexate controls were on prednisone, the median daily dose being 7.5 mg in the first two groups and 5 mg in the last.

Bronchoalveolar lavage was carried out in a single lung segment with 240 ml sterile 0.9% saline. The cell differential count was determined by microscopic examination of cytopsin preparations stained with May-Giemsa-Grünwald. For immunotyping BAL lymphocytes were labelled with fluorescent anti-CD3, anti-CD4, and anti-CD8 (Coulter, Krefeld, Germany and Becton Dickinson, Heidelberg, Germany) and counted in a Coulter EPICS II flow cytometer. Infection with conventional bacterial pathogens, acid-fast bacteria, *Legionella* species, *Chlamydia* species, *Pneumocystis carinii*, and *Mycoplasma* species was excluded by appropriate methods.

## Results

No significant difference was found in the total number of BAL cells recovered from the patients with methotrexate pneumonitis and the two control groups (table 1). All four patients with methotrexate pneumonitis had an increase in the proportion of lymphocytes in the BAL fluid to 68%, 62%, 33%, and 40% (normal in this laboratory <15%). The eosinophil count was normal in all four patients but one patient had an increased proportion of eosinophils to 4% (normal <1%). Five of the 16 methotrexate controls had an increased proportion of lymphocytes with individual values ranging from 18% to 61%, and seven of the eight in the methotrexate + ILD group had an abnormal BAL cell differential with increased lymphocytes (19-52%) in five and increased neutrophils (9% and 12%) in two patients.

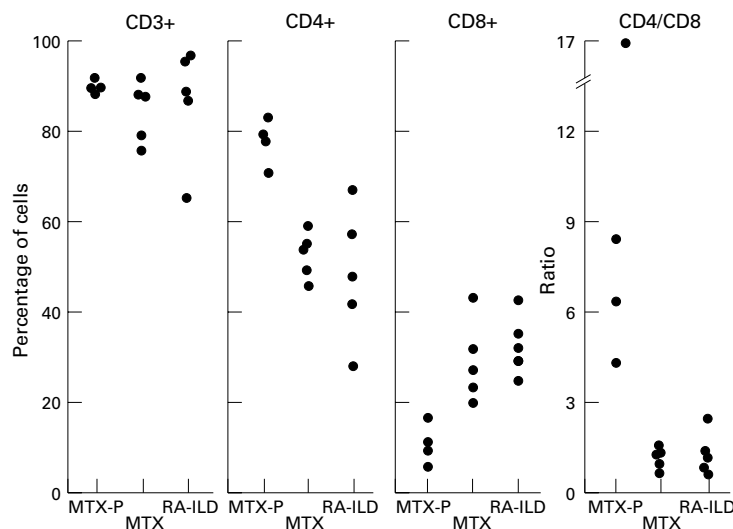


Figure 1 Subsets of lymphocytes in bronchoalveolar fluid of patients with rheumatoid arthritis (RA) with methotrexate pneumonitis (MTX-P), methotrexate treated rheumatoid arthritis without lung disease (MTX), and methotrexate treated rheumatoid arthritis with interstitial lung disease due to rheumatoid arthritis (RA-ILD).

Immunotyping of the BAL lymphocytes was performed in the four patients with methotrexate pneumonitis and the five patients in each of the control groups with increased lymphocyte counts. No difference between the groups was found for the percentage of CD3+ cells (fig 1). However, those with methotrexate pneumonitis had an increase in the percentage of CD4+ cells to 84%, 78%, 78%, and 72% of total lymphocytes resulting in CD4/CD8 ratios of 17.0, 6.5, 8.7, and 4.0, respectively. These figures clearly exceeded those of the two control groups.

### Discussion

The four patients with methotrexate pneumonitis presented with a non-productive cough and dyspnoea which progressed over a period of 3–8 weeks and were eventually accompanied by profound malaise and myalgia. One patient also developed a fever after the weekly administrations of methotrexate. All had radiographic or HRCT findings suggestive of interstitial lung disease. This picture is compatible with drug hypersensitivity and is well documented for methotrexate induced pneumonitis.<sup>13</sup> Withdrawal of methotrexate and a short course of 50 mg prednisone led to a dramatic improvement in all four patients. Tapering of prednisone was tolerated without a relapse in pulmonary or systemic signs or symptoms.

Methotrexate pneumonitis is diagnosed primarily on clinical and radiological grounds. Pulmonary biopsy specimens are of little help since the most characteristic histopathological findings – namely, interstitial infiltration with lymphocytic cells and histiocytes, scattered eosinophils and, occasionally, non-caseating granulomas – have also been observed in interstitial lung disease due to rheumatoid arthritis<sup>4</sup> and do not therefore distinguish between the two disorders.

This study confirms other reports in showing that methotrexate pneumonitis is usually associated with an increase in the proportion of lymphocytes in the BAL fluid.<sup>5–8</sup> However, BAL lymphocytosis is also a fairly common finding in patients with rheumatoid arthritis, with or without clinical and radiological evidence of lung disease, and is an indication of interstitial lung disease due to rheumatoid arthritis.<sup>9,10</sup> To our knowledge, this is the first study to show that methotrexate pneumonitis can be dis-

tinguished from interstitial lung disease due to rheumatoid arthritis by a disproportionate increase in CD4+ cells and a raised CD4/CD8 ratio. This is in agreement with two previous reports of methotrexate pneumonitis in patients with cancer<sup>7</sup> and rheumatoid arthritis.<sup>8</sup> In contrast, another study reported a decrease in CD4+ cells in two out of three patients with this condition who received methotrexate as part of a combination regimen.<sup>6</sup> It is therefore questionable whether their lung disease did indeed result from methotrexate intolerance.

Evidence is thus accumulating that methotrexate pneumonitis is generally associated with lymphocytic alveolitis with a disproportionate increase in CD4+ cells. Our study is based on observations in a small number of subjects but suggests that this pattern distinguishes methotrexate pneumonitis from that of low to moderately active interstitial lung disease due to rheumatoid arthritis. In rare cases interstitial lung disease associated with rheumatoid arthritis takes a more aggressive course<sup>2</sup> and, while the BAL cell pattern in such cases has not been determined, this might also be associated with an increase in the CD4+ BAL lymphocytes. To differentiate between lung disease associated with rheumatoid disease and methotrexate pneumonitis physicians should therefore not rely solely on BAL findings but should view these as a useful adjunct to established clinical and radiological criteria for methotrexate pneumonitis.

- 1 Barrera P, Laan RFJM, van Riel PLCM, Dekhuizen PNR, Boerbooms AMT, van de Putte LBA. Methotrexate-related pulmonary complications in rheumatoid arthritis. *Ann Rheum Dis* 1994;53:434–9.
- 2 Anaya J-M, Diethelm L, Ortiz LA, Gutierrez M, Citera G, Welsh RA, Espinoza LR. Pulmonary involvement in rheumatoid arthritis. *Semin Arthritis Rheum* 1995;24:242–54.
- 3 Carson CW, Cannon GW, Egger MJ, Ward GR, Clegg DO. Pulmonary disease during the treatment of rheumatoid arthritis with low-dose pulse methotrexate. *Semin Arthritis Rheum* 1987;16:186–95.
- 4 Yousem SA, Colby TV, Carrington CB. Lung biopsy in rheumatoid arthritis. *Am Rev Respir Dis* 1985;131:770–7.
- 5 Schnabel A, Dalhoff K, Bauerfeind S, Barth J, Gross WL. Sustained cough in methotrexate therapy for rheumatoid arthritis. *Clin Rheumatol* 1996;15:277–82.
- 6 Akoun GM, Mayaud CM, Touboul JL, Denis MF, Milleron BJ, Perrot JY. Use of bronchoalveolar lavage in the evaluation of methotrexate lung disease. *Thorax* 1987;42:652–5.
- 7 White DA, Rankin JA, Stover DE, Gellene RA, Gupta S. Methotrexate pneumonitis – bronchoalveolar lavage findings suggest an immunologic disorder. *Am J Respir Dis* 1989;139:18–21.
- 8 Pourel J, Guillemin F, Fener P, Webanck L, Bene M-C, Delorme N. Delayed methotrexate pneumonitis in rheumatoid arthritis. *J Rheumatol* 1991;18:303–4.
- 9 Garcia JGN, Parhami N, Killam D, Garcia PL, Keogh BA. Bronchoalveolar lavage fluid evaluation in rheumatoid arthritis. *Am Rev Respir Dis* 1986;133:450–4.
- 10 Scherak O, Popp W, Kolarz G, Wottawa A, Ritschka L, Braun O. Bronchoalveolar lavage and lung biopsy in rheumatoid arthritis. In vivo effects of disease modifying antirheumatic drugs. *J Rheumatol* 1993;20:944–9.