

Case reports

Tracheal botryomycosis in a patient with tracheopathia osteochondroplastica

Jin-Yuan Shih, Po-Ren Hsueh,
Yih-Leong Chang, Li-Na Lee,
Yee-Chun Chen, Ming-Fong Chen,
Kwen-Tay Luh

Abstract

Tracheal botryomycosis has never been reported in the literature. A 68 year old man presented with progressive dyspnoea and an exophytic mass below the vocal cords was found by bronchoscopy. Pathological study of the mass showed tracheal botryomycosis probably associated with *Peptostreptococcus* spp infection. The patient was given intravenous penicillin for six weeks. Tracheal obstruction necessitated tracheal resection and the surgical specimen revealed typical findings of tracheopathia osteochondroplastica without residual lesions of botryomycosis. (Thorax 1998;53:73-75)

Keywords: botryomycosis, tracheopathia osteochondroplastica, airway obstruction.

Botryomycosis is an uncommon chronic suppurative bacterial infection. Both cutaneous and visceral forms have been described.¹⁻⁵ Visceral botryomycosis is less common and affected organs have included the liver,² kidney, brain,³ prostate gland, orbit, tongue, ear, bowels and lung.⁴ However, botryomycosis of the trachea has never been reported.

Tracheopathia osteochondroplastica is an unusual disorder in which nodules of metaplastic bone and cartilage develop in the submucosa of the trachea.⁶⁻⁹ This condition is usually asymptomatic and has a benign course.^{6,7} To date more than 300 cases of tracheopathia osteochondroplastica have been reported, but concomitant bacterial infection of the trachea has not been described in detail.

The case history of a patient with airway obstruction caused by tracheal botryomycosis and tracheopathia osteochondroplastica is presented.

Case report

A 68 year old man presented with progressive dyspnoea for six months and syncope which had developed just before arrival at the emergency department. He had smoked one pack of cigarettes a day for 40 years. He had suffered diabetes mellitus and hypertension, both under

regular medical control, for more than 10 years and had had a stroke about 10 years previously. Progressive exertional dyspnoea, which could be relieved by rest, had bothered him for several months. For the previous two weeks he had experienced episodic dyspnoea with loud breathing sounds, even at rest.

Sudden onset of severe dyspnoea with cold sweating, nausea, dizziness and syncope had occurred before arrival at the emergency department. On examination he was alert, afebrile, slightly tachypnoeic, with diffuse wheezes during the inspiratory and expiratory phase. The chest radiograph was negative. The leucocyte count was $9.2 \times 10^9/l$ (60% neutrophils, 32% lymphocytes) and the haemoglobin was 12.1 g/dl. Tachypnoea and cyanosis followed by respiratory arrest occurred later in the emergency room. After cardiopulmonary resuscitation he was in a comatose state and was admitted to the critical care unit. Extubation was performed on the third day. A foul smell of exhaled air, blood-tinged sputum, episodic dyspnoea, orthopnoea, and stridor were noted. Bronchoscopic examination revealed a whitish exophytic mass with an irregular surface which almost completely occluded the tracheal lumen below the vocal cords (fig 1). The bronchoscope was not advanced further. Tracheostomy was performed immediately. A computed tomographic (CT) scan of the neck revealed an ill-defined mass of soft tissue density in the upper trachea which was excised using laryngomicroscopy. Profuse foul pus drained from the tracheostoma which, when cultured, yielded a heavy growth of *Peptostreptococcus* species. A second bronchoscopic examination showed that there were multiple whitish ulcerations and nodules on the tracheal wall from the subglottic area to the tracheostoma; the trachea below the stoma, both main bronchi, and the lobar and segmental bronchi were spared. Pathological examination

Department of
Internal Medicine
J-Y Shih
Y-C Chen
M-F Chen

Department of
Pathology
Y-L Chang

Department of
Laboratory Medicine
P-R Hsueh
L-N Lee
K-T Luh

National Taiwan
University Hospital,
7 Chung-Shan South
Road, Taipei, Taiwan

Correspondence to:
Dr Li-Na Lee.

Received 13 November
1996

Returned to authors
23 January 1997

Revised version received
10 February 1997

Accepted for publication
14 March 1997

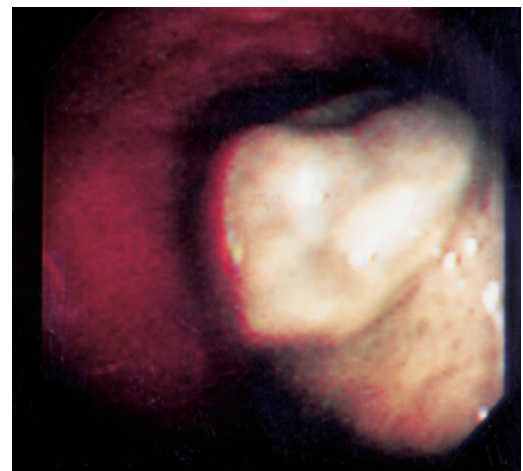
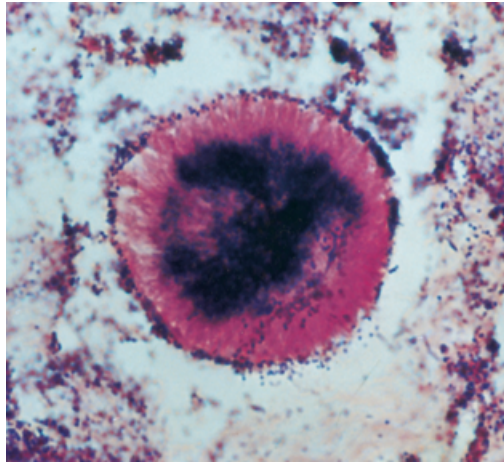


Figure 1 Bronchoscopic examination showing a whitish exophytic mass with irregular surface almost completely occluding the tracheal lumen at the subglottic area.

Figure 2 Gram stain of the sulphur granule-like lesion showing clusters of Gram-positive cocci surrounded by radially arranged material. Original magnification $\times 330$.



of the excised mass revealed sulphur granule-like material surrounded by a necrotic substance and inflammatory cells on haematoxylin and eosin staining. A fragment of cartilage accompanying the granules was found. Gram staining revealed many clusters of Gram-positive cocci scattered within and outside the eosinophilic hyaline material (fig 2). Stains for fungi (periodic acid-Schiff and Gomori's methenamine silver stains) and acid-fast bacilli were negative.

The diagnosis of tracheal botryomycosis was made and treatment with intravenous penicillin was commenced. Anti-HIV antibody was negative and serum levels of immunoglobulin subsets were normal. Lymphocyte subsets determined by flow cytometry demonstrated 74% CD3+ (normal 74.2 (2.5)%), 26.4% CD4+ (absolute CD4 count $491/\text{mm}^3$), 47% CD8+, CD4/CD8 ratio 0.56 (normal 1.48 (0.05)), and 9.5% CD19+ (normal 11.3 (2.4)%).

After treatment with penicillin for four weeks bronchoscopic examination showed an improvement in tracheal inflammation and diameter but some nodules with a smooth surface were still present on the tracheal wall. Bron-

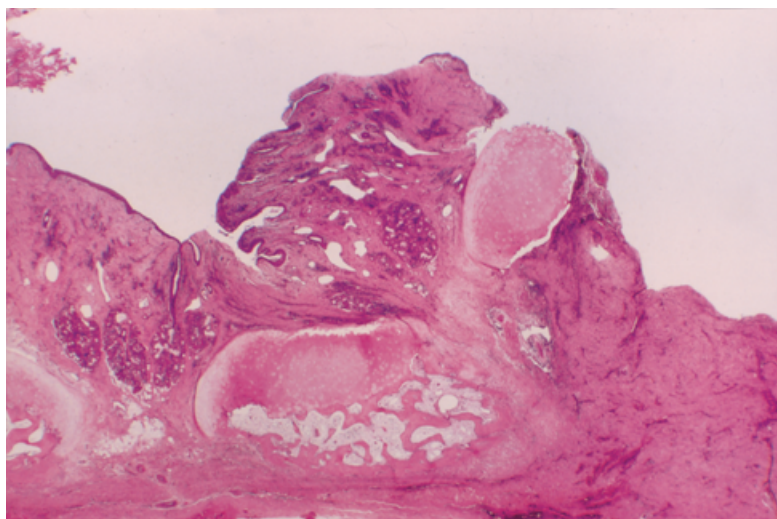


Figure 3 Photomicrograph of the surgical specimen showing squamous metaplasia of the tracheal mucosal epithelium and islands of cartilage with lamellar bone possessing haematopoietic marrow elements in the submucosa. Stain: haematoxylin and eosin; original magnification $\times 3.3$.

choscopic examination after six weeks of treatment showed that the trachea had narrowed to a slit with the nodules increased in size. Spirometric testing showed a forced vital capacity of 1.591 (56% of predicted value) and forced expiratory volume in one second of 0.551 (20.6% of predicted value). The flow-volume loop revealed a pattern of fixed upper airway obstruction. Because of the persistent tracheal obstruction, and to determine the underlying tracheal disease, surgical resection was performed. The trachea was markedly adherent to the surrounding tissue. A $2 \times 1 \times 1$ cm ill defined mass of tumour-like tissue was noted on the tracheal wall. The trachea was resected for 2.5 cm from the tracheostomy site to the cricoid cartilage. Suprahyoid release of the larynx and end-to-end anastomosis of the trachea were performed. Pathological examination revealed squamous metaplasia of mucosal epithelium, islands of cartilage with foci of lamellar bone possessing haematopoietic marrow elements in the submucosa, and dense granulation tissue and fibrous tissue (fig 3). Gram staining showed no bacteria or sulphur granule-like material. Staining with Congo red was negative. The pathological diagnosis was tracheopathia osteochondroplastica. A review of the CT scan of the neck revealed calcified plaques and nodules along the lateral surfaces of the tracheal wall. After surgery the patient suffered from nosocomial pneumonia and respiratory failure and a tracheostomy was performed below the anastomotic site. After two months he was weaned off the ventilator. Follow up bronchoscopic examination showed granulation tissue (proved by biopsy) at the tracheostoma; however, the anastomotic site healed well and no residual tumour was found.

Discussion

Botryomycosis is an infection caused by non-filamentous bacteria. Many pathogens have been identified as causative agents, including *Staphylococcus aureus*, *Streptococcus* spp, *Peptostreptococcus* spp, *Proteus* spp, *Pseudomonas aeruginosa*, *Escherichia* spp, *Neisseria* spp, *Serratia marcescens*, and *Moraxella nonliquefaciens*.¹⁻⁵ *Peptostreptococcus* spp is an organism of normal oral flora. Maves *et al* reported a case of *Peptostreptococcus* cultured from a botryomycotic lesion in a patient with a recurrent cheek mass.⁵ In the case presented here *Peptostreptococcus* spp was isolated from the pus and was compatible with the Gram-positive cocci identified by histological examination. Its low virulence is typical of isolates from botryomycosis lesions.^{4,5} Botryomycotic granules are composed of bacterial colonies that are surrounded by amorphous, eosinophilic, and radially arranged clubs (Splendore-Hoeppli material).¹⁻⁵ They are indistinguishable from those of the actinomycosis and eumycetomas by haematoxylin and eosin staining and special stains are necessary for differential diagnosis.¹⁻³ The presence of Gram-positive cocci by Gram staining and the absence of branching hyphae by periodic acid-Schiff and Gomori's methenamine silver stains helped to establish the diagnosis of

botryomycosis in this case. A fragment of cartilage accompanying the granules suggested an underlying cartilaginous disorder or metaplasia of chronic inflammation.

Neither the pathogenesis of botryomycosis nor the aetiology of tracheopathia osteochondroplastica has yet been determined. The following factors may be responsible for the pathogenesis of botryomycosis: (1) local trauma, (2) foreign body, (3) size of bacteria inoculum, (4) organisms of low virulence, and (5) immunodeficiency of host.²⁻⁵ Many aetiological factors have been proposed for tracheopathia osteochondroplastica including chronic infection, chemical or mechanical irritation, degeneration, metabolic factor, amyloidosis, ecchondrosis and exostosis, and metaplasia of elastic tissue.⁶⁻⁹

The concomitant occurrence of tracheal botryomycosis and tracheopathia osteochondroplastica is interesting. We propose that tracheopathia osteochondroplastica was the underlying disease and that the infection was established possibly by poor oral hygiene, aspirated peptostreptococci, ulcerated overlying mucosa, and the immunological defect of diabetes mellitus (which has been reported previously in a patient with botryomycosis²). Conversely, the osseous metaplasia of the cartilage and fibrous connective tissue could be a response to a longstanding chronic infection.⁹ Prolonged use of antibiotics for botryomycosis is usually required because the matrix covering the granules can be a barrier to the penetration of antibiotics.⁵ Thus, treatment with intravenous penicillin was continued for six weeks and the surgical specimen confirmed resolution

of the infection. However, the inflammatory response to the infection led to granulation and fibrous tissue formation with further narrowing of the tracheal lumen, in spite of the fact that the bacteria were eradicated.¹⁰

This case is interesting for four reasons. Firstly, this is the first report of tracheal botryomycosis; secondly, the combination of tracheal botryomycosis and tracheopathia osteochondroplastica as a cause of airway obstruction suggests that the underlying disease should be sought in cases of tracheal botryomycosis; thirdly, the microbiological response of tracheal botryomycosis to laryngoscopic excision and antibiotic treatment was good; and fourthly, the interaction of the two diseases led to rapid progression of the tracheal stenosis.

- Greenblatt M, Heredia R, Rubenstein L, Alpert S. Bacterial pseudomycosis ("botryomycosis"). *Am J Clin Pathol* 1964; **41**:188-93.
- Omar T, Cooper K. Botryomycosis of the liver. *Histopathology* 1995; **27**:71-3.
- Gillock CB, Sahni KS, Mumaw VR, Meier FA. Cerebral botryomycosis: case study. *J Infect Dis* 1990; **162**:765-7.
- Katapadi K, Pujol F, Vuletin JC, Katapadi M, Pachter BR. Pulmonary botryomycosis in a patient with AIDS. *Chest* 1996; **109**:276-8.
- Maves MD, Aguiar SW, Massanari RM, Robinson RA. Botryomycosis of the oral cavity. *Head and Neck* 1989; **11**:274-8.
- Nienhuis DM, Prakash UBS, Edell ES. Tracheobronchopathia osteochondroplastica. *Ann Otol Rhinol Laryngol* 1990; **99**:689-94.
- Tukiaainen H, Torkko M, Terho EO. Lung function in patients with tracheobronchopathia osteochondroplastica. *Eur Respir J* 1988; **1**:632-5.
- Lundgren R, Sjernberg NL. Tracheopathia osteochondroplastica: a clinical bronchoscopic and spirometric study. *Chest* 1981; **80**:706-9.
- Härmä RA, Suurkari S. Tracheopathia chondro-osteoplastic. A clinical study of thirty cases. *Acta Otolaryngol* 1977; **84**:118-23.
- Molloy AR, McMahon JN. Rapid progression of tracheal stenosis associated with tracheopathia osteo-chondroplastica. *Intensive Care Med* 1988; **15**:60-2.

Infection with feline *Chlamydia psittaci*

Mark M Cotton, Martyn R Partridge

Abstract

A 48 year old man presented with malaise, fever, and progressive mental impairment. Chest radiography showed left lower lobe consolidation. A diagnosis of atypical pneumonia was made and, following treatment with erythromycin and acyclovir, his symptoms rapidly resolved. Asymptomatic biochemical hepatitis persisted for many weeks. Serological examination subsequently showed infection with feline *Chlamydia psittaci*.

(*Thorax* 1998; **53**:75-76)

Keywords: feline *Chlamydia psittaci*, hepatitis, pneumonia.

A 48 year old white male computer analyst was referred as an emergency to the chest clinic by his general practitioner after a one week history of illness. On the first day of illness he felt generally unwell and had difficulty finding words. The next day he felt sick and vomited, and on

the fourth day was unsteady when walking. A diagnosis of food poisoning was made at a local casualty department and he was advised to rest. On days 5 and 6 he was febrile and delirious having visual hallucinations.

The patient had no past medical history of note. He had not travelled abroad and there was no history of bird contact although he had a healthy cat at home. There were no risk factors for HIV infection.

On examination he appeared well but tachypnoeic. Coarse crackles were heard in the left mid zone on auscultation of the chest. No focal neurological deficit was found, but assessment of higher mental functions was abnormal. Although orientated, he had sparse speech, poor concentration, difficulty in naming common objects, difficulty in reading, and could not write a sentence. He was completely unable to recall a simple address, and serial 7s were only successful to 93.

A chest radiograph revealed a left lower lobe pneumonia. A computed tomographic (CT) scan of the brain was normal. Full blood count including differential white cell count was normal, but his ESR was elevated at 70 mm in the first hour. No cold agglutinins were present. Apart from mild hyponatraemia (Na 130 mmol/l) the electrolytes were normal. He had a raised alkaline phosphatase of 227 IU (normal <120 IU) and alanine transaminase 145 IU (normal <40 IU). Cerebrospinal fluid microscopy, protein

Chest Clinic,
Whipps Cross
Hospital,
London E11 1NR, UK
M M Cotton
M R Partridge

Correspondence to:
Dr M R Partridge.

Received 20 September
1996

Returned to authors
4 November 1996

Revised version received
28 February 1997

Accepted for publication
1 April 1997