

Arrhythmias in the congenital long QT syndrome: how often is torsade de pointes pause dependent?

S Viskin, R Fish, D Zeltser, B Belhassen, K Heller, D Brosh, S Laniado, H V Barron

Abstract

Objective—To determine the frequency and predictors of pause dependent torsade de pointes among patients with the congenital long QT syndrome and spontaneous ventricular tachyarrhythmias.

Design—The literature on the “congenital long QT” was reviewed. Articles with illustrations demonstrating the onset of spontaneous polymorphic ventricular arrhythmias in the absence of arrhythmogenic drugs were included.

Results—Illustrations of 62 spontaneous episodes of torsade de pointes among patients with congenital long QT syndrome were found in the literature. The majority (74%) of documented arrhythmias were “pause dependent”; 82% of these pauses were longer than the basic cycle length by > 100 ms. Age and sex correlated with the mode of arrhythmia initiation. Arrhythmias in infants (≤ 3 years old) were not pause dependent, while female sex correlated with pause dependent torsade. Using multivariate analysis, age was the only independent predictor of the mode of onset of torsade de pointes.

Conclusion—Available data suggest that the majority of spontaneous arrhythmias in the congenital long QT syndrome are pause dependent. Torsade de pointes that is not preceded by pauses appears to be limited to patient subgroups with severe forms of the disease, like symptomatic infants. These findings have important implications regarding the use of cardiac pacing for arrhythmia prevention.

(Heart 2000;83:661–666)

Keywords: long QT; congenital long QT syndrome; torsade de pointes; ventricular tachycardia

Department of
Cardiology,
Sourasky-Tel Aviv
Medical Center,
Sackler-School of
Medicine, Tel Aviv
University, Israel

S Viskin
R Fish
D Zeltser
B Belhassen
K Heller
D Brosh
S Laniado

Cardiovascular
Research Institute,
University of
California, San
Francisco, California,
USA

H V Barron

Correspondence to:
Dr S Viskin, Department of
Cardiology, Tel Aviv Medical
Center, Weizman 6, Tel Aviv
64239, Israel
email:
viskin_s@netvision.net.il

Accepted 6 January 2000

Table 1 Patients with congenital long QT syndrome and documented torsade de pointes reported in the literature

	Patients reported in our original series ^a	Patients reported by others ^{†,‡,§,¶,7,8,9,10,11,12}	All patients
Number of patients.	15	47	62
Age (SD)‡ in years	28 (19)*	18 (16)§	21 (17)
Infants (≤ 3 years old)	1 (7%)	9 (21%)§	10 (19%)
Females	12 (80%)	28 (72%)§	40 (74%)
Deafness	0	6 (15%)§	6 (11%)
Mean (SD) QTc (ms)	589 (85)	575 (82)	579 (75)
QT score ^{7†} (range)	5.2 (4–6.5)	5.5 (4–6.5)	5.6 (4–6.5)
No β blocker treatment‡	13 (87%)	33 (76%)§	46 (79%)
Pause dependent TdP	14 (93%)	32 (68%)	46 (74%)

* $p < 0.05$ when comparing the results in our series with those published by others.

†Including one patient reported by us³ after publication of our original series.²

‡At the time of arrhythmia documentation.

§Data on age, sex, history of deafness and number of patients receiving treatment at the time of arrhythmia documentation was not available for 5, 6, 7 and 4 patients published by others, respectively.

Characterisation of the mode of onset of spontaneous ventricular arrhythmias in the long QT syndrome has important clinical implications.^{1,2} Specifically, the frequency by which torsade de pointes is preceded by sudden decrements in cycle length—that is, is “pause dependent”—could affect the role of cardiac pacing for arrhythmia prevention.^{3,4}

We recently evaluated the frequency of “pause dependent” torsade de pointes in patients with congenital long QT syndrome who had documented spontaneous arrhythmias.² In our original series,² the majority of arrhythmic episodes (in 14 of 15 patients) were preceded by pauses (either sinus pauses or post-extrasystolic pauses). These results, however, deviated from the prevailing view in the literature, which equated “pause dependent torsade de pointes” with the acquired, rather

than the congenital long QT syndrome.^{5–8} Moreover, our study had important limitations (like the limited number of documented arrhythmias), which precluded generalisation of our findings. We therefore reviewed the literature of the congenital long QT syndrome, searching for additional illustrations of spontaneous arrhythmias, to identify clinical predictors of the mode of onset of torsade de pointes.

Methods

We reviewed the English literature on “torsade de pointes” and the “congenital long QT”. All published articles, with illustrations demonstrating the onset of spontaneous arrhythmias in patients with a congenital long QT, were included. Reports were excluded if: (1) the documented arrhythmias occurred in the setting of potentially torsadogenic metabolic abnormalities or drug treatment; (2) the poor quality of the illustrations, or the absence of at least three complexes before arrhythmia initiation, precluded classification of the arrhythmia as “pause dependent” or “non-pause dependent”. Reports from the University of California San Francisco,^{9–12} which included patients also reported in our original series describing the mode of onset of torsade de pointes,² were not included in the present study in order to avoid potential double counting.

Torsade de pointes was defined as a polymorphic ventricular tachycardia lasting > 3 beats (all but six episodes lasted ≥ 10 beats) and was considered to be pause dependent when the arrhythmia was immediately preceded by a pause that was longer than the basic

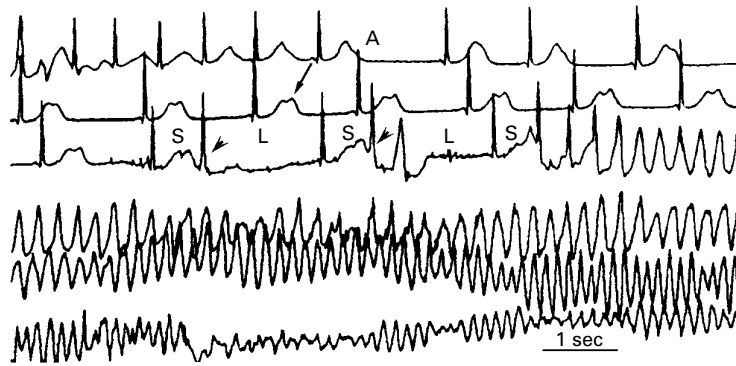


Figure 1 Spontaneous torsade de pointes in a 25 year old female with congenital LQTS reported by Benhorin and Medina.⁶ This Holter recording shows the sequence of events that is typical of pause dependent torsade de pointes. Sinus tachycardia is followed by a sudden decrement in sinus rate (A) with concomitant augmentation of the U wave amplitude (arrow). Eventually, an extrasystole (arrowhead) is followed by a long post-extrasystolic pause. The sinus complex that follows the pause shows further U wave augmentation and is followed by more extrasystoles (arrowhead), which in turn, trigger a new pause. This creates a series of short (s) and long (l) cycles that culminate in torsade de pointes. Reproduced with permission from the authors and the Massachusetts Medical Society (copyright © 1997 Massachusetts Medical Society).

cycle length by at least 40 ms. Also, if torsade followed a period of ventricular bigeminy, it was considered to be pause dependent (even if the undisturbed basic cycle length was unknown) as long as the post-extrasystolic interval was longer than the coupling interval of the preceding extrasystole by at least 40 ms. The 40 ms value was chosen because this was the smallest interval increment that could be reproducibly recognised. As in a previous study,² the identified pauses were, in fact, considerably longer than the basic cycle length (see below).

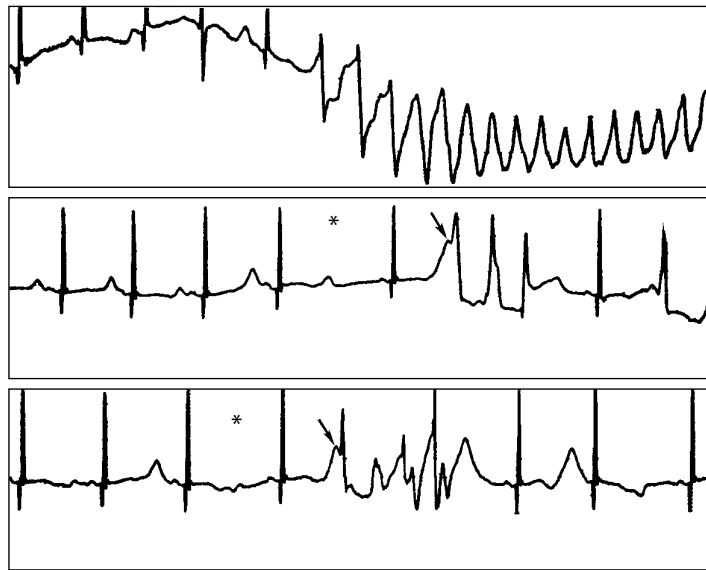


Figure 2 The top trace shows what is probably the most famous example of non-pause dependent torsade de pointes. It was originally published by Malfatto and colleagues³⁶ and is commonly cited as a typical example of adrenergic dependent torsade de pointes.³⁵ The preceding sinus rate is 90 beats per minute and there is no pause before the onset of the arrhythmia. This 11 year old female patient also had documented pause dependent torsade de pointes (middle and bottom panels): Sudden sinus pauses (*) are followed by sinus complexes with tall bizarre TU waves (arrows) from which short bursts of torsade de pointes originate. Reproduced with permission from the authors and Futura Publishing Company Inc, publisher of the *Journal of Cardiovascular Electrophysiology*.

Results

In addition to the 15 patients with congenital long QT syndrome reported in our original series,² we found 62 illustrations of torsade de pointes in 54 articles published by others.^{3 6 13-51 52 53-64} Fifteen of these patients were excluded for the following reasons. Five patients with a congenital long QT syndrome and pause dependent torsade were excluded because the illustrated arrhythmias occurred during hypokalaemia,⁵² hypomagnesaemia⁵³ or during treatment with imipramine,⁵⁴ astemizole⁵⁹ or after amiodarone discontinuation.⁶¹ One patient with non-pause dependent tachycardia was excluded because the arrhythmia appeared to be related to an old myocardial infarction.⁵⁵ Five patients were excluded because the poor quality of the ECG or the absence of ≥ 3 complexes before arrhythmia initiation precluded classification of the arrhythmia.^{51 56-58 60} In addition, four arrhythmia illustrations that were repeatedly published—first in original articles^{15 20 36 38} and later in reviews^{6 45 64}—were included only once. Thus, the present report includes 62 patients with documented torsade de pointes, including 15 patients reported in our original series² and 47 patients reported by others.^{3 6 13-20 22-37 39-50 62}

The majority of arrhythmia illustrations, in patients with congenital long QT syndrome reported by others, also demonstrated pause related arrhythmias (table 1, fig 1). However, the percentage of arrhythmias preceded by pauses among patients reported by others (68%) was less than the preponderance of pause dependent arrhythmias (93%) observed in our original series.² Based on all available data (62 patients), it appears that torsade de pointes is pause dependent in roughly three out of four symptomatic patients with congenital long QT syndrome (table 1). Only two patients^{15 36} demonstrated both type of arrhythmias (fig 2).

The R-R cycles that preceded the onset of pause dependent arrhythmias are shown in fig 3. The ratio between the short cycle and the long cycle immediately leading to torsade was large enough to make the diagnosis of “pause dependent” arrhythmias evident (figs 1, 2, and 3). Although a 40 ms increment in cycle length

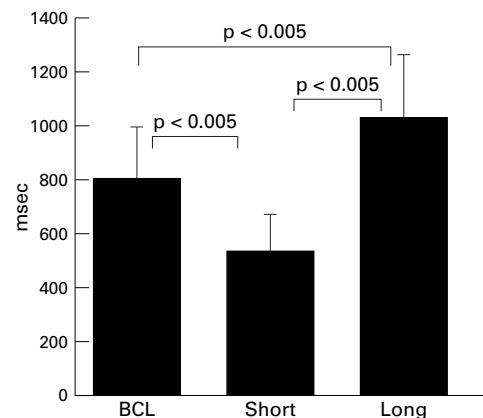


Figure 3 R-R intervals preceding the onset of arrhythmias in patients with pause dependent torsade de pointes. BCL, basic cycle length; short and long, short cycle and long cycle immediately preceding the onset of torsade.

Table 2 Mode of onset of torsade de pointes in patients with congenital long QT syndrome and documented arrhythmias†

	Pause dependent arrhythmias	Non-pause dependent arrhythmias
Number of patients	46 (74%)	16 (26%)
Age (SD) in years‡§	27 (16)*	5 (7)
Infants (≤ 3 years old)§	1 (2%)*	8 (53%)
Females§	33 (80%)*	7 (54%)
Deafness§	3 (7%)	3 (21%)
Mean (SD) QTc (ms)	569 (77)	620 (49)
Mean (SD) QT score ⁷⁷	5.4 (0.6)	5.6 (0.8)
Stress related arrhythmias	26 (79%)	14 (100%)‡
No β blocker treatment§	35 (79%)	12 (86%)

*p < 0.05.

†Data from all patients shown in table 1.

‡All in-hospital arrhythmias in newborns were presumed to be stress related. For older patients, a history of out-of-hospital syncope or cardiac arrest following physical or emotional stress (including sudden arousal) was used as evidence for stress related arrhythmias (data were not available for 15 patients reported by others).

§Data on age, sex, history of deafness, and number of patients receiving treatment at the time of arrhythmia documentation was not available for 5, 6, 7 and 4 patients published by others, respectively.

was used as a definition of “pause” (see Methods), in fact 85% and 82% of the “pauses” preceding torsade were longer than the basic cycle length by > 60 ms or by > 100 ms, respectively. Moreover, a “short-long-short” sequence (an extrasystole, followed by a post-extrasystolic pause) immediately preceded the onset of torsade de pointes in most arrhythmic events (see below). In such cases, the post-extrasystolic “long cycle” leading to torsade was longer than

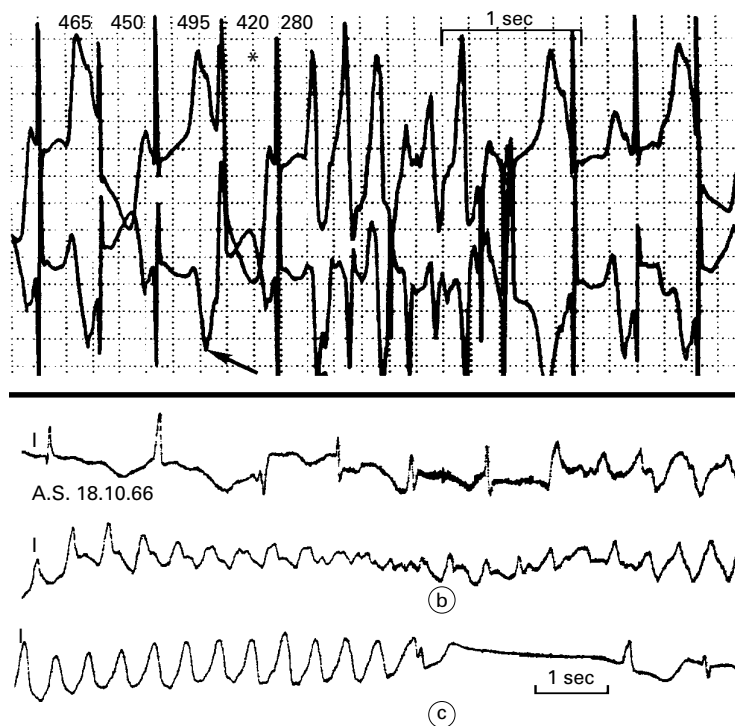


Figure 4 (A) Non-pause dependent torsade de pointes in a neonate.⁴⁷ There is sinus tachycardia with marked T wave alternans. Although there appears to be some R-R alternans (the R-R intervals are shown in milliseconds), the interval immediately preceding the sinus complex from which torsade originates, which would be expected to be the longest interval if this was a pause dependent arrhythmia (*), is actually short (420 ms). Reproduced with permission from the authors and Futura Publishing Company Inc, publisher of the *Journal of Cardiovascular Electrophysiology*. (B) One of the first cases of congenital long QT syndrome and deafness described.¹⁶ The QT interval is giant and bizarre. Torsade de pointes is not preceded by a pause. Reproduced with permission from Mosby Inc, publisher of *Advances in Internal Medicine*.

the previous “short cycle” (created by the extrasystole) by more than 200 ms in 84% of events. Finally, electrocardiographic features supporting the causative role of pauses—like observation of “post-pause U wave augmentation”,⁶ reproducible arrhythmia initiation after pauses, or an escalating sequence of events (in which longer pauses are followed by faster bursts of ventricular tachycardia)⁶⁵—were common among our patients² and were seen in the majority of illustrations reported by others.^{3 6 15 17 18 22 25 28 30 32 33 35-37 44 46 62 63}

The pauses eventually leading to torsade de pointes were mainly “compensatory pauses” following extrasystoles. These post-extrasystolic pauses were observed in 28 patients reported by others^{3 6 7 13 15 18 19 21-23 25 26 28 30-33 35 37 42-46 48-50 62} and in all but two of the patients reported by us.² In all, post-extrasystolic pauses, sudden sinus pauses, or both, preceded the onset of torsade de pointes in 73%, 14%, and 15% of all patients with pause dependent arrhythmias, respectively.

COMPARISON OF PATIENTS WITH PAUSE DEPENDENT VERSUS NON-PAUSE DEPENDENT ARRHYTHMIAS

Age and sex correlated with the mode of onset of torsade de pointes (table 2). Arrhythmias in newborns and infants (≤ 3 years old) were predominantly not pause dependent (fig 4), whereas female sex correlated with pause dependent arrhythmias. Using multivariate analysis, age was the only independent predictor of the mode of onset of torsade de pointes.

It is difficult to assess the importance of “stress” as a precipitating factor of arrhythmias not preceded by pauses, because the majority of such arrhythmias were recorded in hospitalised newborns. Nevertheless, 76% of patients with documented pause dependent torsade de pointes had a history of syncope or cardiac arrest preceded by physical or emotional stress.

Discussion

This review supports our observations regarding the mode of onset of torsade de pointes in the congenital long QT syndrome.² Although the predominance of pause dependent arrhythmias was not as pronounced as originally reported in our series,² the majority of spontaneous arrhythmias documented in the literature were also pause dependent (table 1, figs 1, 2, and 3). Most patients with congenital long QT syndrome and pause dependent arrhythmias had a history of stress related arrhythmias (table 2). This implies that the terms “adrenergic dependent” and “pause dependent” torsade de pointes, which are too often equated with the congenital and the acquired long QT syndrome, respectively, are not mutually exclusive.

PAUSE DEPENDENT TORSADE DE POINTES

The fact that arrhythmias were preceded by pauses does not prove cause and effect. It could be argued that torsade de pointes should be labelled “pause related” rather than “pause dependent”. However, the marked QTU changes, that become apparent immediately after pauses, appear to represent enhanced early after depolarisations (or increased dispersion of

repolarisation) following sudden increments in cycle length.^{5 6 37 66 67} Furthermore, the escalating sequence of events, in which longer pauses are followed by faster runs of torsade de pointes,⁶⁵ supports the notion that pauses indeed favour the onset of torsade de pointes. In contrast, idiopathic polymorphic ventricular tachyarrhythmias in patients without a long QT syndrome are generally not preceded by pauses.^{1 68}

The univariate association between female sex and pause dependent torsade de pointes is of interest because acquired forms of the long QT syndrome, which are essentially always pause dependent, are also more common in women.^{69 70} However, this association was not confirmed by multivariate analysis in our series.

NON-PAUSE DEPENDENT TORSADE DE POINTES

Torsade de pointes that was not pause dependent was seen predominantly in infants (table 2). Typically, infants would develop torsade following periods of sinus tachycardia (mean (SD) heart rate 107 (21) bpm) with marked T wave alternans or ventricular bigeminy. In the last case, the coupling interval of the extrasystole and the post-extrasystolic interval were of similar duration. Thus, the "short-long" sequence of pause dependent arrhythmias was not identifiable. This could be related to our methodology in several ways. First, our definition of "pause" could have been too strict. However, most investigators will argue that our 40 ms cut off value was "too lenient" rather than "too strict". Second, the huge and bizarre TU waves, commonly seen in symptomatic infants, probably made defining the onset of extrasystoles less accurate (fig 4). This could result in imprecise estimation of the intervals preceding the arrhythmias. Alternatively, the absence of pause dependent arrhythmias in infants could reflect a more severe disease. Onset of symptomatic arrhythmias at infancy denotes a rather malignant course.^{9 47 71} Sudden decrements in cycle length—"pauses"—merely facilitate the onset of torsade via two mechanisms: (1) cycle length dependent augmentation of ensuing early afterdepolarisations (which triggers more extrasystoles); and (2) differential prolongation of repolarisation (with greater prolongation in mid/endocardial zones), which worsens the dispersion of repolarisation and facilitates re-entry.^{5 66 72} Indeed, it is possible that patients with more severe forms of the disease (like infants), can develop torsade even without the aid of pauses. In this regard, it is interesting that deafness (indicating homozygote inheritance of a long QT syndrome⁷³ and a more severe disease), also seemed to be more common among patients with torsade not preceded by pauses (21% *v* 7%). The last difference, however, did not reach significance, probably because of the small number of patients with deafness.

LIMITATIONS

A computerised literature search cannot be customised to find arrhythmia illustrations.

This was an "old fashioned" non-automatic search and we probably overlooked more than one report. Also, genotype analysis of the patients with documented arrhythmias is lacking. Since the response of the QT interval to changes in heart rate varies considerably among genotypes,⁷⁴ it is likely that sudden pauses are not equally arrhythmogenic for all genotypes. Finally, case reports tend to include illustrations of arrhythmias more often than large series. Thus, serial studies were under represented in our review. However, since the prevailing view in the literature has been that torsade de pointes in the congenital long QT syndrome is generally not pause dependent,⁵⁻⁸ there is no reason to believe that the authors of the articles reviewed opted for presenting only illustrations of arrhythmias preceded by pauses. Nevertheless, these limitations could have biased our results.

CLINICAL IMPLICATIONS

Some data suggest that cardiac pacing reduces the arrhythmic risk in the long QT syndrome.^{11 12 75} However, arrhythmias may recur despite treatment with β blockers and pacing. Unfortunately, these rare recurrences may be lethal.^{75 76} Our data suggest that sudden pauses, especially post-extrasystolic pauses, play a major role in the genesis of torsade de pointes. Post-extrasystolic pauses are not entirely prevented by cardiac pacing. Whenever an extrasystole occurs, the premature event is sensed by the pacemaker, resetting the escape interval. Although this represents normal pacemaker behaviour, it perpetuates the "short-long" sequence that we ought to interrupt. This is because the coupling interval of the extrasystole (a short cycle) is immediately followed by the escape interval, which is a relatively long cycle determined by the programmed lower rate limit. In contrast, post-extrasystolic pauses may be significantly shortened with specific pause-prevention pacing algorithms. Our clinical experience with the use of one such algorithm for preventing torsade de pointes has been rewarding, but is very limited.^{3 4} The results of the present study support the rationale for further careful evaluation of pause-prevention pacing algorithms to prevent torsade de pointes.

- 1 Viskin S, Belhassen B. Polymorphic ventricular tachyarrhythmias in the absence of organic heart disease. Classification, differential diagnosis and implications for therapy. *Prog Cardiovasc Dis* 1998;41:17-34.
- 2 Viskin S, Alla SR, Barron HV, et al. Mode of onset of torsade de pointes in congenital long QT syndrome. *J Am Coll Cardiol* 1996;28:1262-8.
- 3 Viskin S, Fish R, Roth A, et al. Prevention of torsade de pointes in the congenital long QT syndrome: use of a pause-prevention pacing algorithm. *Heart* 1998;79:417-19.
- 4 Viskin S, Fish R, Brosh D, et al. Prevention of pause-dependent torsade de pointes and malignant ventricular arrhythmias with a pause-preventing pacing algorithm [abstract]. *PACE* 1998;21(II):II-826.
- 5 Antzelevitch C, Sicouri S. Clinical relevance of cardiac arrhythmias generated by afterdepolarizations. Role of M cells in the generation of U waves, triggered activity and torsade de pointes. *J Am Coll Cardiol* 1994;23:259-77.
- 6 Jackman WM, Friday KJ, Anderson JL, et al. The long QT syndromes: a critical review, new clinical observations and a unifying hypothesis. *Prog Cardiovasc Dis* 1988;31:115-72.

- 7 Tan HL, Hou CJ, Lauer MR, et al. Electrophysiologic mechanisms of the long QT interval syndromes and torsade de pointes. *Ann Intern Med* 1995;122:701-14.
- 8 Josephson ME. Recurrent ventricular tachycardia. In: *Clinical cardiac electrophysiology. Techniques and interpretations*, 2nd ed. Pennsylvania: Lea & Febiger, 1993.
- 9 Van-Hare GF, Franz MR, Roge C, et al. Persistent functional atrioventricular block in two patients with prolonged QT intervals: elucidation of the mechanism of block. *PACE* 1990;13:608-18.
- 10 Bhandari AK, Scheinman MM, Morady F, et al. Efficacy of left cardiac sympathectomy in the treatment of patients with the long QT syndrome. *Circulation* 1984;70:1018-23.
- 11 Eldar M, Griffin JC, Abbott JA, et al. Permanent cardiac pacing in patients with the long QT syndrome. *J Am Coll Cardiol* 1987;10:600-7.
- 12 Eldar M, Griffin JC, Van Hare GF, et al. Combined use of beta-adrenergic blocking agents and long-term cardiac pacing for patients with the long QT syndrome. *J Am Coll Cardiol* 1992;20:830-7.
- 13 James TN. Congenital deafness and cardiac arrhythmias. *Am J Cardiol* 1967;19:627-43.
- 14 Van-Bruggen HW, Sebus J, Van-Heyst ANP. Convulsive syncope resulting from arrhythmia in a case of congenital deafness with ECG abnormalities. *Am Heart J* 1969;78:81-6.
- 15 Garza LA, Vick RL, Nora JJ, et al. Heritable Q-T prolongation without deafness. *Circulation* 1970;41:39-48.
- 16 Jervell A. Surdocardiac and related syndromes in children. *Adv Intern Med* 1971;17:425-38.
- 17 Ratshin RA, Hunt D, Russell RO Jr, et al. QT-interval prolongation, paroxysmal ventricular arrhythmias, and convulsive syncope. *Ann Intern Med* 1971;75:919-24.
- 18 Wellens HJ, Vermeulen A, Durrer D. Ventricular fibrillation occurring on arousal from sleep by auditory stimuli. *Circulation* 1972;46:661-5.
- 19 Mathews EC, Blount AW, Townsend JL. Q-T prolongation and ventricular arrhythmias, with and without deafness, in the same family. *Am J Cardiol* 1972;29:702-11.
- 20 Pernot C, Henry M, Aigle J. Syndrome cardio-auditif de Jervell et torsades de pointes. *Arch Mal Coeur* 1972;65:261-74.
- 21 Johansson BW, Jorming B. Hereditary prolongation of QT interval. *Br Heart J* 1972;34:744-51.
- 22 Crawford MH, Karliner JS, O'Rourke RA, et al. Prolonged Q-T interval syndrome. Successful treatment with combined ventricular pacing and propranolol. *Chest* 1975;68:369-71.
- 23 Reynolds E, Vander-Ark CR. Quinidine syncope and the delayed repolarization syndromes. *Modern Concepts in Cardiovascular Disease* 1976;45:117-22.
- 24 Roy PR, Emanuel R, Ismail SA, et al. Hereditary prolongation of the Q-T interval. Genetic observations and management in three families with twelve affected members. *Am J Cardiol* 1976;37:237-43.
- 25 James TN, Froggatt P, Atkinson WJ, et al. De Subitaneis Mortibus. Observations on the pathophysiology of the long QT syndromes with special reference to the neuropathology of the heart. *Circulation* 1978;57:1221-32.
- 26 Curtiss EI, Heibel RH, Shaver JA. Autonomic maneuvers in hereditary Q-T interval prolongation (Romano-Ward syndrome). *Am Heart J* 1978;95:420-8.
- 27 DiSegni E, David D, Katzenstein M, et al. Permanent overdrive pacing for the suppression of recurrent ventricular tachycardia in a newborn with long QT syndrome. *J Electrocardiol* 1980;13:189-92.
- 28 Mitsutake A, Takeshita A, et al. Usefulness of the valsalva maneuver in management of the long QT syndrome. *Circulation* 1981;63:1029-35.
- 29 Hartzler GO, Osborn MJ. Invasive electrophysiological study in the Jervell and Lange-Nielsen syndrome. *Br Heart J* 1981;45:225-9.
- 30 Fontaine G, Frank R, Grosgeogeat Y. Torsades de pointes: definition and management. *Modern Concepts in Cardiovascular Disease* 1982;51:103-8.
- 31 Medina-Ravell V, Castellanos A, Portillo-Acosta B, et al. Management of tachyarrhythmias with dual-chamber pacemakers. *Pacing Clin Electrophysiol* 1983;6:333-45.
- 32 Coumel P, Leclercq JF, Lucet V. Possible mechanisms of the arrhythmias in the long QT syndrome. *Eur Heart J* 1985;6(suppl D):115-29.
- 33 Wilmer CI, Stein B, Morris DC. Atrioventricular pacemaker placement in Romano-Ward syndrome and recurrent torsades de pointes. *Am J Cardiol* 1987;59:171-2.
- 34 Saoudi N, Bozio A, Kirkorian G, et al. Prolonged QT, atrioventricular block, and sudden death in the newborn: an electrophysiologic evaluation. *Eur Heart J* 1991;12:838-41.
- 35 Eggeling T, Hoehner M, Osterhues HH, et al. Significance of noninvasive diagnostic techniques in patients with long QT syndrome. *Am J Cardiol* 1992;70:1421-6.
- 36 Malfatto G, Rosen MR, Foresti A, et al. Idiopathic long QT syndrome exacerbated by beta-adrenergic blockade and responsive to left cardiac sympathetic denervation: implications regarding electrophysiologic substrate and adrenergic modulation. *J Cardiovasc Electrophysiol* 1992;3:295-305.
- 37 Zhou JT, Zheng LR, Liu WY, et al. Early afterdepolarization in the familial long QTU syndrome. *J Cardiovasc Electrophysiol* 1992;3:431-6.
- 38 Habbab MA, El-Sherif N. TU alternans, long QTU and torsade de pointes: clinical and experimental observations. *PACE* 1992;15:916-31.
- 39 Perticone F, Canepa S, Ceravolo R, et al. A case of torsade de pointes occurring in a newborn with persistent 2:1 atrioventricular block. *Cardiology* 1993;83:134-40.
- 40 Leenhardt A, Thomas O, Coumel P. Aspects cliniques et electrocardiographiques des torsades de pointes. In: Chauvin M, ed. *La mort subite d'origine rythmique. Données actuelles*. Paris: Editions Frison-Roche, 1994:79-91.
- 41 Shimizu W, Ohe T, Kurita T, et al. Effects of verapamil and propranolol on early afterdepolarizations and ventricular arrhythmias induced by epinephrine in congenital long QT syndrome. *J Am Coll Cardiol* 1995;26:1299-309.
- 42 Nakajima T, Misu K, Iwasawa K, et al. Auditory stimuli as a major cause of syncope in a patient with idiopathic long QT syndrome. *Jpn Circ J* 1995;59:241-6.
- 43 Wong CW, Wang CH, Wen MS, et al. Effective therapy with transthoracic video-assisted endoscopic coagulation of the left stellate ganglion and upper sympathetic trunk in congenital long QT syndrome. *Am Heart J* 1996;132:1060-3.
- 44 Gronefeld G, Holtgen R, Hohnloser SH. Implantable cardioverter defibrillator therapy in a patient with the idiopathic long QT syndrome. *PACE* 1996;19:1260-3.
- 45 Roden D, Lazzara R, Rosen M, et al. Multiple mechanisms in the long QT syndrome. Current knowledge, gaps, and future directions. *Circulation* 1996;94:1996-2012.
- 46 Benhorin J, Medina A. Congenital long QT syndrome. *N Engl J Med* 1997;336:1568.
- 47 Tanel RE, Triedman JK, Walsh EP, et al. High-rate atrial pacing as an innovative bridging therapy in a neonate with congenital long QT syndrome. *J Cardiovasc Electrophysiol* 1997;8:812-17.
- 48 Moss AJ. The long QT interval syndrome. *Am J Cardiol* 1997;79(6A):17-19.
- 49 Ackerman MJ, Porter CJ. Identification of a family with inherited long QT syndrome after pediatric near-drowning. *Pediatrics* 1998;101:306-8.
- 50 Shimono M, Fujiki A, Inoue H. Relation between autonomic nerve activity and QT interval in patients with congenital long QT syndrome: analysis using 24-hour Holter ECG monitoring. *Annals of Noninvasive Electrocardiology* 1998;3:12-19.
- 51 Zipes DP. *Specific arrhythmias: diagnosis and treatment*, 5th ed. Philadelphia: WB Saunders Co, 1997.
- 52 Pedersen D, Zipes D, Foster P, et al. Ventricular tachycardia and ventricular fibrillation in a young population. *Circulation* 1979;60:988-97.
- 53 Bashour T, Rios JC, Gorman PA. U wave alternans and increased ventricular irritability. *Chest* 1973;64:377-9.
- 54 Flugelman MY, Pollack S, Hammerman H, et al. Congenital prolongation of QT interval: a family study of three generations. *Cardiology* 1982;69:170-4.
- 55 Vlay SC, Mallis GI, Brown EJ, et al. Documented sudden cardiac death in prolonged QT syndrome. *Arch Intern Med* 1984;144:833-5.
- 56 Mache CJ, Beitzke A, Haidvogel M, et al. Perinatal manifestations of the idiopathic long QT syndrome. *Pediatr Cardiol* 1996;17:118-21.
- 57 Kawade M, Ohe T, Kamiya T. Provocative testing and drug response in a patient with the long QT syndrome. *Br Heart J* 1995;74:67-70.
- 58 Garcia-Rubira JC, Garcia-Aranda VL, Cruz-Fernandez JM. Magnesium sulfate for torsade de pointes in a patient with congenital long QT syndrome. *Int J Cardiol* 1990;27:282-3.
- 59 Hsieh MH, Chen SA, Chiang CE, et al. Drug-induced torsade de pointes in one patient with congenital long QT syndrome. *Int J Cardiol* 1996;54:85-8.
- 60 Klein HO, Levi A, Kaplinsky E, et al. Congenital long QT syndrome: deleterious effect of long-term high-rate ventricular pacing and definitive treatment by cardiac transplantation. *Am Heart J* 1996;132:1079-81.
- 61 Chiladakis J, Karapanos G, Manolis SA. Idiopathic long QT syndrome with late onset of bradycardia-dependent and short-coupled variant of torsade de pointes. *Int J Cardiol* 1998;64:93-5.
- 62 Wilde AAM, Jongbloed RJE, Doevendans PA, et al. Auditory stimuli as a trigger for arrhythmic events differentiate HERG-related (LQTS₂) patients from KVLQT1-related patients (LQTS₁). *J Am Coll Cardiol* 1999;33:327-32.
- 63 Tan HL, Alings M, Van-Olden RW, et al. Long-term (subacute) potassium treatment in congenital HERG-related long QT syndrome (LQTS₂). *J Cardiovasc Electrophysiol* 1999;10:229-33.
- 64 El-Sherif N, Turitto G. The long QT syndrome and torsade de pointes. *PACE* 1999;22(1):91-110.
- 65 Locati EH, Maison-Blanche P, Deiode P, et al. Spontaneous sequences of onset of torsade de pointes in patients with acquired prolonged repolarization: quantitative analysis of Holter recordings. *J Am Coll Cardiol* 1995;25:1564-75.
- 66 El-Sherif N, Caref EB, Chinushi M, et al. Mechanism of arrhythmogenicity of the short-long cardiac sequence that precedes ventricular tachyarrhythmias in the long QT syndrome. *J Am Coll Cardiol* 1999;33:1415-23.
- 67 El-Sherif N, Bekheit SS, Henkin R. Quinidine-induced long QTU interval and torsade de pointes: role of bradycardia-dependent early afterdepolarizations. *J Am Coll Cardiol* 1989;14:252-7.
- 68 Viskin S, Lesh MD, Eldar M, et al. Mode of onset of malignant ventricular arrhythmias in idiopathic ventricular fibrillation. *J Cardiovasc Electrophysiol* 1997;8:1115-20.
- 69 Kawasaki R, Machado C, Reinhoel J, et al. Increased propensity of women to develop torsade de pointes during complete heart block. *J Cardiovasc Electrophysiol* 1995;6:1032-8.

- 70 Makkar RR, Fromm BS, Steinman RT, et al. Female gender as a risk factor for torsade de pointes associated with cardiovascular drugs. *JAMA* 1993;270:2590-7.
- 71 Garson A, Dick M, Fournier A, et al. The long QT syndrome in children. An international study of 287 patients. *Circulation* 1993;87:1866-72.
- 72 El-Sherif N, Zeiler RH, Craelius W, et al. QTU prolongation and polymorphic ventricular tachyarrhythmias due to bradycardia dependent early afterdepolarizations. *Circ Res* 1988;63:286-305.
- 73 Splawski I, Timothy K, Vincent GM, et al. Molecular basis of the long QT syndrome associated with deafness. *N Engl J Med* 1997;336:1562-7.
- 74 Schwartz P, Priori S. The long Q-T syndrome. *Annals of Noninvasive Electrocardiology* 1998;3:63-7.
- 75 Moss AJ, Liu JE, Gottlieb S, et al. Efficacy of permanent pacing in the management of high-risk patients with long QT syndrome. *Circulation* 1991;84:1524-9.
- 76 Dorostkar PC, Eldar M, Belhassen B, et al. Long-term follow-up of patients with long-QT syndrome treated with beta-blockers and continuous pacing. *Circulation* 1999;100:2431-6.
- 77 Schwartz PJ, Moss AJ, Vincent GM, et al. Diagnostic criteria for the long QT syndrome. An update. *Circulation* 1993;88:782-4.

IMAGES IN CARDIOLOGY

Ventricular pacing and right bundle branch block morphology: diagnosis and management

A 28 year old woman had atrioventricular (AV) conduction problems since her childhood and developed a complete AV block with junctional rhythm when she was 15 years old. She became progressively symptomatic from her AV conduction block.

A dual chamber pacemaker was implanted and no symptoms were noted during follow up of several years. This young patient was seen at the pacemaker outpatient clinic four years after

the implant. The ECG shows a right bundle branch block pattern, a QRS transition in lead V₅, and a frontal axis at +120°. The posterior-anterior (PA) x ray view shows the ventricular lead located at a higher level than usual and without synchronous movement with the tricuspid valve on PA fluoroscopy.

Transoesophageal echocardiography depicted the lead crossing the interatrial septum in the area of the foramen ovale and passing through the mitral valve, with a large thrombus attached to the lead's extremity.

Considering the age of the patient and the presence of a thrombus with potentially disastrous consequences, atriotomy with removal of the left ventricular lead under extracorporeal circulation was decided. Surgery revealed the lead going through a permeable foramen ovale, with a large thrombus attached on the lead at the atrial level and the tip of the lead entrapped in the cordae of the mitral valve. The lead was removed and the foramen closed. A new ventricular lead was inserted in the right ventricle during the same procedure. No further problems occurred during follow up of 18 months.

DOMINIQUE BLOMMAERT
JOSEPH MUCUMBITSI
LUC DE ROY

