

REVIEWS

Phyllodes tumours

S J Parker, S A Harries

Abstract

Phyllodes tumours are rare fibroepithelial lesions that account for less than 1% of all breast neoplasms. With the non-operative management of fibroadenomas widely adopted, the importance of phyllodes tumours today lies in the need to differentiate them from other benign breast lesions. All breast lumps should be triple assessed and the diagnosis of a phyllodes tumour considered in women, particularly over the age of 35 years, who present with a rapidly growing "benign" breast lump. Treatment can be by either wide excision or mastectomy provided histologically clear specimen margins are ensured. Nodal metastases are rare and routine axillary dissection is not recommended. Few reliable clinical and histological prognostic factors have been identified. Local recurrence occurs in approximately 15% of patients and is more common after incomplete excision. It can usually be controlled by further surgery. Repeated local recurrence has been reported without the development of distant metastases or reduced survival. Approximately 20% of patients with malignant phyllodes tumours develop distant metastases. Long term survival with distant metastases is rare. The role of chemotherapy, radiotherapy, and hormonal manipulation in both the adjuvant and palliative settings remain to be defined.

(*Postgrad Med J* 2001;77:428-435)

Keywords: benign breast disease; fibroadenoma; phyllodes tumour

Department of
Surgery, University
Hospital of Wales,
Cardiff
S J Parker

Department of
General Surgery,
South Warwickshire
General Hospitals
NHS Trust, Lakin
Road, Warwick
CV34 5BW, UK
S A Harries

Correspondence to:
Mr Harries

Submitted 11 July 2000
Accepted 14 November 2000

metastatic spread. In contrast, benign phyllodes tumours on clinical, radiological, and cytological examination are often indistinguishable from fibroadenomas and can be cured by local surgery. With the non-operative management of fibroadenomas widely adopted, the importance of phyllodes tumours today lies in the need to differentiate them from other benign breast lesions.

A Medline search of the English literature published since 1975 was performed using the medical subject heading "phyllodes tumour". Further articles were identified from the reference lists of papers reviewed. In view of the rarity of these tumours, most reported clinicopathological series are small, retrospective in nature, with limited long term follow up. This review collates the results of larger series and discusses the current status of diagnostic investigations, pathological assessment, aetiological and prognostic factors relating to phyllodes tumours. The management of primary, recurrent, and metastatic disease is outlined.

Diagnosis

Triple assessment by clinical, radiological, and cytological or histological examination forms the fundamental basis for the evaluation of all breast lumps. In patients with phyllodes tumours, all three aspects individually have a low sensitivity and, even in combination, the diagnostic accuracy is often poor.⁷⁻¹¹

CLINICAL PRESENTATION

Phyllodes tumours occur over a wide age range. The median age of presentation is 45 years (table 1); 20 years later than that for fibroadenomas.¹² Phyllodes tumours are rare in adolescence¹³⁻¹⁵ and are more prevalent in the Latin American white¹⁶ and Asian populations.¹⁷ Few cases have been reported in men and these have invariably been associated with the presence of gynaecomastia.¹⁸⁻²⁰ With the earlier presentation today of all breast lesions, most tumours are seen at a smaller size than a decade ago.

Phyllodes tumours usually present as a rapidly growing but clinically benign breast lump.^{9 21} In some patients a lesion may have been apparent for several years, with clinical presentation precipitated by a sudden increase in size.^{7 22 23} Malignant tumours are often larger and faster growing, but size and growth rate *per se* are poor predictors of the final histopathological type.^{8 10 21-25} They are found more commonly in the upper outer quadrant with an equal propensity to occur in either breast.^{7 8}

Phyllodes tumours are rare fibroepithelial lesions that account for less than 1% of all breast neoplasms.¹⁻³ First described by Johannes Müller in 1838,⁴ he coined the term *cystosarcoma phyllodes*; a misleading description as the tumours are rarely cystic and the majority follow a benign clinical course. In total, more than 60 synonyms have been reported⁵ but today, the World Health Organisation regards phyllodes tumour as the most appropriate nomenclature.⁶ Displaying a broad range of clinical and pathological behaviour, phyllodes tumours should be regarded as a spectrum of fibroepithelial neoplasms rather than a single disease entity. At one extreme, malignant phyllodes tumours, if inadequately treated, have a propensity for rapid growth and

The skin over large tumours may have dilated veins and a blue discoloration but nipple retraction is rare. Fixation to the skin or the pectoralis muscles has been reported, but ulceration is uncommon, even in patients with histologically malignant tumours.⁷ Pressure necrosis of the overlying skin can occur.²³ Palpable axillary lymphadenopathy can be identified in up to 20% of patients but nodal metastases are uncommon.^{22 26 27} A significant proportion of patients have previously had a fibroadenoma and in a minority these have been multiple.^{7 18 28 29} Occasionally fibroadenomas present simultaneously with a phyllodes tumour^{30 31} and synchronous bilateral phyllodes tumours have been reported.^{32 33} The diagnosis of a phyllodes tumour should be considered in all women, particularly over the age of 35 years, who present with a rapidly growing but clinically benign breast lump.

RADIOLOGICAL IMAGING

As with fibroadenomas, phyllodes tumours are mammographically well defined with a smooth and occasionally lobulated border. A radiolucent "halo" may be seen around the lesion, due to compression of the surrounding breast stroma.^{34 35} Coarse microcalcification has been reported within both fibroadenomas and phyllodes tumours^{9 36-39} but "malignant" microcalcification is rare.^{35 38 40} No mammographic indicators have been identified that allow differentiation between benign and malignant tumours.^{34 39 40} On ultrasound examination, phyllodes tumours often show smooth contours with low level homogenous internal echoes, intramural cysts, and the absence of posterior acoustic enhancement.^{9 34 41} As with mammography, no reliable ultrasonic indicators have been identified that differentiate between benign and malignant lesions.^{34 36} The role of magnetic resonance imaging in the assessment of phyllodes tumours and fibroadenomas remains to be defined.⁴²

PATHOLOGICAL ASSESSMENT

As both phyllodes tumours and fibroadenomas belong to a spectrum of fibroepithelial lesions, accurate cytological diagnosis of phyllodes

Box 1: Diagnosis

- Phyllodes tumours account for less than 1% of breast neoplasms.
- Median age of presentation is 45 years; 20 years later than that for fibroadenomas.
- Diagnosis should be considered in all rapidly growing benign breast lesions.
- No radiological indicators exist to differentiate benign and malignant lesions.
- Fine needle aspiration cytology specimens require both epithelial and stromal elements to confirm the diagnosis.

tumours by fine needle aspiration can be difficult.^{43 44} Cytologically, it is often easier to differentiate benign from malignant phyllodes tumours than to separate benign phyllodes tumours from fibroadenomas.⁴⁵ The presence of cohesive stromal cells (phyllodes fragments), isolated mesenchymal cells, clusters of hyperplastic duct cells, foreign body giant cells, bipolar naked nuclei, and the absence of apocrine metaplasia are highly suggestive of a phyllodes tumour.^{46 47} In the correct clinical setting, the presence of both epithelial and stromal elements within the cytological smear supports the diagnosis.⁴⁸ Epithelial cells may, however, be absent from specimens taken from malignant lesions.⁴⁶ The reporting of C3 (possibly benign) or C4 (possibly malignant) cytology from what appears to be a fibroadenoma should raise clinical suspicion of a phyllodes tumour.⁸ With the increased use of core biopsies, preoperative diagnostic accuracy should improve and confusion with breast carcinomas should rarely occur.^{44 47}

Pathology

Phyllodes tumours vary greatly in size with most series reporting lesions up to 20 cm in diameter (table 1). Macroscopically, most small tumours have a uniform white consistency with a lobulated surface, similar to that of a fibroadenoma. They are rarely cystic in nature.¹⁸ Large tumours often have a red or grey "meaty" consistency with fibrogelatinous, haemorrhagic, and necrotic areas.¹ The term

Table 1 Patient age, tumour diameter, and histological types reported from all studies of phyllodes tumours with greater than 20 patients published since 1975

Study	City	No	Duration	Age (years; range)	Diameter (cm; range)	No (%) of histological type		
						Benign	Borderline	Malignant
Bennett <i>et al</i> ⁶⁰	Brisbane	30	1970-88	49 (20-75)	3.5 (1-30)	14 (47)	5 (17)	11 (37)
Chua <i>et al</i> ¹	Singapore	106	1978-86	30 (13-61)	NA	97 (92)	6 (6)	3 (2)
Ciatto <i>et al</i> ¹⁰	Florence	59	1977-91	NA	NA	22 (37)	12 (20)	25 (42)
Cohn-Cedermark <i>et al</i> ⁹	Stockholm	77	1958-86	50 (18-85)	NA	42 (55)	NC	35 (45)
Contarini <i>et al</i> ³⁸	Jacksonville	40	1963-80	41 (12-85)	6.1 (1-20)	23 (58)	NC	17 (42)
de Roos <i>et al</i> ¹⁰	Cape Town	38	1975-96	44 (17-65)	8.0 (2-30)	15 (39)	11 (29)	12 (32)
Hines <i>et al</i> ¹³	Chicago	25	1959-81	50 (16-82)	7.2 (2-15)	15 (60)	NC	10 (40)
Holthouse <i>et al</i> ⁶⁸	Perth	26	1983-94	46 (21-82)	NA	19 (73)	4 (15)	3 (12)
Iau <i>et al</i> ¹¹	Singapore	40	1985-95	38 (15-58)	5.2 (1-22)	33 (83)	2 (5)	5 (12)
Mangi <i>et al</i> ²⁸	Boston	40	1980-97	41 (17-74)	NA (5-28)	34 (84)	3 (8)	3 (8)
Moffat <i>et al</i> ²⁵	Nottingham	32	1975-90	52 (23-93)	5.9 (1-19)	23 (71)	4 (13)	5 (16)
Mokbel <i>et al</i> ⁶⁸	London	30	1978-98	49 (19-80)	4.6 (2-10)	21 (70)	2 (7)	7 (23)
Pietruszka and Barnes ⁵⁶	Pittsburgh	42	1945-77	44 (14-67)	5.0 (1-41)	18 (43)	5 (12)	19 (45)
Reinfuss <i>et al</i> ²²	Krakow	170	1952-88	52 (19-76)	7.0 (2-40)	92 (54)	19 (11)	59 (34)
Salvadori <i>et al</i> ²⁴	Milan	81	1974-83	44 (9-88)	NA	28 (34)	32 (40)	21 (26)
Stebbing and Nash ⁸	London	33	1981-92	41 (15-67)	3.7 (1-18)	24 (73)	6 (18)	3 (9)
Zurrida <i>et al</i> ³	Milan	216	1970-89	NA	NA	140 (64)	46 (21)	30 (14)

NA = data not published; NC = no borderline category.

Series that specifically studied only adolescent patients, benign or malignant tumours have been excluded.

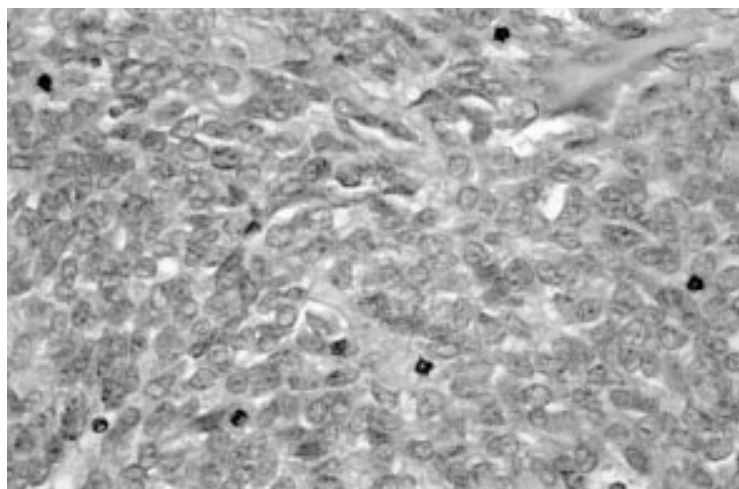


Figure 1 Malignant phyllodes tumour. Stroma shows cellular pleomorphism, nuclear atypia, and high mitotic activity (haematoxylin and eosin $\times 200$).

cystosarcoma phyllodes was applied by Müller as *phyllode* described the leaf-like projection of the stroma into cystic spaces while *sarcoma* referred to the “fleshy” consistency of the tumour.⁴

Microscopically, phyllodes tumours are characterised by epithelial lined cystic spaces into which projects a hypercellular stroma (fig 1). The presence of both epithelial and stromal elements are necessary to confirm the diagnosis. The stroma is the neoplastic component and determines the pathological behaviour.⁴⁹ Only the stromal cells have the potential to metastasise.⁵⁰ Primary tumours of the breast with pure sarcomatous differentiation and the absence of epithelial elements should be regarded as soft tissue sarcomas.^{51 52} Fibroadenomas are pathologically distinct from phyllodes tumours. They have a hypocellular stroma with few mitoses and little evidence of pleomorphism (fig 2). Unlike phyllodes tumours, fibroadenomas have a true capsule.

A wide range of histological features are seen within phyllodes tumours with heterogeneity existing between abutting areas within the same lesion. Based on the histological characteristics of the tumour, including its margin

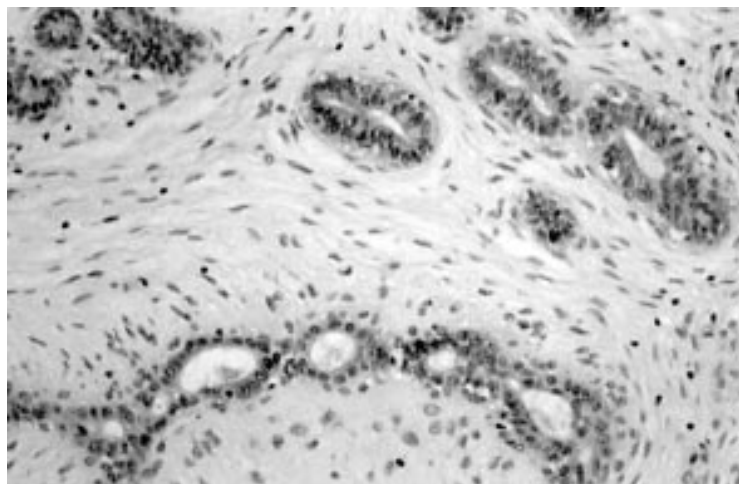


Figure 2 Fibroadenoma. Stroma shows no cellular pleomorphism, nuclear atypia, or mitotic activity (haematoxylin and eosin $\times 200$).

Table 2 Criteria used to classify histological type as proposed by Azzopardi⁵³ and Salvadori *et al*⁵⁴

Criteria	Histological type		
	Benign	Borderline	Malignant
Tumour margins	Pushing	\leftrightarrow	Infiltrative
Stroma cellularity	Low	Moderate	High
Mitotic rate (per 10 hpf)	<5	5–9	>10
Pleomorphism	Mild	Moderate	Severe

hpf = high powered field.

(pushing or infiltrating), stromal cellularity (slight or severe), stromal overgrowth (absent, slight, or severe), tumour necrosis (present or absent), cellular atypia (absent, slight, or severe), and the number of mitoses per high power field, they can be classified into “benign”, “borderline”, and “malignant” categories. The widely accepted definitions as proposed by Azzopardi⁵³ and Salvadori *et al*⁵⁴ are shown in table 2. Other pathological classifications have defined similar categories but based on slightly different histopathological features.^{55 56} Some have regarded the designation of borderline lesions as unnecessary.⁵⁷

Tumour heterogeneity, sampling errors, and the lack of a standard interpretation of histological features are important factors in determining the relative proportions of benign, borderline, and malignant tumours seen in different series. The percentage of malignant lesions reported ranges from 2% to 45% (table 3). Furthermore, studies in which different pathologists have reported on the same histological slides have shown up to a 25% discordance in the final histopathological typing.^{58 59}

Aetiology

The aetiological relationship between fibroadenomas and phyllodes tumours is at present unclear. Many patients develop both lesions either synchronously or metachronously and histological features of both fibroadenomas and phyllodes tumours have been identified in some tumours.⁵⁵ Whether phyllodes tumours develop from fibroadenomas or arise *de novo* remains to be defined. Noguchi *et al* showed that most fibroadenomas have polyclonal elements and should be regarded as hyperplastic rather than neoplastic lesions.⁶⁰ It has been suggested that, in a proportion of fibroadenomas, a somatic mutation can result in a monoclonal proliferation, histologically indistinguishable from the polyclonal element, but with a propensity to local recurrence and progression to a phyllodes tumour. Clonal analysis performed on histological specimens from patients who sequentially developed fibroadenomas and phyllodes tumours at the same site showed that both lesions were monoclonal and expressed the same inactivated allele, appearing to support this hypothesis.⁶¹

It has also been postulated that stromal induction of phyllodes tumours can occur as a result of growth factors produced by the breast epithelium.⁶² The nature of these factors is unclear but endothelin-1, a stimulator of breast fibroblast growth, may be important. Increased endothelin-1 levels have been demonstrated

Box 2: Pathology

- Tumours can grow to over 20 cm in diameter.
- Macroscopically small tumours usually resemble fibroadenomas.
- Large tumours often have a red “meaty” appearance with cystic and necrotic areas.
- Microscopy shows epithelial lined cystic spaces with hypercellular stroma.
- On histological appearance tumours are classified as benign, borderline, or malignant.
- Axillary lymph node metastases occur in approximately 10% of patients.

within phyllodes tumours.⁶³ Endothelin-1 immunoreactive cells has been demonstrated in both the stroma of normal breast tissue⁶⁴ and the epithelium of phyllodes tumours⁶⁵ suggesting a possible paracrine mechanism for stromal stimulation.

Prognostic factors

Most malignant phyllodes tumours do not recur or metastasise while some histologically benign tumours can show an usually aggressive clinical course.^{18 52 65} Consequently, it has been suggested that all phyllodes tumours should be regarded with malignant potential.^{58 66} Radical surgery for all phyllodes tumours is unnecessary and attempts have been made to identify clinical and histopathological prognostic factors. Little consensus exists regarding their relative importance and different factors appear to be important in predicting for local recurrence and metastatic spread. The local recurrence and distant metastatic rates of large published series are shown in table 3.

No reliable clinical prognostic factors have been identified that predict for local recurrence. Patient age does not appear to be important^{10 27 56 67} but tumours presenting in adolescence do seem to be less aggressive irrespective of their histological type.^{13 14 30} The role of tumour size is unclear. While most series have reported low local recurrence rates with tumours less than 2 cm in diameter,^{10 21 68} no correlation between tumour size and the

risk of local recurrence has been demonstrated.^{8 10 22 30 56 69 70} The size of the tumour in relation to the breast appears important as this usually determines the extent of surgery and the resulting specimen resection margins. The risk of local recurrence is increased in incompletely excised lesions.^{30 25 70 71} Conversely, low recurrence rates have been reported in patients in which histologically clear margins have been assured.^{21 22} Whether the risk of local recurrence is increased in histologically malignant phyllodes tumours is unclear.^{8 10 70 72-74}

Most distant metastases develop from borderline or malignant tumours.⁷⁵ Unlike for local recurrence, tumour size does appear to be an important factor in predicting for metastatic spread.^{56 67 70} Many histological prognostic factors have been evaluated. Different studies have regarded stromal overgrowth,^{67 76-78} tumour necrosis,⁷⁹ infiltrating margins,^{30 56 67 80} mixed mesenchymal components,⁷³ high mitotic rate,^{30 56 67 79} and stromal atypia^{56 74} as important but in isolation each appears to have a low predictive value. Reinfuss *et al*, by univariate analysis, identified stromal overgrowth, margin and histological type as key prognostic factors.²² When entered in a multivariate analysis only histological type remained an independent prognostic factor. Similarly, Cohn-Cedermark *et al* in a univariate analysis identified mitotic activity, stromal overgrowth, cellular atypia, tumour necrosis and stromal elements other than fibromyxoid tissue as significant prognostic factors,⁷⁹ but in a multivariate analysis only the presence of necrosis and the type of stromal elements remained significant.

As studies of histological prognostic factors have been disappointing, recent interest has been shown in markers of tumour biology. Mutations of the p53 tumour suppressor gene have been identified in human malignancies and are believed to be important in neoplastic progression and malignant potential. Increased p53 stromal immunoreactivity has been detected in malignant phyllodes tumours and p53 immunoreactivity may be valuable in differentiating fibroadenomas from phyllodes tumours.^{81 82} Furthermore, in phyllodes tumours,

Table 3 Operative treatment, local and distant recurrence rates from all studies of phyllodes tumours with greater than 20 patients published since 1975

Study	No	Operation: benign		Operation: border		Operation: malignant		Follow up (years; range)	Recurrence	
		LE	Mastectomy	LE	Mastectomy	LE	Mastectomy		Local	Distant
Bennett <i>et al</i> ⁶⁰	30	12	2	2	3	3	8	72 (3–216)	4 (13)	1 (3)
Chua <i>et al</i> ⁷	106	93	4	5	1	Nil	3	42 (NA)	18 (17)	1 (<1)
Ciatto <i>et al</i> ¹⁰	59	16	6	7	5	1	11	45 (1–160)	17 (29)	3 (5)
Cohn-Cedermark <i>et al</i> ⁹	77	NA	NA	NA	NA	NA	NA	NA	15 (19)	16 (21)
Contarini <i>et al</i> ⁵⁸	40	19	4	NC	NC	6	11	46 (7–168)	3 (8)	4 (10)
de Roos <i>et al</i> ¹⁰	38	12	3	5	6	4	8	NA	9 (23)	4 (11)
Hines <i>et al</i> ¹³	25	11	4	NA	NA	2	8	NA (36–180)	10 (40)	4 (16)
Holthouse <i>et al</i> ⁶⁸	26	19	Nil	3	1	3	Nil	81 (27–146)	4 (15)	Nil
Iau <i>et al</i> ¹¹	40	32	1	2	Nil	4	1	23 (2–82)	4 (10)	2 (5)
Mangi <i>et al</i> ²⁸	40	27	7	2	1	2	1	133 (60–312)	5 (13)	1 (3)
Moffat <i>et al</i> ²⁵	32	16	7	1	3	1	4	135 (36–221)	7 (22)	Nil
Mokbel <i>et al</i> ⁶⁶	30	21	Nil	2	Nil	7	Nil	72 (6–240)	5 (17)	1 (3)
Pietruszka and Barnes ⁵⁶	42	11	7	2	3	3	16	98 (1–281)	6 (14)	4 (10)
Reinfuss <i>et al</i> ²²	170	79	13	15	4	4	26	96 (60–NA)	14 (9)	27 (17)
Salvadori <i>et al</i> ²⁴	81	25	3	28	4	8	13	91 (31–164)	14 (17)	2 (2)
Stebbing and Nash ⁸	33	23	1	4	2	Nil	3	50 (4–194)	4 (12)	1 (3)
Zurrida <i>et al</i> ³	216	136	4	41	5	19	11	116 (24–326)	27 (13)	Nil

LE = local or wide local excision; mastectomy = simple or radical mastectomy; NA = data not published. Series that specifically studied only adolescent patients, benign or malignant tumours have been excluded.

Box 3: Prognosis

- Most malignant tumours do not metastasise.
- Some benign tumours may show an unusually aggressive behaviour.
- Incomplete excision increases the risk of local recurrence.
- Histological type is the most important predictor for metastatic spread.
- The five year survival for benign, borderline, or malignant tumours is 96%, 74%, and 66% respectively.

Box 4: Management

- All rapidly growing benign breast lesions require histological assessment.
- Wide excision or mastectomy should be performed ensuring histological clear margins.
- Mastectomy for malignant tumours offers no survival advantage.
- Axillary nodal dissection is not required.
- The role of adjuvant radiotherapy is unclear.

p53 immunoreactivity has been shown to correlate with negative prognostic factors but alone fails to predict for local recurrence or survival.⁸³ In flow cytometric studies, correlations between DNA content, cell proliferation, and histological grade have been demonstrated.⁸⁴⁻⁸⁶ Some studies have identified a correlation between these markers of cellular proliferation and clinical outcome,⁸⁷ however, most have not.^{84-86 88} Recent small studies have suggested that telomerase, a ribonucleoprotein enzyme that generates telomeres (DNA sequences important in determining cell immortality) may be a useful prognostic factor in phyllodes tumours.^{89 90}

Five year disease-free survival rates of 96%, 74%, and 66% have been reported after surgery for benign, borderline, and malignant phyllodes tumours, respectively.²² Using pooled cancer registry data, Vorherr *et al* estimated an overall five year survival rate of 80% for malignant phyllodes tumours.²⁷

Management

The natural history of fibroadenomas has recently been clearly defined. With the negligible increased risk of malignancy and the recognition that 40% of fibroadenomas reduce in size over a two year period, non-operative management has been widely adopted.⁹¹ With the low prevalence of phyllodes tumours among all benign breast lumps, routine excision of all benign breast lumps cannot be advocated. However, treatment protocols need to be adopted that allow the timely identification of phyllodes tumours. As most phyllodes tumours grow faster than fibroadenomas, histological assessment and possible excision of a benign breast lump should be considered if rapid growth is seen during a period of observation.

Until the late 1970s, mastectomy was the standard surgical treatment for all phyllodes tumours, irrespective of tumour size or histological type.^{1 23 26} Radical surgery offered no survival advantage⁷⁹ and today more conservative surgical approaches have been adopted. Directly comparing the outcome of local surgery and mastectomy is difficult as mastectomy has invariably been performed for larger tumours.^{8 10} Some generalisations regarding the management of these tumours can however be made. Simple intracapsular enucleation or “shelling out” of phyllodes tumours, irrespective of the histological type, results in an unacceptably high rate of local recurrence.^{58 92} If

diagnosed preoperatively, wide excision with a margin of at least 1 cm of normal breast tissue is required, particularly for borderline and malignant tumours.²⁸ For benign phyllodes tumours diagnosed after local excision of what appeared to be a fibroadenoma, a “watch and wait” policy does appear to be safe.⁹³ With such an approach, local recurrence and five year survival rates of 4% and 96% respectively have been reported for benign phyllodes tumours.²² Whether patients with benign phyllodes tumours who have undergone local excision and have histologically positive specimen margins should undergo further surgery^{7 70} or be entered in a surveillance programme²¹ is controversial. Re-excision of borderline and malignant phyllodes tumours identified after local excision should be considered. It has been suggested that mastectomy is no longer required, even for malignant phyllodes tumours, provided adequate resection margins can be achieved.^{58 59} With the “benign” course of the disease in adolescents, irrespective of the histological type of the tumour, the breast can invariably be preserved.^{7 14 94}

As malignant phyllodes tumours undergo haematogenous spread, the proportion of patients with lymph node metastases is approximately 10% and routine axillary clearance is not recommended.^{10 18 22 72 76} The role of adjuvant breast radiotherapy is unclear and has not been the subject of large randomised controlled trials.^{29 79 95} In those few unselected cases in which it has been used, the dose of radiotherapy given has been higher than that used in the adjuvant setting for patients with breast cancer.

Recurrent disease

The potential for phyllodes tumours to recur and metastasise was first recognised in the 1930s.^{96 97} To date, local recurrence rates ranging from 10% to 40% have been reported with most series averaging 15% (table 3). Local recurrence appears to be related to the extent of the initial surgery and should be regarded as a failure of primary surgical treatment.^{10 56 76 77 79 92} Whether malignant tumours have an increased risk of recurrence is unclear but when it does occur it is invariably seen earlier than with benign tumours.^{74 92 98} Local recurrence usually occurs within the first few years of surgery and histologically resembles the original tumour.^{8 10 25 56 92 99} Occasionally recurrent tumours shows increased cellularity and more aggressive histological features than

Box 5: Recurrent and metastatic disease

- 15% of patients develop local recurrence.
- Local recurrence is not associated with distant metastases or reduced survival.
- Local recurrence can often be controlled with further surgery.
- 20% of patients with malignant tumours develop distant metastases.
- The commonest sites are lung, bone, and abdominal viscera.
- Good palliation can be obtained with single agent or combination chemotherapy.
- The role of hormonal therapy remains to be defined.

the original lesion.^{25 52 67 92} In most patients, local recurrence is isolated and is not associated with the development of distant metastases.^{79 99} In a minority of patients repeated local recurrence occurs, over a prolonged period with no survival disadvantage.^{56 92 98 100 101} This is often seen irrespective of either the histological type of the tumour or the extent of the specimen margins.

Local recurrence can usually be controlled by further wide excision⁷ and mastectomy is not invariably required.^{56 99} Mastectomy should, however, be considered for local recurrence after local surgery for borderline or malignant tumours.^{17 22 82} Occasionally aggressive local recurrence can result in widespread chest wall disease with direct invasion of the underlying lung parenchyma.⁵⁶ Isolated reports of good palliation in this situation with radiotherapy have been published.^{29 102}

Metastatic disease

Overall, 10% of patients with phyllodes tumours develop distant metastases (table 3) and these eventually occur in approximately 20% of patients with histologically malignant tumours.²⁵ Most distant metastases develop without evidence of local recurrence.⁹⁹ The commonest sites for distant metastases are the lung, bone, and abdominal viscera.^{22 55 103 104} These often occur in the absence of lymph node metastases^{24 103} and histologically contain only the stromal element.¹⁰⁵ The risk of metastatic disease does not appear to be influenced by the extent of the initial surgery^{56 75 92 104} and appears to be predetermined by tumour biology. Few reports have been published of distant metastases after excision of a benign phyllodes tumour, except when histologically malignant local recurrence occurs.^{24 29 52 92}

Metastatic phyllodes tumours have a poor prognosis and no long term survival has been reported.^{103 105} Isolated reports have been published of good palliation of metastatic disease from single agent^{22 106} or combination chemotherapy¹⁰⁷⁻¹⁰⁹ but the exact role of chemotherapy in metastatic phyllodes tumours remains to be defined. Up to 40% of phyllodes tumours are oestrogen receptor positive¹¹⁰ and as with fibroadenomas, almost all phyllodes tumours express progesterone

receptors.¹¹¹ Despite these features, the use of endocrine therapy in either the adjuvant or palliative setting has not been extensively studied.

The authors would like to thank Dr Mark Newbold, Consultant Pathologist, Walsgrave Hospitals NHS trust for the photomicrographs in figures 1 and 2.

- 1 Dyer NH, Bridger JE, Taylor RS. Cystosarcoma phyllodes. *Br J Surg* 1966;53:450-5.
- 2 Popescu I, Serbanescu M, Ivaschescu C. Phyllodes tumours of the breast. *Zentralbl Chir* 1991;116:327-36.
- 3 Buchanan ED. Cystosarcoma phyllodes and its surgical management. *Am Surg* 1995;61:350-5.
- 4 Müller J. *Über den feineren Bau und Die Formen der Krankhaften Geschwulste*. Berlin: G Reiner, 1838;1:54-7.
- 5 Fiks A. Cystosarcoma phyllodes of the mammary gland—Muller's tumor. *Virchows Arch* 1982;392:1-6.
- 6 World Health Organisation. Histological typing of breast tumors. *Tumori* 1982;68:181-98.
- 7 Chua CL, Thomas A, Ng BK. Cystosarcoma phyllodes: a review of surgical options. *Surgery* 1989;105:141-7.
- 8 Stebbing JF, Nash AG. Diagnosis and management of phyllodes tumour of the breast: experience of 33 cases at a specialist centre. *Ann R Coll Surg Engl* 1995;77:181-4.
- 9 Umpleby HC, Guyer PB, Moore I, et al. An evaluation of the preoperative diagnosis and management of cystosarcoma phyllodes. *Ann R Coll Surg Engl* 1989;71:285-8.
- 10 Ciatto S, Bonardi R, Cataliotti L, et al. Phyllodes tumor of the breast: a multicenter series of 59 cases. *Eur J Surg Oncol* 1992;18:545-9.
- 11 Iau PTC, Lim TC, Png DJC, et al. Phyllodes tumour: an update of 40 cases. *Ann Acad Med Singapore* 1998;27:200-3.
- 12 Oberman HA. Cystosarcoma phyllodes. A clinicopathologic study of hypercellular periductal stromal neoplasms of the breast. *Cancer* 1965;18:697-710.
- 13 Amerson JR. Cystosarcoma in adolescent females. *Am Surg* 1970;171:849-58.
- 14 Adachi Y, Matsushima T, Kido A, et al. Phyllodes tumor in adolescents. Report of two cases and review of the literature. *Breast Dis* 1993;6:285-93.
- 15 Nambiar R, Kutty MK. Giant fibro-adenoma (cystosarcoma phyllodes) in adolescent females: a clinicopathological study. *Br J Surg* 1974;61:113-17.
- 16 Bernstein L, Deapen D, Ross RK. The descriptive epidemiology of malignant cystosarcoma phyllodes tumors of the breast. *Cancer* 1993;71:3020-4.
- 17 Chua CL. Cystosarcoma phyllodes: Asian variations. *Aust N Z J Surg* 1988;58:301-5.
- 18 West TL, Weiland LH, Clagett OT. Cystosarcoma phyllodes. *Ann Intern Med* 1971;173:520-8.
- 19 Pantoja E, Llobet RE, Lopez E. Gigantic cystosarcoma phyllodes in a man with gynecomastia. *Arch Surg* 1976;111:611.
- 20 Reingold IM, Ascher GS. Cystosarcoma phyllodes in a man with gynecomastia. *Am J Clin Pathol* 1970;53:582-6.
- 21 Bartoli C, Zurrada S, Veronesi P, et al. Small sized phyllodes tumor of the breast. *Eur J Surg Oncol* 1990;16:215-19.
- 22 Reinfuss M, Mitus J, Duda K, et al. The treatment and prognosis of patients with phyllodes tumor of the breast. *Cancer* 1996;77:910-16.
- 23 Maier WP, Rosemond GP, Wittenberg P, et al. Cystosarcoma phyllodes mammae. *Oncology* 1968;22:145-58.
- 24 Zissis C, Apostolikas N, Konstantinidou A, et al. The extent of surgery and prognosis of patients with phyllodes tumor of the breast. *Breast Cancer Res Treat* 1998;48:205-10.
- 25 Moffat CJC, Pinder SE, Dixon AR, et al. Phyllodes tumour of the breast: a clinicopathological review of the thirty-two cases. *Histopathology* 1995;27:205-18.
- 26 Norris HJ, Taylor HR. Relationship of histological features to behaviour of cystosarcoma phyllodes. *Cancer* 1967;20:2090-9.
- 27 Vorherr H, Vorherr UF, Kutvirt DM, et al. Cystosarcoma phyllodes: epidemiology, pathohistology, pathobiology, diagnosis, therapy and survival. *Arch Gynecol* 1985;236:173-81.
- 28 Mangi AA, Smith BL, Gadd MA, et al. Surgical management of phyllodes tumors. *Arch Surg* 1999;134:487-92.
- 29 Hopkins ML, McGowan TS, Rawlings G. Phylloides tumor of the breast: a report of 14 cases. *J Surg Oncol* 1994;56:108-12.
- 30 Rajan PB, Cranor ML, Rosen PP. Cystosarcoma phyllodes in adolescent girls and young women. *Am J Clin Pathol* 1998;22:64-9.
- 31 Modena S, Prati G, Mainente M, et al. Phyllodes tumor of the breast: problems of differential diagnosis and therapeutic approach from an analysis of 17 cases. *Eur J Surg Oncol* 1993;19:70-3.
- 32 McDonald J, Harrington SW. Giant fibroadenoma of the breast; cystosarcoma phyllodes. *Am Surg* 1950;131:243-51.
- 33 Bader L, Isaacson C. Bilateral malignant cystosarcoma phyllodes. *Br J Surg* 1961;48:519-21.
- 34 Buchberger W, Strasser K, Helm K, et al. Phylloides tumor: findings on mammography, sonography and aspiration cytology in 10 cases. *Am J Roentol* 1991;157:715-19.

- 35 Page JE, Williams JE. The radiological features of phylloides tumour of the breast with clinico-pathological correlation. *Clin Radiol* 1991;44:8-12.
- 36 Blanco AJ, Serrano BV, Romero RR, et al. Phylloides tumors of the breast. *Eur Radiol* 1999;9:356-60.
- 37 Paulus DD. Benign diseases of the breast. *Radiol Clin North Am* 1983;21:27-50.
- 38 Liberman L, Bonaccio E, Hamele-Bena D, et al. Benign and malignant phylloides tumor: mammographic and sonographic findings. *Radiology* 1996;198:121-4.
- 39 Lyons K, Gravelle IH, Jones AD. The radiology of phylloides tumour. *Br J Clin Pract* 1989;43(suppl 68):147-9.
- 40 Cosmacini P, Zurrida S, Veronesi P, et al. Phylloide tumor of the breast: mammographic experience in 99 cases. *Eur J Radiol* 1992;15:11-14.
- 41 Cole-Beuglet C, Soriano R, Kurtz AB, et al. Ultrasound, X-ray mammography and histopathology of cystosarcoma phylloides. *Radiology* 1983;146:121-4.
- 42 Farria DM, Gorczyca DP, Barsky SH, et al. Benign phylloides tumor of the breast: MR imaging features. *Am J Roentgenol* 1996;167:187-9.
- 43 Shimizu K, Masawa N, Yamada T, et al. Cytologic evaluation of phylloides tumors as compared to fibroadenomas of the breast. *Acta Cytol* 1994;38:891-7.
- 44 Dusenbury D, Frable WJ. Fine needle aspiration cytology of phylloides tumor: potential diagnostic pitfalls. *Acta Cytol* 1992;36:215-21.
- 45 Deen SA, McKee GT, Kissin MW. Differential cytologic features of fibroepithelial lesions of the breast. *Diagn Cytopathol* 1999;20:53-6.
- 46 Rao CR, Narasimhamurthy NK, Jaganathan K, et al. Cystosarcoma phylloides: diagnosis by fine needle aspiration cytology. *Acta Cytol* 1992;36:203-7.
- 47 Simi U, Moretti D, Iacconi P, et al. Fine needle aspiration cytopathology of phylloides tumor. *Acta Cytol* 1988;32:63-6.
- 48 Shabb NS. Phylloides tumor. Fine needle aspiration cytology of eight cases. *Acta Cytol* 1997;41:321-6.
- 49 Aranda FI, Laforga JB, Lopez JL. Phylloides tumor of the breast. An immunohistochemical study of 28 cases with special attention to the role of myofibroblast. *Pathol Res Pract* 1994;190:474-81.
- 50 Fernandez BB, Hernandez FJ, Spindler W. Metastatic cystosarcoma phylloides, a light and electron microscopic study. *Cancer* 1976;37:1737-46.
- 51 Moore MP, Kinne DW. Breast sarcoma. *Surg Clin North Am* 1996;76:383-92.
- 52 Blichert-Toft M, Hansen JPH, Hansen OH, et al. Clinical course of cystosarcoma phylloides related to histologic appearance. *Surg Gynecol Obstet* 1975;140:929-32.
- 53 Azzopardi JG. Sarcoma in the breast. In: Bennington J, ed. *Problems in breast pathology. Vol. II.* Philadelphia: WB Saunders, 1979: 355-9.
- 54 Salvadori B, Cusumano F, Del-Ro R, et al. Surgical treatment of phylloides tumors of the breast. *Cancer* 1989;63:2532-6.
- 55 Treves N, Sutherland DJ. Cystosarcoma phylloides of the breast: a clinicopathological study of 77 cases. *Cancer* 1951;4:1286-332.
- 56 Pietruszka M, Barnes L. Cystosarcoma phylloides. A clinicopathological analysis of 42 cases. *Cancer* 1978;41:1974-83.
- 57 McDivitt RW, Urban JA, Farrow JH. Cystosarcoma phylloides. *Johns Hopkins Med J* 1987;120:33-45.
- 58 Contarini O, Urdaneta LF, Wayne H, et al. Cystosarcoma phylloides of the breast: a new therapeutic proposal. *Am Surg* 1982;48:157-66.
- 59 Hart J, Layfield LJ, Trumbull WE, et al. Practical aspects in the diagnosis and management of cystosarcoma phylloides. *Arch Surg* 1988;123:1079-83.
- 60 Noguchi S, Motomura K, Inaji H, et al. Clonal analysis of fibroadenoma and phylloides tumor of the breast by means of polymerase chain reaction. *Cancer Res* 1993;53:4071-4.
- 61 Noguchi S, Yokouchi H, Aihara T, et al. Progression of fibroadenoma to phylloides tumour demonstrated by clonal analysis. *Cancer* 1995;76:1779-85.
- 62 Sawhney N, Garrahan N, Douglas-Jones AG, et al. Epithelial-stromal interactions in tumors. A morphologic study of fibroepithelial tumours of the breast. *Cancer* 1992;70:2115-20.
- 63 Yamashita J, Ogawa M, Egami H. Abundant expression of immunoreactive endothelin-1 in mammary phylloides tumour—possible paracrine role of endothelin-1 in the growth of stromal cells in phylloides tumour. *Cancer Res* 1992;52:4046-9.
- 64 Baley PA, Resink TJ, Eppenberger U, et al. Endothelin messenger RNA and receptors are differentially expressed in cultured human breast epithelial and stromal cells. *J Clin Invest* 1990;85:1320-3.
- 65 Lester J, Stout AP. Cystosarcoma phylloides. *Cancer* 1954;7:335-53.
- 66 Rix DB, Tredwell SJ, Forward AD. Cystosarcoma phylloides (cellular intracanalicular fibroadenoma): clinical-pathological relationships. *Can J Surg* 1971;14:31-7.
- 67 Hawkins RE, Schofield JB, Fisher C, et al. The clinical and histologic criteria that predict metastases from cystosarcoma phylloides. *Cancer* 1992;69:141-7.
- 68 Holthouse DJ, Smith PA, Naunton-Morgan R, et al. Cystosarcoma phylloides: the Western Australian experience. *Aust N Z J Surg* 1999;69: 635-8.
- 69 Al-Jurf A, Hawk WA, Crile G. Cystosarcoma phylloides. *Surg Gynecol Obstet* 1978;146:358-64.
- 70 de Roos WK, Kaye P, Dent DM. Factors leading to local recurrence or death after surgical resection of phylloides tumours of the breast. *Br J Surg* 1999;86:396-9.
- 71 Bennett IC, Khan A, De Freitas R, et al. Phylloides tumours: a clinicopathological review of 30 cases. *Aust N Z J Surg* 1992;62:628-33.
- 72 McGregor GI, Knowing MA, Este FA. Sarcoma and cystosarcoma phylloides tumors of the breast: a retrospective of 58 cases. *Am J Surg* 1994;167:477-80.
- 73 Hines JR, Murad TM, Beal JM. Prognostic indicators in cystosarcoma phylloides. *Am J Surg* 1987;153:276-80.
- 74 Grimes MM. Cystosarcoma phylloides of the breast: histologic features, flow cytometric analysis and clinical correlations. *Mod Pathol* 1992;5:232-9.
- 75 Halverson JD, Hori-Rubaina JM. Cystosarcoma phylloides of the breast. *Am Surg* 1974;40:295-301.
- 76 Ward RM, Evans HL. Cystosarcoma phylloides. A clinicopathologic study of 26 cases. *Cancer* 1986;58:2282-9.
- 77 Hart WR, Bauer RC, Oberman HA. Cystosarcoma phylloides. A clinicopathologic study of twenty six hypercellular periductal stromal tumors of the breast. *Am J Clin Pathol* 1978;70:211-16.
- 78 Inoshita S. Phylloides tumour (cystosarcoma phylloides) of the breast: a clinicopathologic study of 45 cases. *Acta Pathol Jpn* 1988;38:21-33.
- 79 Cohn-Cedermark G, Rutqvist LE, Rosendahl I, et al. Prognostic factors in cystosarcoma phylloides. A clinicopathologic study of 77 patients. *Cancer* 1991;68:2017-22.
- 80 Bennett IC, Khan A, DeFreitas R, et al. Phylloides tumours: a clinicopathological review of 30 cases. *Aust N Z J Surg* 1992;62:628-33.
- 81 Millar EKA, Beretov J, Marr P, et al. Malignant phylloides tumours of the breast display increased stromal p53 protein expression. *Histopathology* 1999;34:491-6.
- 82 Shabalova IP, Chemeris GJ, Ermilova D, et al. Phylloides tumour: cytologic and histologic presentation of 22 cases and immunohistochemical demonstration of p53. *Cytopathology* 1997;8:177-87.
- 83 Feakins RM, Mulcahy HE, Nickols CD, et al. p53 expression in phylloides tumours is associated with histological features of malignancy but does not predict outcome. *Histopathology* 1999;35:162-9.
- 84 Keelan PA, Myers JL, Wold LE, et al. Phylloides tumor: clinicopathologic review of 60 patients and flow cytometric analysis in 30 patients. *Hum Pathol* 1992;23:1049-54.
- 85 Layfield LJ, Hart J, Neuwirth H, et al. Relation between DNA ploidy and the clinical behaviour of phylloides tumors. *Cancer* 1989;64:1486-9.
- 86 Murad TM, Hines JR, Beal J, et al. Histopathological and clinical correlations of cystosarcoma phylloides. *Arch Pathol Lab Med* 1998;112:752-6.
- 87 El-Naggar A, Ro J, McLemore D, et al. DNA content and proliferative activity of cystosarcoma phylloides of the breast: potential prognostic significance. *Am J Clin Pathol* 1990;93:480-5.
- 88 Rowell MD, Perry RR, Hsiu J-G, et al. Phylloides tumors. *Am J Surg* 1993;165:376-9.
- 89 Hiyaama E, Gollahon L, Kataoka T, et al. Telomerase activity in human breast tumours. *J Nat Cancer Inst* 1996;88:116-22.
- 90 Mokbel K, Ghilchik M, Parris CN, et al. Telomerase activity in phylloides tumours. *Eur J Surg Oncol* 1999;25:352-5.
- 91 Cant PJ, Madden MV, Close PM, et al. Case for conservative management of selected fibroadenomas of the breast. *Br J Surg* 1987;74:857-9.
- 92 Hajdu SJ, Espinosa MH, Robbins GF. Recurrent cystosarcoma phylloides: a clinico-pathologic study of 32 cases. *Cancer* 1976;38:1402-6.
- 93 Zurrida S, Bartoli C, Galimberti V, et al. What therapy for unexpected phylloide tumour of the breast? *Eur J Cancer* 1992;28:654-7.
- 94 Briggs RM, Walters M, Rosenthal D. Cystosarcoma phylloides in adolescent female patients. *Am J Surg* 1983;146:712-14.
- 95 Reinfuss M, Mitus J, Smolak K, et al. Malignant phylloides tumours of the breast. A clinical and pathological analysis of 55 cases. *Eur J Cancer* 1993;29A:1252-6.
- 96 Lee BJ, Pack GT. Giant intracanalicular fibroadenomyxoma of the breast. The so-called cystosarcoma phylloides mammae of Johannes Mueller. *Am J Cancer* 1931;15:2583-609.
- 97 Cooper WG, Ackerman LV. Cystosarcoma phylloides: with a consideration of its malignant variant. *Surg Gynecol Obstet* 1943;77:279-83.
- 98 Mokbel K, Price RK, Mostafa A, et al. Phylloides tumour of the breast: a retrospective analysis of 30 cases. *The Breast* 1999;8:278-81.
- 99 Palmer ML, De Risi DC, Pelikan A, et al. Treatment options and recurrence potential for cystosarcoma phylloides. *Surg Gynecol Obstet* 1990;170:193-6.
- 100 Faraci RP, Schour L. Radical treatment of recurrent cystosarcoma phylloides. *Ann Surg* 1974;180:796-8.
- 101 Kuipers T, Stark GB, Spilker G. Explosive malignant transformation of a primarily benign phylloides tumor. *Eur J Plast Surg* 1992;15:233-6.
- 102 Stockade AD, Leader M. Phylloides tumour of the breast: response to radiotherapy. *Clin Radiol* 1987;38:287-90.
- 103 Kessinger A, Foley JF, Lemon HM, et al. Metastatic cystosarcoma phylloides: a case report and review of the literature. *J Surg Oncol* 1972;4:131-47.
- 104 Staren ED, Lynch G, Boyle C, et al. Malignant cystosarcoma phylloides. *Am Surg* 1994;60:583-5.
- 105 Lindquist KD, Van Heerden JA, Weiland LH, et al. Recurrent and metastatic cystosarcoma phylloides. *Am J Surg* 1982;144:341-3.

- 106 Hawkins RE, Schofield JB, Wiltshaw E, *et al.* Ifosfamide is an active drug for chemotherapy of metastatic cystosarcoma phylloides. *Cancer* 1992;69:2271–5.
- 107 Burton GV, Hart LL, Leight GS, *et al.* Cystosarcoma phylloides: effective therapy with cisplatin and etoposide chemotherapy. *Cancer* 1989;63:2088–92.
- 108 Bissett D, Mallon E, Reed NS, *et al.* Cystosarcoma phylloides: heterogeneity in a rare tumour type. *J R Coll Surg Edinb* 1996;41:244–5.
- 109 Allen R, Nixon D, York M, *et al.* Successful chemotherapy for cystosarcoma in a young woman. *Arch Intern Med* 1985; 145:1127–8.
- 110 Brentani MM, Pacheco MM, Nagai MA, *et al.* Steroid receptors in cystosarcoma phylloides. *Cancer Detect Prev* 1982;5:211–19.
- 111 Rao BR, Meyer JS, Fry CG. Most cystosarcoma phylloides and fibroadenomas have progesterone receptors but lack oestrogen receptor: stromal localisation of the progesterone receptor. *Cancer* 1981;47:2016–21.

Medical Anniversary

King Edward VII, 19 July 1897

King Edward VII (1841–1910) was elected honorary FRCP at Malborough House on this day by the President, Sir Samuel Wilks, and in the presence of the Censors, Treasurer, and Registrar. He was presented with a gold headed cane, a replica of the one carried in turn by Radcliffe, Mead, Askew, Pitcairn, and Baillie and presented to the Royal College of Physicians in 1823 by Baillie's widow. During his reign, he showed continued support for medical services by opening a new wing to the London Hospital (1903), King Edward VII Sanatorium, Midhurst (1906), King Edward Hospital, Windsor (1908), and the new King's College Hospital (1909).—*D G James*