

Mycobacterium marinum Causes Both Long-Term Subclinical Infection and Acute Disease in the Leopard Frog (*Rana pipiens*)

LALITA RAMAKRISHNAN,^{1*} RAPHAEL H. VALDIVIA,¹ JAMES H. MCKERROW,²
AND STANLEY FALKOW^{1,3}

Department of Microbiology and Immunology, Stanford University School of Medicine, Stanford, California 94305-5402;¹
Departments of Pathology and Medicine, University of California, San Francisco, California 94143,
and the San Francisco Veterans Administration Medical Center, California 94121;²
and Rocky Mountain Laboratories, National Institute of Allergy and Infectious Diseases,
National Institutes of Health, Hamilton, Montana 59840³

Received 16 May 1996/Returned for modification 30 July 1996/Accepted 31 October 1996

***Mycobacterium marinum* grows at an optimal temperature of 33°C, far lower than that for *M. tuberculosis*. Consequently, *M. marinum* infection of mammals is restricted largely to the cooler surfaces of the body, such as the extremities, but it causes a systemic infection in a large number of poikilothermic animals. Here, we describe a laboratory animal model for *M. marinum* disease in the leopard frog (*Rana pipiens*), a natural host species. *M. marinum* causes a chronic granulomatous, nonlethal disease in immunocompetent frogs. Immunosuppression of the frogs with hydrocortisone results in an acute, fulminant, lethal disease. This animal model, in which a spectrum of tuberculosis-like disease can be produced, will be useful for the dissection of the genetic basis of mycobacterial pathogenesis.**

We use *Mycobacterium marinum*, a relatively rapidly growing species closely related to members of the *M. tuberculosis* complex (18), to study mycobacterial pathogenesis (16). *M. marinum* grows optimally at 25 to 35°C and poorly, or not at all, at 37°C (1, 5). It is an attractive model in that it is a well-recognized human pathogen but, consistent with its lower optimal growth temperature, causes only localized nodular and ulcerated lesions on the cooler surfaces of the extremities (15, 23). The histopathology of *M. marinum* disease in humans, called aquarium tank granuloma, resembles that of *M. tuberculosis* (10). However, in warm-blooded animals, including humans, dissemination to systemic organs occurs extremely rarely, even in the immunocompromised population (5, 14, 17, 21).

M. marinum first was isolated from dying saltwater fish in which a tuberculosis-like systemic disease was found (1). Disseminated disease, where infected animals die of acute *M. marinum* disease within a few weeks, has been produced experimentally in 50 poikilothermic species (5). Systemic disease has also been produced in mice whose body temperature was lowered to 36.5°C and in chick embryos maintained at 33 but not at 37°C (5). Conversely, a strain of *M. marinum* adapted to optimal growth at 37°C caused disseminated systemic disease when injected into mouse footpads or tail vein with a disease pattern similar to that for tuberculosis (6).

In developing *M. marinum* for the study of mycobacterial pathogenesis, we have established genetic systems, including genetic transformation (22), random transposon mutagenesis, and homologous recombination (16a), and an in vitro assay for persistence in macrophage and epithelial cell lines (16). Our initial studies also showed that frogs of the species *Rana pipiens* infected with three different strains of *M. marinum* developed a chronic granulomatous disease (16) rather than the acute lethal disease previously reported (5). We report here detailed studies on acute and chronic *M. marinum* infection of

R. pipiens. A chronic nonlethal granulomatous infection is produced unless the frogs are immunosuppressed by the administration of hydrocortisone, in which case acute fulminant disease develops. The minimal infectious dose and the behavior of an *M. marinum* uracil auxotrophic mutant in these animals are also reported.

MATERIALS AND METHODS

Bacterial strains and growth conditions. Two isolates of *M. marinum* were used: strain M, a human patient isolate obtained from the clinical laboratories of Moffitt Hospital at the University of California, San Francisco, which is the strain we have used for most of our studies (16), and strain S, an isolate obtained from a diseased fish (gift of Bev Dixon, California State University, Hayward, California).

The original isolates were restreaked for single colonies, one of which was grown at 33°C in 7H9 broth (Difco, Detroit, Mich.) supplemented with 0.5% glycerol–10% oleic acid–albumin–dextrose complex–0.01% cyclohexamide (OADC) and 0.25% Tween 80 (OADC-Tw broth) for 7 to 9 days. The cultures were then frozen (–70°C) in 50% glycerol in 1-ml aliquots. Before use, a small portion of the frozen culture was used to inoculate 10 ml of OADC-Tw broth and grown at 33°C without shaking for 5 to 7 days. This culture was kept at 4°C and 1 ml was used to inoculate 10-ml cultures, which after 3 days of growth at 33°C were used for the experiments at a cell density of 5×10^7 to 5×10^8 bacteria per ml. Cultures of *M. smegmatis* mc²155 (12) were grown in the same way from a frozen aliquot but at 37°C. Viable counts were determined by plating appropriate dilutions in phosphate-buffered saline (PBS) on 7H9 agar supplemented with OADC agar. Colonies were counted after 5 to 7 days for *M. marinum* and 2 to 3 days for *M. smegmatis*.

Eukaryotic cell lines. The mouse macrophage cell line J774A.1 (ATCC TIB67) was maintained at 37°C and with 5% CO₂ in Dulbecco's Modified Eagle media (DMEM, high glucose; Gibco, Bethesda, Md.) supplemented with 10% fetal bovine serum (Gibco) and 1 mM sodium pyruvate.

Maintenance, inoculation, and examination of frogs. Young adult (1.5 to 2 years of age) male frogs of the species *R. pipiens* (J. M. Hazen, Alburg, Vt.) were housed five to a tank in the biohazard suite of the Department of Laboratory Animal Medicine of Stanford University where the ambient temperature was 25°C. They were inoculated with varying concentrations of the isolates of *M. marinum* suspended in 0.5 ml of PBS by intraperitoneal injection. Frogs receiving hydrocortisone were housed singly. The hydrocortisone (Merck, West Point, Pa.) was administered 5 days per week by intraperitoneal injection at a dose of 6 mg per frog in 0.5 ml of PBS. Frogs were killed by putting them into a chamber containing methoxyfluorane, and their tissues were removed and examined for gross pathology. Samples of their liver and spleen were put into 10% neutral formalin for histopathological examination. These tissues were embedded in paraffin, sectioned, and stained with hematoxylin and eosin or with an acid-fast stain (Histo-tech Laboratories, Hayward, Calif.). Liver, spleen, kidney, and lung

* Corresponding author. Mailing address: Department of Microbiology and Immunology, Fairchild D309B, Stanford University School of Medicine, Stanford, CA 94305-5402. Phone: (415) 723-2671. Fax: (415) 723-1837. E-mail address: lalitar@cmgm.stanford.edu.

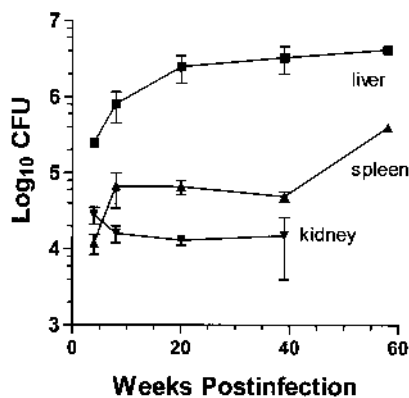


FIG. 1. Persistence of *M. marinum* in the livers, spleens, and kidneys of frogs. Each time point represents the mean for four or five frogs except the last time point at 58 weeks, which is derived from one frog tissue. Error bars represent standard errors of the mean. The CFU represent viable bacteria derived from the whole organ.

tissue samples were placed individually in 5 ml of PBS in sterile plastic bags and homogenized using a Stomacher Lab-Blender 80 (Tekmar, Cincinnati, Ohio). Dilutions of each tissue homogenate were plated onto OADC agar. Plates were assessed for the presence of colonies after incubation at 33°C for 5 to 7 days.

Derivation of a uracil auxotroph of *M. marinum*. To derive a uracil auxotroph, 10 ml of an *M. marinum* culture at an optical density at 600 nm of 0.4 to 0.6 were incubated in PBS containing 1% Tween 80 and 0.2 M methane-sulfonic acid ethyl ester (EMS; Sigma) for 2 h (13). The bacteria were washed three times and

plated on 7H9 agar containing 1 mg of 5 fluoroorotic acid per ml (American Bioorganics, Inc, Niagara Falls, N.Y.) and 200 µg of uracil (11) per ml. Colonies appearing on these plates were confirmed to be uracil auxotrophs by their lack of growth in the absence of uracil. In addition, the reversion frequency of individual colonies was tested. The reversion frequency of the uracil auxotroph, LR107-2, used in this study was less than 1.25×10^{-7} .

Invasion and persistence assay. J774A.1 cells were seeded into 24-well microdilution plates at a density of 2×10^4 cells per well in 1 ml of medium 18 to 24 h prior to use as described previously (16). Bacterial cultures were diluted into fresh DMEM to achieve a multiplicity of infection of approximately 0.1. This medium was used to replace the one in which the cells had been grown overnight. The infection was allowed to proceed for 3 h at 37°C, after which the wells were washed twice with DMEM. The cells were then incubated in 1 ml of DMEM containing 200 µg of amikacin per ml (Sigma Chemicals, St. Louis, Mo.) for 2 h at 37°C. The cell monolayers were again washed twice, and those being assessed for initial cell-associated bacteria were lysed as described below. Those being assessed for intracellular bacterial persistence were incubated at 33°C in DMEM containing 20 µg of amikacin per ml. This medium was replaced either daily or every other day with fresh medium containing 20 µg of amikacin per ml. Prior to analysis of intracellular bacterial counts, the cell monolayer was washed twice with DMEM and lysed with 0.1 ml of 1% Triton X-100 for 15 min. The lysed monolayer was brought up to a total volume of 1 ml with PBS and plated at appropriate dilutions for intracellular bacterial cell counts. Intracellular bacteria were expressed as raw numbers.

RESULTS

***M. marinum* infection causes chronic granulomas in *R. pipiens*.** To determine the time course of chronic *M. marinum* infection, frogs were inoculated with 10^6 CFU of *M. marinum*, and four or five frogs were examined at each time point post-inoculation. Colonization of the liver, spleen, kidney, and lung was achieved by 2 weeks after inoculation (Fig. 1 and data not

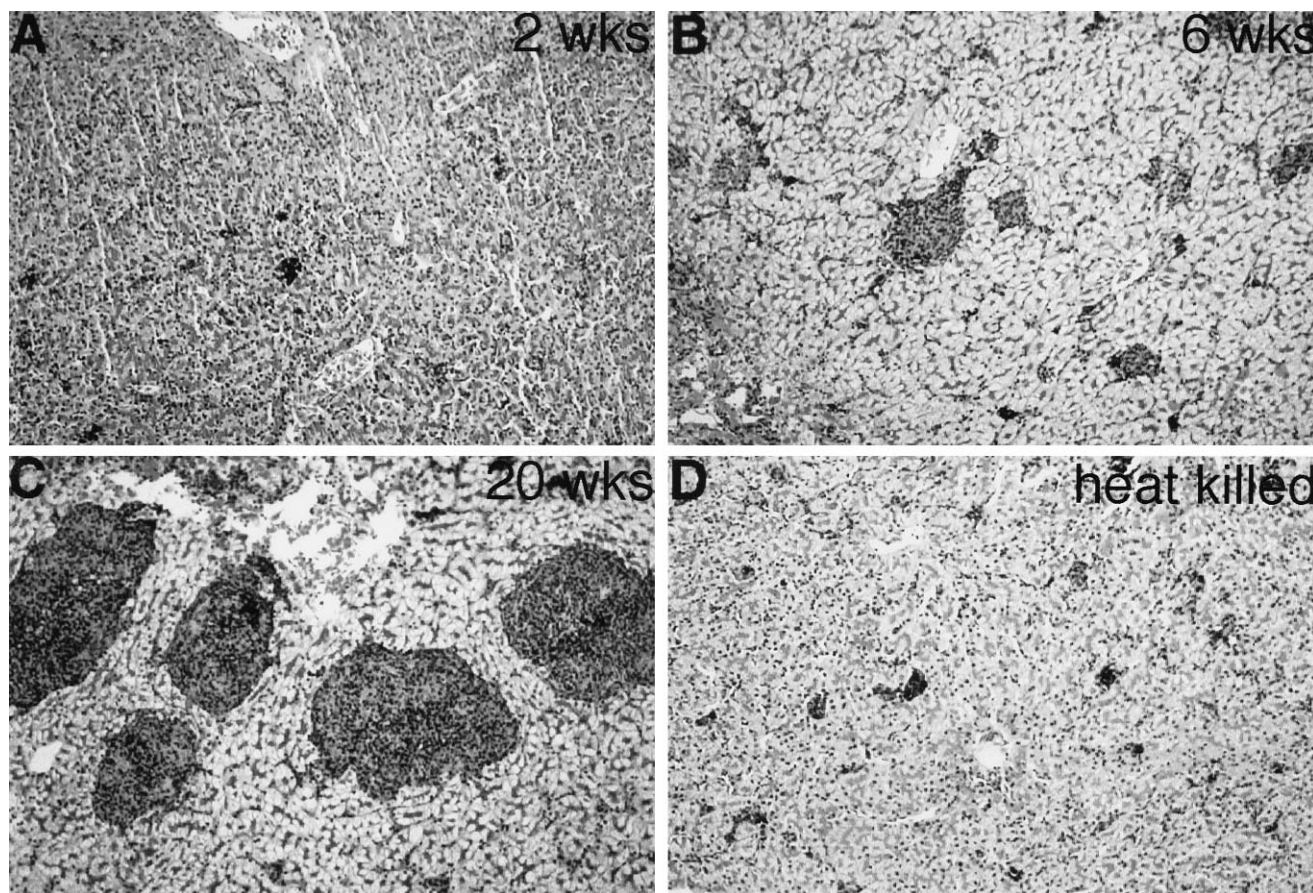


FIG. 2. Histopathology of hematoxylin and eosin-stained liver sections obtained from frogs infected with *M. marinum* for 2 (A), 8 (B), and 12 (C) weeks. (D) Liver from a frog inoculated with heat-killed *M. marinum*. Magnification, $\times 85$.

shown). *M. marinum* concentrations in these organs did not change significantly over the course of 58 weeks (Fig. 1 and data not shown).

No granulomas were seen in the liver of any of the frogs at 2 weeks postinoculation (Fig. 2A) despite the presence of greater than 10^5 CFU of *M. marinum* in this organ (data not shown). Similarly, only loose macrophage aggregates were seen in some of the spleens at 2 weeks, but no granulomas were found. At 4 weeks, either loose macrophage aggregates or very small granulomas were seen in the organs of most of the frogs (data not shown). By 6 weeks, well-defined granulomas were noted in the livers and spleens of four of the five frogs examined (Fig. 2B), and thereafter they consistently were seen in these organs of all the frogs examined (Fig. 2C). There was no consistent change in granuloma size beyond 8 weeks postinfection, although there was considerable variation in their size between animals (compare Fig. 2B and C). An identical disease pattern was produced when frogs were inoculated with 10^7 CFUs.

No frogs died of *M. marinum* infection in the 40-week observation period. Between 32 and 58 weeks postinoculation, two frogs died of intestinal tumors leading to compression of major organs and gross ascites. Adenomas were also noted in uninfected frogs as well in frogs injected with 10^7 CFU of *M. marinum* and other strains of *M. marinum* (see below). Histopathological examination revealed the tumors to be benign adenomas, with the likely cause of death secondary to intestinal obstruction. In one case, there had been a transformation to an adenocarcinoma with metastases to the liver. Furthermore, in those *M. marinum*-infected frogs developing tumors, there was no change in the pattern of chronic *M. marinum* infection as judged by tissue histopathology and bacterial CFU.

To ensure that the granuloma formation required the presence of live organisms, 10^7 heat-killed organisms were injected into each of four frogs. At 6 weeks, no organisms were detected in the frogs, nor were granulomas observed in their organs (Fig. 2D).

To determine if *M. marinum* strains derived directly from poikilothermic host species might produce the more acute, rapidly lethal disease reported previously for *R. pipiens* (5), *M. marinum* S was inoculated into four frogs at 4×10^4 CFU per animal, an inoculum at which *M. marinum* M was found to cause chronic granulomas (see below). Strain S also produced a chronic, nonlethal disease. Additionally, *M. marinum* M, which had been recovered from a frog suffering from chronic granulomas, was reinoculated into each of four frogs at 1.2×10^6 CFU and gave the same pattern of chronic disease.

Determination of the minimal infectious dose of *M. marinum*. To determine the suitability of this animal model for the isolation of genetically derived avirulent mutants, it was important to determine the minimal infectious dose required for persistence and granuloma formation. For this experiment, inocula ranging from 2.3×10 to 2×10^6 were injected into each of four frogs, and their livers and spleens were examined at 8 weeks postinfection (Table 1 and data not shown). Even at the lowest inoculum of 2.3×10 , *M. marinum* was cultured from the liver but not the spleen (limit of detection was 25 organisms). At higher inocula, organisms were detected by culture of both liver and spleen, and there was an increase in the number of organisms recovered with increasing inocula. Histopathological examination of liver tissue revealed that granulomas were present at 8 weeks only when inocula of 2.3×10^4 and greater were administered. The minimum number of persistent organisms required to stimulate granuloma formation appears to be approximately 10^4 (Table 1).

TABLE 1. Minimal infectious dose of *M. marinum*

Inoculum ^a	<i>M. marinum</i> CFU	No. of granulomas ^b
2.3×10^6	$1 \times 10^6 \pm 2.7 \times 10^5$	4/4
2.3×10^5	$4 \times 10^5 \pm 2.9 \times 10^5$	3/4
2.3×10^4	$2 \times 10^4 \pm 5.7 \times 10^3$	4/4
2.3×10^3	$8 \times 10^3 \pm 2.7 \times 10^3$	0/4
2.3×10^2	$5 \times 10^2 \pm 1.8 \times 10^2$	0/4
2.3×10^1	5×10^{2c}	0/2

^a CFU per frog. *M. marinum* CFU and granulomas were assessed in livers at 8 weeks postinoculation. Four frogs were assessed per inoculum dose, except for the 2.3×10 inoculum, where two frogs were used. The values for *M. marinum* CFU consist of means and standard errors of the mean.

^b Number of livers in which granulomas were present/number of livers examined.

^c Sample size too small to calculate standard errors of the mean. Granuloma formation was assessed by examination of hematoxylin and eosin-stained tissue.

A uracil auxotroph of *M. marinum* does not persist in *R. pipiens*. To ensure that both our in vitro macrophage and the *R. pipiens* models would be useful for the detection of *M. marinum* mutants, the uracil auxotrophic strain of *M. marinum*, strain LR107-2, was tested for persistence in both infection models. Strain LR107-2 was found to enter macrophages at the same level as the parental *M. marinum* strain, regardless of the presence of uracil in the tissue culture medium (Fig. 3A and

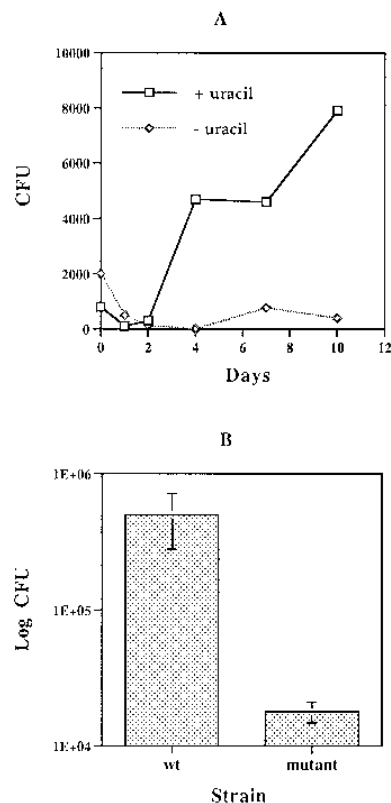


FIG. 3. (A) Persistence of the *M. marinum* uracil auxotroph, LR107-2, in J774 cells, representative of two individual experiments showing the colony counts of *M. marinum* at various time points after infection of cells at 33°C. A multiplicity of infection of 0.08 was used, and each time point represents the mean of two values. In each case, the 0 day time point reflects bacterial counts after 3 h of infection. (B) Persistence of wild-type *M. marinum* (wt) and strain LR107-2 (mutant) in the livers of frogs; each time point represents the mean of four and six frogs, respectively. Error bars represent standard errors of the mean. The CFU represent viable bacteria derived from the whole organ.

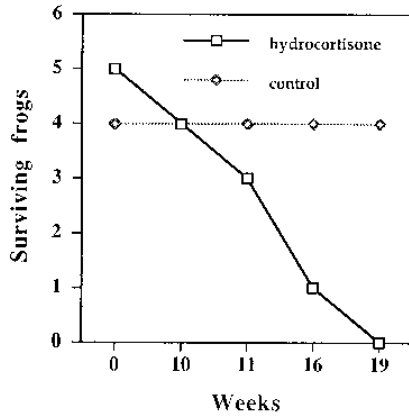


FIG. 4. Survival of *M. marinum*-infected frogs when treated with hydrocortisone. The control frogs represent those infected with *M. marinum* and uninfected frogs treated with hydrocortisone. Both of these groups (four frogs per group) had identical survival profiles.

data not shown). However, it did not persist within macrophages in the absence of uracil (Fig. 3A). If uracil was added to the tissue culture medium at a concentration of 120 $\mu\text{g/ml}$, the level of persistence and replication of LR107-2 was similar to that for parental *M. marinum* (Fig. 3A and data not shown).

The LR107-2 strain (6.0×10^6 CFU) was injected into each of six frogs intraperitoneally, and the animals were killed at 7 weeks. The number of CFU recovered from the livers of these frogs was significantly lower than that recovered from the livers of frogs inoculated with a similar number of CFU of the parental *M. marinum* strain (Fig. 3B). Granuloma formation was also very minimal in the LR107-2-infected livers (data not shown). Although strain LR107-2 clearly did not persist in frogs, it is interesting to note that it was not cleared as rapidly as the nonpathogen *M. smegmatis*. When *M. smegmatis* ($2.5 \times$

10^8 CFU) was injected into frogs, bacteria were undetectable by 4 weeks postinfection.

Administration of hydrocortisone to *M. marinum*-infected frogs induces a fulminant lethal disease. To determine if modulation of the host immune response would alter the pattern of *M. marinum*-induced disease, frogs were injected intraperitoneally with hydrocortisone (6 mg per frog) 5 days a week. This dose has been shown to suppress cellular immunity, particularly T-lymphocyte function in frogs (19, 20). Seven days after a single intraperitoneal dose of hydrocortisone, the peripheral lymphocyte count was depleted to less than half that of controls, as reported previously (3, 4). Four weeks after the hydrocortisone injections began, the frogs were given a single intraperitoneal injection of 2.4×10^7 CFU of *M. marinum*. The hydrocortisone doses were continued on the same schedule until the completion of the experiment.

Seven frogs received both hydrocortisone and *M. marinum*, while four frogs each received either the same single dose of *M. marinum* or the same schedule of hydrocortisone injections. Five of the seven frogs from the hydrocortisone group died within 19 weeks of *M. marinum* infection (Fig. 4). The two survivors were killed at 19 weeks, and one of these showed signs of fulminant disease as judged by histopathological findings. (The remaining frog had evidence only of chronic infection.) In contrast, all of the frogs from the other two groups survived for the duration of the experiment.

On necropsy, all five hydrocortisone-treated frogs that died and one of the two that were killed had peritoneal and intestinal adhesions and multiple surface liver abscesses. In addition, one of the frogs had a fistulous tract originating from the intestine and opening onto the skin of the abdominal wall. Microscopic examination of the surface abscesses from the organs revealed inflammatory cells and numerous acid-fast bacilli (Fig. 5). Histopathology of the organs revealed that five of the six frogs with fulminant disease had either focal infiltrates of chronic inflammatory cells but no granulomas (Fig. 6A) or very poorly formed granulomas (Fig. 6B). Only one of

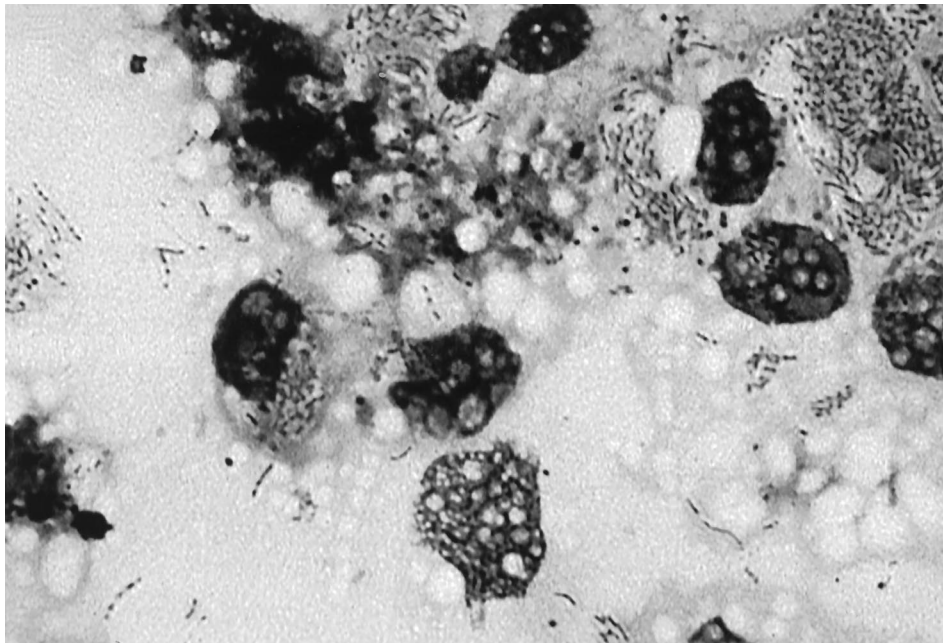


FIG. 5. Acid-fast stain of smear derived from surface liver abscess of an *M. marinum* infected frog treated with hydrocortisone. Magnification, $\times 1,000$.

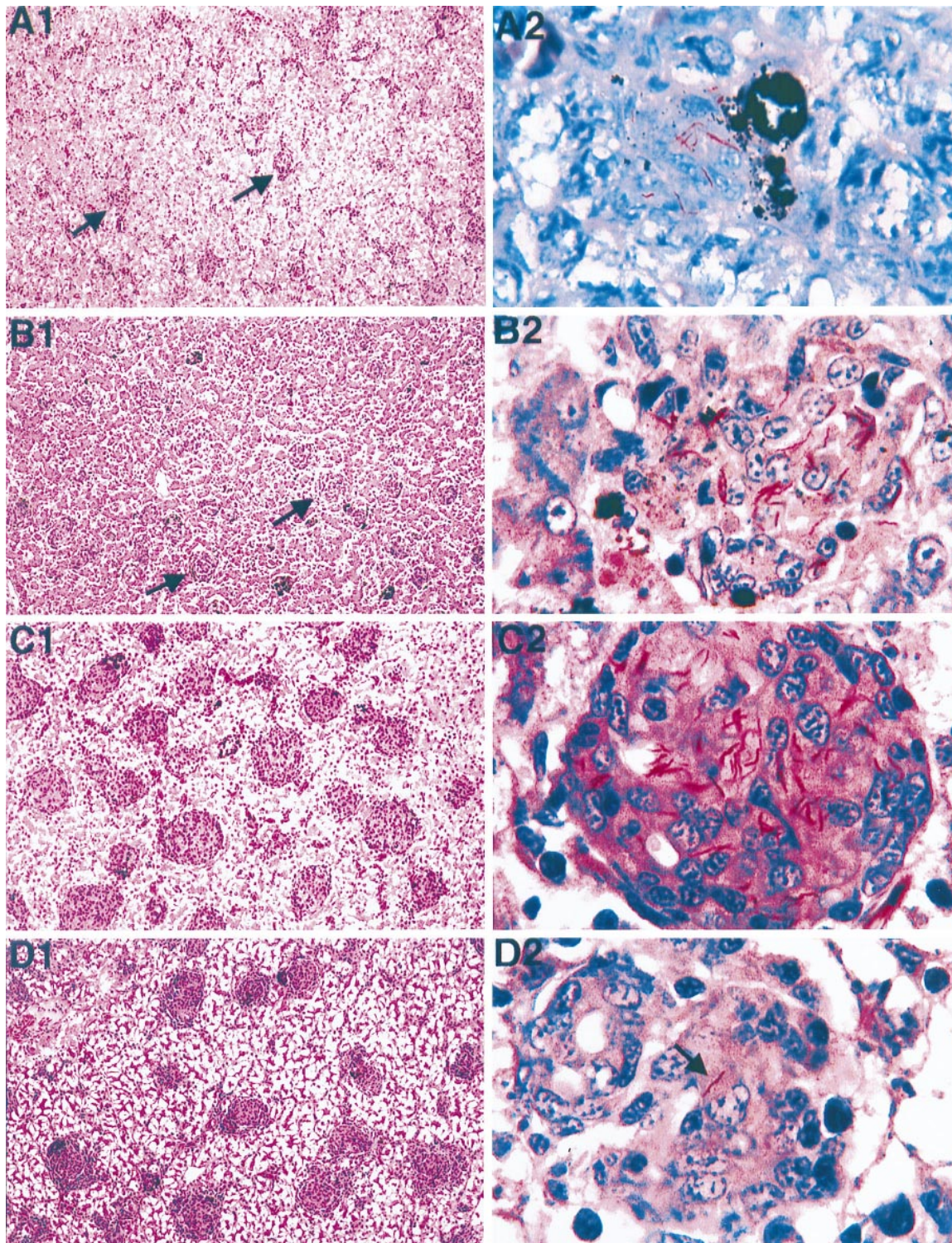


FIG. 6. Histopathology of hematoxylin and eosin-stained sections of livers obtained from *M. marinum*-infected frogs treated with hydrocortisone (A1, B1, and C1) and a frog infected with *M. marinum* but not treated with hydrocortisone (D1). Magnification, $\times 100$. Arrows point to chronic focal infiltrates (A1) and to poorly formed granulomas (B1). Panels A2, B2, C2, and D2 show acid-fast staining of the same tissues shown in panels A1, B1, C1, and D1, respectively. Magnification, $\times 1,000$. Arrow in panel D2 points to single acid-fast bacillus seen in the lesion.

the frogs had well-formed granulomas (Fig. 6C). Acid-fast staining of liver tissue revealed a very high density of *M. marinum* organisms in the hydrocortisone-treated frogs (Fig. 6A1, B1, and C1). This was the case even with the frog that had

well-formed granulomas (Fig. 6C). In contrast, the livers from the control *M. marinum*-infected frogs had at most one or two organisms per granuloma (Fig. 6D) as shown previously (16). Evaluation of *M. marinum* CFU was not possible in most of the

hydrocortisone-treated frogs that were found dead, owing to overgrowth of the plates with rapidly growing bacteria likely originating from the tank water. In the two frogs in which this assessment was possible, a mean of 2.8×10^7 (range, 1.9×10^7 to 3.7×10^7) CFU of *M. marinum* was found in the liver. In contrast, far fewer viable bacteria (mean 6.9×10^5 CFU; range, 4.2×10^5 to 6.9×10^5) were found in the livers of the three control *M. marinum*-infected frogs examined.

DISCUSSION

We have established a reliable animal infection model for *M. marinum*. Five different strains of *M. marinum* derived from both human clinical isolates and from fish and frogs ([16, 16b]; also this study) have now been tested in *R. pipiens*, and all cause a chronic granulomatous infection over a range of inocula. Thus, our findings are quite different from those of previous studies that have reported an acute ulcerative lethal disease in frogs (including *R. pipiens*) and other poikilothermic animals when either a fish or a human isolate of *M. marinum* was injected intraperitoneally (1, 5). In those studies, very few animals of each species were used (for example, two *R. pipiens* frogs) and tissue histopathology was not reported (5). Clark and Shepard (5) used amphibians that they caught in the wild (and were therefore of unknown age) and that were maintained without feeding for the course of the study. The *R. pipiens* frogs we used were young, bred in captivity, and fed regularly. Thus, it is most likely that the differences in disease pattern are due to differences in host susceptibility deriving from nutritional status, age, and other factors. Consistent with our findings, *M. marinum* has been previously recognized as the causative agent of a chronic wasting disease in fish, taking up to 1 year to kill them (8). Goldfish inoculated at a central midventral point of the abdomen with 10^8 CFU of *M. marinum* M have not succumbed to disease in over 6 months (our unpublished results).

An intraperitoneal inoculum as low as 2.3×10 organisms is sufficient to sustain a persistent infection in *R. pipiens*. That the infectious dose is small makes this animal model system suitable for the use of newly devised techniques to identify virulence mutants (9, 22).

The *R. pipiens* infection model and in vitro persistence assay for *M. marinum* are complementary. Both the uracil auxotrophic mutant (this study) and a smooth variant of another strain of *M. marinum* (16b) that fail to persist in macrophages in vitro do not persist or cause granulomas in *R. pipiens*. Hence, in principal, both our in vitro and animal models could be used to identify avirulent mutants from a random bank of transposon mutants (9). It is interesting to note that both *M. marinum* mutants persist in frogs for considerably longer than the non-pathogen *M. smegmatis*, which dies very soon after inoculation into animals. This result also parallels our findings in macrophage cells in vitro (16). The uracil auxotrophs of pathogenic bacteria may have applications as vaccine strains, since they may persist long enough for a host cell response to be mounted. In this context, there is a previous study documenting the protective effect of *M. marinum* inoculation against a subsequent challenge with *M. tuberculosis* in mice (6).

Our results suggest that *M. marinum* is a suitable model for the study of mycobacterial pathogenesis as judged by its chronic course and latency. The typical histopathology with chronic granulomas and the sparsity of acid-fast bacilli in the lesions are reminiscent of *M. tuberculosis* infection of an immunocompetent human host. One-third of the frogs eventually died of adenomas unrelated to *M. marinum* infection at between 32 and 58 weeks of study. We do not believe that this

finding detracts in any way from the use of these animals to study chronic *M. marinum* disease, particularly in light of our finding that the course of the infection remains essentially unchanged after 8 to 12 weeks postinfection.

The course of the disease is completely altered by immunosuppression of the frogs with corticosteroids, consistently resulting in a fulminant, lethal disease. In this form of the disease, there is uncurtailed bacillary replication, with abscess and fistula formation. A similar lethal infection results when mice inoculated with *M. tuberculosis* are treated with glucocorticosteroids (2). The corticosteroid-treated mice also were found to have enhanced bacillary replication. Such features are also characteristic of tuberculosis in a highly immunosuppressed human host (7). In all but one of the frogs with fulminant disease, steroid treatment resulted in impairment of granuloma formation. Even in the one case where granuloma formation was comparable to that in the chronically infected frogs, there was abundant replication of *M. marinum*. This result indicates that even if epithelioid macrophages can be recruited to the site of infection, their function is impaired by corticosteroids. We are currently testing whether steroids can reactivate the subclinical form of the disease in frogs.

The finding that *M. marinum* disease in frogs has the characteristics of chronic mycobacterial disease, including a latent state, will allow us to use it to identify *M. marinum* mutants relevant for mycobacterial persistence and other pathogenic traits. The fact that persistent disease is produced in a natural host species, coupled with our ability to modulate the host response to produce acute disease, adds to the attractiveness of this inexpensive laboratory animal model.

ACKNOWLEDGMENTS

This work was supported by a Howard Hughes physician postdoctoral fellowship to L.R., by National Institutes of Health grant AI36396, and by unrestricted grants from Bristol-Myers Squibb and Lederle-Praxis Biologicals to S.F. J.H.M. was supported by the World Health Organization TDR on Pathogenesis and the Burroughs Wellcome Fund.

We thank Louise Rollins-Smith for advice on immunosuppression of frogs, Phil Verzola and Paul Edelstein for help with the figures, and Paul Edelstein, Steve Porter, Luiz Bermudez, and Sara Fisher for a critical reading of the manuscript. We appreciate the thoughtful comments of an anonymous reviewer.

ADDENDUM IN PROOF

The goldfish inoculated with *M. marinum* described in the Discussion were recently killed 1 year postinoculation and found to have persistent *M. marinum* infections in their livers, spleens, and kidneys despite the absence of any overt signs of disease.

REFERENCES

1. Aronson, J. D. 1926. Spontaneous tuberculosis in salt water fish. *J. Infect. Dis.* **39**:315-320.
2. Batten, J. C., and R. M. McCune, Jr. 1957. The influence of corticotrophin and certain corticosteroids on populations of *Mycobacterium tuberculosis* in tissues of mice. *Br. J. Exp. Pathol.* **38**:424-437.
3. Bennett, M., and J. Alspaugh. 1964. Some changes in the blood of frogs following administration of hydrocortisone. *Va. J. Sci.* **15**:76-79.
4. Bennett, M., and N. Newell. 1965. A further study of the effects of hydrocortisone on the blood of frogs. *Va. J. Sci.* **16**:128-130.
5. Clark, H. F., and C. C. Shepard. 1963. Effect of environmental temperatures on infection with *Mycobacterium marinum* (*balnei*) of mice and a number of poikilothermic species. *J. Bacteriol.* **86**:1057-1069.
6. Collins, F. M., V. Montalbini, and N. E. Morrison. 1975. Growth and immunogenicity of photochromogenic strains of mycobacteria in the footpads of normal mice. *Infect. Immun.* **11**:1079-1087.
7. Dannenberg, A. M., Jr. 1993. Immunopathogenesis of pulmonary tuberculosis. *Hosp. Prac.* **28**:51-58.
8. Gray, S. F., R. S. Smith, N. J. Reynolds, and E. W. Williams. 1990. Fish tank granuloma. *Br. Med. J.* **300**:1069-1070.

9. Hensel, M., J. E. Shea, C. Gleeson, M. D. Jones, E. Dalton, and D. W. Holden. 1995. Simultaneous identification of bacterial virulence genes by negative selection. *Science* **269**:400–403.
10. Huminer, D., S. D. Pitlik, C. Block, L. Kaufman, S. Amit, and J. B. Rosenfeld. 1986. Aquarium-borne *Mycobacterium marinum* skin infection. Report of a case and review of the literature. *Arch. Dermatol.* **122**:698–703.
11. Husson, R. N., B. E. James, and R. A. Young. 1990. Gene replacement and expression of foreign DNA in mycobacteria. *J. Bacteriol.* **172**:519–524.
12. Jacobs, W. R., Jr., G. V. Kalpana, J. D. Cirillo, L. Pascopella, R. A. Udani, W. D. Jones, Jr., R. G. Barletta, and B. R. Bloom. 1991. Genetic systems for mycobacteria. *Methods Enzymol.* **204**:537–555.
13. Konicek, J., and I. Malek. 1969. The mutagenic effect of ethyl methane sulfonate on a non-acid-fast strain of *Mycobacterium phlei*. *Folia Microbiol.* **14**:194–200.
14. Lambertus, M. W., and G. E. Mathisen. 1988. *Mycobacterium marinum* infection in a patient with cryptosporidiosis and the acquired immunodeficiency syndrome. *Cutis* **41**:38–40.
15. Linell, F., and A. Norden. 1954. *Mycobacterium balnei*, a new acid fast bacillus occurring in swimming pools and capable of producing skin lesions in humans. *Acta Tuberc. Scand.* **33**(Suppl.):1–84.
16. Ramakrishnan, L., and S. Falkow. 1994. *Mycobacterium marinum* persists in cultured mammalian cells in a temperature-restricted fashion. *Infect. Imm.* **62**:3222–3229.
- 16a. Ramakrishnan, L., R. McAdam, W. R. Jacobs, Jr., and S. Falkow. Unpublished results.
- 16b. Ramakrishnan, L., and P. L. C. Small. Unpublished results.
17. Ries, K., G. White, and R. Murdock. 1990. Atypical mycobacterial infection caused by *Mycobacterium marinum*. *N. Engl. J. Med.* **322**:633.
18. Rogall, T., J. Wolters, T. Flohr, and E. Bottger. 1990. Towards a phylogeny and definition of species at the molecular level within the genus *Mycobacterium*. *Int. J. Syst. Bacteriol.* **40**:323–330.
19. Rollins, L., and R. G. McKinnell. 1980. The influence of glucocorticoids on survival and growth of allografted tumors in the anterior eye chamber of leopard frogs. *Dev. Comp. Immunol.* **4**:283–294.
20. Ruben, L., and M. Vaughan. 1974. The effect of hydrocortisone on the sheep red cell response in adult *Xenopus laevis*, the South African clawed toad. *J. Exp. Zool.* **190**:229–236.
21. Tchorobay, A.-M., A. Claudy, J.-L. Perrot, M. Levigne, and M. Denis. 1992. Fatal disseminated *Mycobacterium marinum* infection. *Int. J. Dermatol.* **31**:286–287.
22. Valdivia, R. H., A. Hromockyj, D. Monack, L. Ramakrishnan, and S. Falkow. 1996. Applications for the green fluorescent protein (GFP) in the study of host-pathogen interactions. *Gene* **173**:47–52.
23. Woods, G. L., and J. A. Washington II. 1987. *Mycobacteria* other than *Mycobacterium tuberculosis*: review of microbiologic and clinical aspects. *Rev. Infect. Dis.* **9**:275–293.

Editor: R. E. McCallum