

## Letters

### M2-AMA do not directly produce ANCA indirect immunofluorescence patterns

The importance of distinguishing atypical cytoplasmic indirect immunofluorescence patterns from the "classic", centrally accentuated cytoplasmic immunofluorescence pattern on ethanol fixed human neutrophils has recently been re-emphasised.<sup>1-3</sup> Autoantibodies to other cytoplasmic autoantigens such as antimitochondrial antibodies (AMA), antismooth muscle antibodies, and antiribosomal-P antibodies have also recently been reported to produce atypical cytoplasmic immunofluorescence patterns on ethanol fixed human neutrophils.<sup>1</sup> However, an alternative explanation is that the atypical cytoplasmic immunofluorescence patterns might be produced by concomitant antineutrophil cytoplasmic antibodies (ANCA) in these sera, especially in cases of autoimmune liver disease. Therefore, we investigated: (1) whether sera containing AMA with confirmed M2 specificity<sup>4</sup> produced positive indirect immunofluorescence patterns on ethanol fixed human neu-

trophils, and (2) the precise neutrophil antigen specificity of such sera.

Thirty two sera from different patients with confirmed M2-AMA specificity (using the Inova Diagnostics (San Diego, California, USA) M2-AMA enzyme linked immunosorbent assay (ELISA)), were tested by indirect immunofluorescence on in house, ethanol fixed, normal human neutrophils and commercial HEP-2 cells (Sanofi Diagnostics Pasteur Chaska, Minnesota, USA). Twelve of the 32 patients had liver biopsies, which showed primary biliary cirrhosis in nine cases and autoimmune chronic active hepatitis in three. All 32 sera were also tested on the ORGenTec (Mainz, Germany) Combi-kit® ELISA against the following neutrophil antigens: proteinase 3, myeloperoxidase, lactoferrin, elastase, cathepsin G, lysozyme, and bactericidal/permeability increasing protein (BPI).

Table 1 gives the results. Thirteen of the 32 M2-AMA sera produced positive indirect immunofluorescent staining on the ethanol fixed neutrophils: ten had a perinuclear pattern (two of which might have been produced by concomitant ANA), and three had an atypical cytoplasmic pattern. The ORGenTec Combi-kit ELISA revealed that 22 (comprising all 13 sera that were immunofluorescence positive, and nine that were negative) of the 32 sera contained ANCA directed specifically against the following

neutrophil antigens: BPI (n = 13), cathepsin G (n = 8), lactoferrin (n = 7), elastase (n = 2), proteinase 3 (n = 2), and lysozyme (n = 1). Five of these 22 sera contained ANCA against two neutrophil antigens, one against three neutrophil antigens, and one against five neutrophil antigens.

The immunofluorescence staining pattern did not appear to predict antigen specificity because the three atypical cytoplasmic immunofluorescence positive sera were associated with either antineutrophil G antibodies (n = 2) or anti-BPI antibodies (n = 1). Furthermore, the 10 perinuclear immunofluorescence positive sera were associated with either anti-BPI antibodies alone (n = 2), antineutrophil G antibodies alone (n = 1), antilactoferrin antibodies alone (n = 1), antilysozyme antibodies alone (n = 1), or a combination of two or more antibodies (n = 5). Finally, 10 of the 32 sera were negative for ANCA by both immunofluorescence and ELISA.

Therefore, we conclude that M2-AMA do not directly produce positive indirect immunofluorescence patterns on ethanol fixed human neutrophils. Rather, a positive indirect immunofluorescence pattern in M2-AMA positive sera appears to be produced by concomitant ANCA directed against a variety of neutrophil antigens such as BPI, cathepsin G, and lactoferrin. Further studies are necessary to determine whether autoantibodies to other cytoplasmic autoantigens directly produce positive immunofluorescence patterns on ethanol fixed human neutrophils,<sup>1</sup> or whether these sera contain concomitant ANCA.

Table 1 Results of M2-AMA ELISA, ANCA IIF and ANCA Combi-kit® ELISA

Specimen	M2-AMA ELISA	ANCA IIF pattern (titre)	ANCA Combi-kit® ELISA (OD ratio)	Liver biopsy result
1	High positive	Negative	Anti-BPI (2.47)	PBC
2	High positive	Negative	Negative	PBC
3	High positive	Negative	Negative	PBC
4	High positive	Atypical cytoplasmic (1/40)	Anticathepsin G (1.31)	PBC
5	High positive	Negative	Antilactoferrin (1.08)	PBC
6	High positive	Negative	Anti-BPI (1.24)	PBC
			Antiproteinase 3 (1.13)	
7	High positive	Negative	Anti-BPI (1.79)	PBC
8	High positive	Negative	Anti-BPI (2.79)	Not done
9	High positive	Negative	Negative	Not done
10	High positive	Negative	Negative	Not done
11	High positive	Perinuclear (1/160)	Anti-BPI (1.60)	Not done
			Anticathepsin G (2.02)	
12	High positive	Negative	Anti-BPI (1.02)	Not done
			Antilactoferrin (2.35)	
13	High positive	Perinuclear (1/160)	Anti-BPI (3.04)	Not done
			Anticathepsin G (2.14)	
			Antilactoferrin (1.6)	
14	High positive	Perinuclear (1/160)	Anti-BPI (1.17)	Not done
15	High positive	Perinuclear (1/640)	Antilactoferrin (4.37)	Not done
16	High positive	Perinuclear/nuclear (1/160)†	Anti-BPI (1.30)	Not done
17	High positive	Negative	Antilactoferrin (1.07)	Not done
18	High positive	Negative	Antilactoferrin (1.03)	Not done
19	Mod positive	Perinuclear (1/40)	Antilysozyme (1.41)	PBC
20	Mod positive	Negative	Negative	AICAH
21	Mod positive	Perinuclear/nuclear (1/40)#	Anticathepsin G (1.02)	AICAH
22	Mod positive	Negative	Anticathepsin G (4.24)	Not done
23	Mod positive	Negative	Negative	Not done
24	Mod positive	Perinuclear (1/160)	Anti-BPI (4.01)	Not done
			Anticathepsin G (1.74)	
			Antielastase (1.11)	
			Antilactoferrin (2.12)	
			Antiproteinase-3 (1.05)	
25	Mod positive	Negative	Negative	Not done
26	Low positive	Atypical cytoplasmic (1/40)	Anticathepsin G (1.00)	PBC
27	Low positive	Perinuclear (1/160)	Anti-BPI (1.49)	AICAH
			Anti-elastase (1.46)	
28	Low positive	Negative	Negative	Not done
29	Low positive	Atypical cytoplasmic (1/40)	Anti-BPI (1.35)	Not done
30	Low positive	Negative	Negative	Not done
31	Low positive	Perinuclear	Anti-BPI (1.74)	Not done
			Anticathepsin G (1.03)	
32	Low positive	Negative	Negative	Not done

ORGenTec ANCA Combi-kit® ELISA OD (optical density) ratio: positive ≥ 1, negative < 1.

†Concomitant ANA staining (1/640 titre) with a nuclear membrane pattern was present.

#Concomitant ANA staining (1/40 titre) with homogeneous and speckled patterns was present.

AICAH, autoimmune chronic active hepatitis; AMA, antimitochondrial antibodies; ANCA, antineutrophil cytoplasmic antibodies; BPI, bactericidal/permeability increasing protein; ELISA, enzyme linked immunosorbent assay; IIF, indirect immunofluorescence; PBC, primary biliary cirrhosis.

R C W WONG  
R WILSON  
J NEIL  
Division of Immunology,  
Queensland Health Pathology Services,  
Royal Brisbane Hospital,  
Herston 4029, Brisbane, Australia

S ADELSTEIN  
Department of Clinical Immunology,  
Royal Prince Alfred Hospital, Australia

R A SILVESTRINI  
E M BENSON  
Department of Immunopathology, ICPMR,  
Westmead Hospital, Australia

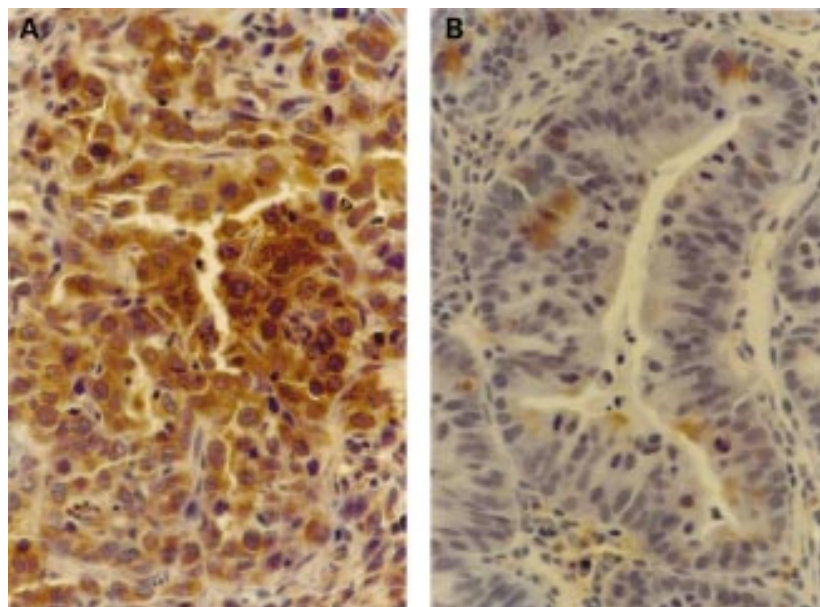
L POWELL  
Queensland Institute of Medical Research, Australia

- Savage JA, Paspaliaris B, Silvestrini R, et al. A review of immunofluorescent patterns associated with antineutrophil cytoplasmic antibodies (ANCA) and their differentiation from other antibodies. *J Clin Pathol* 1998;51:568-75.
- Wong RCW, Silvestrini RA, Savage JA, et al. Diagnostic usefulness of classical and atypical cytoplasmic ANCA (antineutrophil cytoplasmic antibody) immunofluorescence patterns. *J Clin Pathol* 1999;52:124-8.
- Gross WL. Antineutrophil cytoplasmic autoantibody testing in vasculitides. *Rheum Dis Clin North Am* 1995;21:987-1011.
- Bylund DJ, McHutchison J. Autoimmune liver diseases. *Clin Lab Med* 1997;17:483-97.

### Raised plasma parathyroid hormone related peptide in gastric adenocarcinoma

We report a case of humoral hypercalcemia associated with a rapidly growing gastric carcinoma. To our knowledge, this is the first such case of gastric carcinoma reported with raised plasma parathyroid hormone related peptide (PTHrP) and absent bone metastases.

A 69 year old woman presented with fatigue and intermittent sharp epigastric pain for one week. Upper gastrointestinal radiographs and endoscopy demonstrated a necrotic, friable mass in the mid stomach. Biopsy of the mass and a surrounding satellite



**Figure 1** The figure shows representative tissue from multiple gastric biopsies in which the expression of parathyroid hormone related peptide (PTHrP) was investigated using a horseradish peroxidase labelled polyclonal rabbit antibody directed against amino acids 1–34 of human PTHrP: (A) Gastric adenocarcinoma showing expression of PTHrP and (B) gastric adenoma showing no expression of PTHrP

polypoid lesion showed poorly differentiated adenocarcinoma and gastric adenoma with high grade dysplasia, respectively (fig 1). Four weeks after the first symptoms had arisen the liver edge was palpable 3 cm below the costal margin. Computed tomographic scan of the abdomen demonstrated several hypodense lesions in the liver and aortic adenopathy compatible with metastases. The following results were found: haematocrit, 0.24; white blood cell count,  $12.7 \times 10^9$ /litre; platelets,  $460 \times 10^9$ /litre; calcium, 2.54 mmol/litre; albumin, 31 g/litre; international normalised ratio, 1.2; alkaline phosphatase, 1075 units/litre; alanine amino transferase, 16 units/litre; total bilirubin, 10.26  $\mu$ mol/litre; lactate dehydrogenase, 1765 units/litre; carcinoembryonic antigen, 327  $\mu$ g/litre; ferritin, 302  $\mu$ g/litre; Fe,  $< 2 \mu$ mol/litre; and total iron binding capacity,  $< 21 \mu$ mol/litre. Chest x ray was negative. Two weeks later the patient developed mental confusion and dehydration. Serum calcium was 2.8 mmol/litre, phosphorus 0.5 mmol/litre, and albumin 26 g/litre. With intravenous hydration and pamidronate (90 mg), serum calcium rapidly became normal and the patient's mental status returned to baseline. Neither radionuclide bone scan nor magnetic resonance scan of the brain suggested metastases. The intact PTH (IRMA; Nichols Institute) was 6 ng/litre (normal, 10–65). However, PTHrP (1–40 IRMA; Nichols Institute) was 5.4 pmol/litre (normal  $< 1.3$ ). The patient died of progressive liver failure three weeks later.

Hypercalcaemia is rarely associated with gastric cancer. In the literature, two cases of gastric adenocarcinoma with hypercalcaemia have been reported in which the tumour cells expressed PTHrP.<sup>1,2</sup> In both cases, bone metastases were present and plasma PTHrP values were not reported. Alipov *et al* found that PTHrP was expressed on tumour cells in 71 of 92 patients with gastric adenocarcinoma, none of whom had humoral hypercalcaemia.<sup>3</sup> PTHrP expression in the tumour tissue was strongly associated with poorly differentiated cancers (34 of 34) as opposed to well differentiated ones (10 of 23). Normal gastric mucosa

and adenomas did not express PTHrP. Our case is consistent with the findings of Alipov *et al* because cancer cells expressed PTHrP, whereas adenoma did not (fig 1). Our case is notable for rapid clinical deterioration coupled with raised tissue and plasma PTHrP. These results suggest that PTHrP expression is associated with poor prognosis in gastric cancer. Whether PTHrP plays a direct role in cancer progression<sup>4</sup> or is a byproduct of oncogene activation (for example, ras and src<sup>5</sup>) remains to be determined.

GEORG ENGELICH  
NIAL SWAN  
KEVAN L HARTSHORN

Boston University School of Medicine and Boston Medical Center, Departments of Medicine and Pathology, 80 East Concord Street, Boston, MA 02118, USA

- 1 Ito M, Nakashima M, Alipov G, *et al*. Gastric cancer associated with overexpression of parathyroid hormone-related peptide (PTHrP) and PTH/PTHrP receptor in relation to tumor progression. *J Gastroenterol* 1997;32:396–400.
- 2 Abdeen O, Pandol S, Burton D, *et al*. Parathyroid hormone related protein expression in human gastric adenocarcinomas not associated with hypercalcaemia. *Am J Gastroenterol* 1995; 90:1864–7.
- 3 Alipov G, Ito M, Nakashima M, *et al*. Expression of parathyroid hormone related peptide in gastric tumours. *J Pathol* 1997;182:174–9.
- 4 Guise TA. Parathyroid hormone-related protein and bone metastasis. *Cancer* 1997;80:1572–80.
- 5 Li X, Drucker DJ. Parathyroid hormone-related peptide is a downstream target for ras and src activation. *J Biol Chem* 1994;269:6263–6.

#### ELISA is the superior method for detecting antineutrophil cytoplasmic antibodies in the diagnosis of systemic necrotising vasculitis

Dr Harris's results<sup>1</sup> showed that indirect immunofluorescence is a more sensitive technique than antigen specific enzyme linked immunosorbent assay (ELISA) for the diagnosis of systemic necrotising vasculitis (70% *v* 50%) but that ELISAs have a higher positive predictive value (87% *v* 76%). It was the greater sensitivity of indirect immunofluorescence that prompted the "Inter-

national consensus statement on testing and reporting antineutrophil cytoplasmic antibodies (ANCA)"<sup>2</sup> to require all laboratories to screen for ANCA by indirect immunofluorescence, but to confirm the specificity of fluorescent sera by ELISA. In our hands, adherence to the minimum requirements of the consensus statement results in a higher positive predictive value than either indirect immunofluorescence or ELISA alone (62% compared with 44% and 50%, respectively). Screening by indirect immunofluorescence has the additional advantages of being a quicker and cheaper technique than using the two commercial antigen specific ELISAs that are usually required and, furthermore, indirect immunofluorescence might demonstrate coincidental but unsuspected autoantibodies such as antinuclear antibodies. We believe that the use of ELISAs alone to diagnose a systemic necrotising vasculitis is analogous to testing for systemic lupus erythematosus with anti-double stranded DNA antibodies rather than initially screening for antinuclear antibodies by indirect immunofluorescence.

JUDY SAVIGE

University Department of Medicine,  
The University of Melbourne,  
Austin and Repatriation Medical Centre,  
Heidelberg, Victoria 3084, Australia

PAUL NEESON

MICHELE TREVISIN

PETER GAMBEL

Division of Investigational Medicine,  
Austin and Repatriation Medical Centre

WENDY POLLOCK

Gribble's Pathology, 14 Yarra Street,  
Private Bag 1800, South Yarra,  
Victoria 3141, Australia

- 1 Harris A, Chang G, Vadas M, *et al*. ELISA is the superior method for detecting antineutrophil cytoplasmic antibodies in the diagnosis of systemic necrotising vasculitis. *J Clin Pathol* 1999;52:670–6.
- 2 Savige J, Gillis D, Davies D, *et al*. International consensus statement on testing and reporting of antineutrophil cytoplasmic antibodies (ANCA). *Am J Clin Pathol* 1999;111:507–13.

#### The authors reply

Our study was carried out following the preliminary observation that in our laboratory a positive immunofluorescence antineutrophil cytoplasmic antibody (ANCA) result was less frequently associated with a diagnosis of systemic necrotising vasculitis than a positive enzyme linked immunosorbent assay result (PR3 or myeloperoxidase). Our clinicians frequently did not alter management based on the immunofluorescence ANCA result. In fact, our renal physicians invariably proceeded with renal biopsy, regardless of immunofluorescence results, to confirm or refute the diagnosis of systemic necrotising vasculitis. The ELISA result frequently came back too late to alter clinical management, the ELISA test being done when immunofluorescence was positive. Our study has shown that for active systemic necrotising vasculitis, ELISA has a superior positive predictive value and specificity, and comparable sensitivity to the immunofluorescence technique.

Savige *et al* quoted our sensitivity results with respect to "all cases" of systemic necrotising vasculitis, active and inactive combined, which are largely irrelevant parameters in clinical practice because the need is to identify active cases. The principal result of the study was the finding that in active, biopsy confirmed cases of systemic necrotising vasculitis, ELISA ANCA is just as sensitive (85% *v* 88%; *p* = 0.056) yet has a signifi-

cantly better specificity (97% *v* 90%;  $p = 0.0006$ ) and positive predictive value (73% *v* 50%;  $p = 0.0013$ ) compared with immunofluorescence ANCA.

The fact that the sensitivity of ELISA ANCA falls as inactive cases are added to active cases implies that ELISA more quickly becomes negative as active disease settles, whereas immunofluorescence remains positive. This observation suggests that ELISA is also a better test in following disease activity after diagnosis and initiation of treatment.

Savige *et al* reported their finding of a higher positive predictive value if results of ELISA and immunofluorescence ANCA are combined. This was not found in our study. In fact, combining immunofluorescence and ELISA ANCA resulted in a lower positive predictive value than ELISA ANCA alone. It would be of interest to review the data Savige *et al* have used.

Based on our results, we conclude that ELISA ANCA is the principal serological test for the diagnosis of systemic necrotising vasculitis. Immunofluorescence ANCA should be avoided because its inferior specificity and poor positive predictive value open the way to incorrect or delayed diagnosis and treatment. We would like to restate the importance of recognising the different clinical syndromes caused by systemic necrotising vasculitis and of appropriate histological testing even with a positive or negative ELISA ANCA result.

We have not investigated the value of ANCA with respect to the diagnosis of other conditions, such as inflammatory bowel disease, and so we do not recommend which tests should be used in a particular laboratory. We have only compared ELISA and immunofluorescence ANCA in a particular disease (systemic necrotising vasculitis) and found ELISA to be superior by all criteria. Our results indicate that the "International consensus statement on the testing and reporting of ANCA"<sup>1</sup> should be revisited.

ANNE HARRIS  
DAVID GILLIS  
MATTHEW VADAS  
GRACE CHANG

Division of Investigational Medicine,  
Austin and Repatriation Medical Centre, Heidelberg,  
Victoria 3084, Australia

1 J Savige, D Gillis, D Davies, *et al*. International consensus statement on the testing and reporting of antineutrophil cytoplasmic antibodies (ANCA). *Am J Clin Pathol* 1999;111:507-13.

### The effect of using templates on the information included in histology reports on specimens of uterine cervix taken by loop excision of transformation zone (LETZ)

I should again like to congratulate Dr Al-Nafussi and her colleagues for providing us with an interesting and stimulating paper<sup>1</sup> and to take the opportunity to add some comments of my own. Following earlier correspondence in the journal,<sup>2,3</sup> I have sought to develop a system of standardised phrases that are used in reporting the features listed in the paper by Reid *et al*.<sup>1</sup> Secretarial or medical staff can enter a short code of up to 35 letters, which is expanded electronically to produce a phrase or sentence in coherent English. In this department, we use the Telepath system, which allows more than one such code to be used in any given report. Snomed codes are linked to the codes and automatically included in the departmental database. Furthermore, it is possible to recover reports in which a given standardised phrase or sentence has

been used. This allows us to identify the proportion of cases with specific findings such as involved specimen edges, traumatised squamocolumnar junctions, or the presence of endocervical epithelium or squamous epithelium at the end of the endocervical canal. Because these are quality features that are to some extent under the control of the colposcopist or surgeon, it is envisaged that we can then provide feedback on the adequacy of specimens deriving from particular clinics to the responsible consultants.

Finally, in addition to the ectocervical and endocervical edges we routinely comment upon the presence of CIN (cervical intraepithelial abnormality) at the deep lateral edge. This is the edge that runs between the superior, endocervical edge of the specimen to the lateral, ectocervical edge of the specimen. Although this is composed of cervical stroma with variable degrees of cautery artefact, we regard this involvement as being important because there is the potential of residual disease being covered in the re-epithelialisation process, so that it will not be detected on colposcopy or cytological surveillance. Residual disease, if undetected, has been suggested as a cause of later invasive cervical carcinoma in patients treated for CIN.<sup>4,5</sup>

S BRADBURN  
MK HEATLEY

Department of Pathology, 5th Floor, Duncan Building,  
The Royal Liverpool University Hospital,  
Prescot Street, Liverpool L7 8XB UK

- 1 Reid WA, Al-Nafussi AI, Rebello G, *et al*. Effect of using templates on the information included in histopathology reports on specimens of uterine cervix taken by loop excision of the transformation zone. *J Clin Pathol* 1999; 52:825-8.
- 2 Heatley MK. Quantitative audit of histopathology reports. *J Clin Pathol* 1994;47:1057.
- 3 Coghill SB. Quantitative audit of the content of histopathology reports. *J Clin Pathol* 1994;47: 681-2.
- 4 Anderson MC. Invasive carcinoma of the cervix following local destructive treatment for cervical intraepithelial neoplasia. *Br J Obstet Gynaecol* 1993;100:657-63.
- 5 Sevin B-U, Ford JH, Girtanner RD, *et al*. Invasive cancer of the cervix after cryosurgery—pitfalls of conservative management. *Obstet Gynecol* 1979;53:465-71.

### Some problems found in HIV-1 RNA quantification

The polymerase chain reaction (PCR) based assay of human immunodeficiency virus type 1 (HIV-1) RNA in plasma is now commercially available and is used widely for the assessment of antiretroviral treatments. The kit is called the Amplicor<sup>TM</sup> HIV-1 monitor test kit version 1.0 from Roche Diagnostics (Tokyo, Japan). However, this system is not sensitive enough for the accurate measurement of genetic subtypes A and E, and it gives falsely low titres for these virus subtypes.<sup>1,2</sup> To surmount this problem, additional gag primers (AG primers) have been provided by Roche for research use (Ver. 1.0 plus). Furthermore, a new improved version (Ver. 1.5) was developed recently, which is said to yield accurate results not only on subtype B but on subtypes A and E. With the Ver. 1.0 plus kit, adding the AG primer set from the Ver. 1.5 kit to the PCR master mixture containing the Ver. 1.0 primer set makes it possible to amplify even subtype A and E viruses. In the Ver. 1.5 kit, the downstream primer is 12 bases downstream from the Ver. 1.0 primer position, whereas the upstream primer position is unchanged but the primer has two base substitutions. In our laboratory, we have examined over 1500 samples (148 cases) using the Ver. 1.0 kit, and among

Table 1 Amplicor<sup>TM</sup> HIV-1 monitor kit

Case	Ver. 1.0	Ver. 1.0 (+)	Ver. 1.5
Case 1	$3.6 \times 10^4$	$2.7 \times 10^4$	$2.0 \times 10^4$
Case 2	$<0.4 \times 10^3$ $<0.4 \times 10^3$	$3.7 \times 10^4$ $2.1 \times 10^4$	$<0.4 \times 10^3$
Case 3	$4.2 \times 10^3$	$1.2 \times 10^4$	$9.2 \times 10^3$
Case 4	$1.7 \times 10^3$	$5.0 \times 10^4$	$3.5 \times 10^4$
Case 5	$1.6 \times 10^3$	$6.1 \times 10^4$	$3.5 \times 10^4$
Case 6	$4.6 \times 10^4$ $3.1 \times 10^4$	$<0.4 \times 10^3$ $<0.4 \times 10^3$	$0.5 \times 10^3$

Test results of each case are summarised. Measurements with Amplicor HIV-1 monitor test kits Ver. 1.0, 1.0 plus, and 1.5 were performed according to the manufacturer's protocol.

The per cent coefficient of variation on the same samples tested with the Amplicor HIV-1 monitor test kits Ver. 1.0 and 1.0 plus in our laboratory were 19.9% ( $n = 17$ ) and 31.9% ( $n = 12$ ), respectively. In cases 2 and 6 the viral load was confirmed with another independent measurement (second result).

them, 150 samples (65 cases) were also measured with the Ver. 1.0 plus kit. As expected, most cases with the HIV-1 subtypes A and E, which could not be measured with the Ver. 1.0 kit, could be measured with the Ver. 1.0 plus kit. However, we were particularly interested in a few cases that gave unexpected results. Clinically and epidemiologically, these patients are not different from our other patients infected with HIV-1 subtypes A or E. As shown in table 1, case 1 gave equivalent results with all of the kits but in cases 2 to 5 higher results were obtained with the Ver. 1.0 plus kit than with the Ver. 1.0 kit. We measured these specimens with the Ver. 1.5 kit (kindly provided by Roche Diagnostics, Japan). In these five cases, all but case 2 revealed equivalent values with both the Ver. 1.0 plus and Ver. 1.5 kits. Unexpectedly, in case 2, only the Ver. 1.0 plus kit yielded the accurate results.

On the other hand, in case 6, a higher result was obtained with the Ver. 1.0 kit but not with the Ver. 1.0 plus or Ver. 1.5 kits. An additional two cases showed a similar trend, although the degree of discrepancy was less severe (data not shown).

### Nucleotide sequences of primer region

#### Upstream primer region

SK462 primer AGTTGGAGGACATCAAGCAGCCATGCAAAAT

Consensus B ---G---G-----  
Consensus A ---G---G---C---G---T-----  
Consensus E ---G---G---C---G---A-----

Case 1 ---G---G---C---G---A-----  
Case 2 ---G---G---C---G---A-----  
Case 3 ---G---G---C---G---A-----  
Case 4 ---G---G---C---G---A-----  
Case 5 ---G---G---C---G---A-----  
Case 6 ---G---G---C---G---A-----

#### Downstream primer region

SK431 primer AGAGAACCAAGGGAACAGCATAGCA

Consensus B -----G-----  
Consensus A -----G-----  
Consensus E --G-----G-----

Case 1 --G-----G-----  
Case 2 --G-----G-----  
Case 3 --G-----G-----  
Case 4 --G-----G-----  
Case 5 --G-----G-----  
Case 6 --G-----G-----

Figure 1 The alignment of each primer region. The SK462 and SK431 primers were used in the Amplicor<sup>TM</sup> HIV-1 monitor test Ver. 1.0 kit. The sequences of these primers were obtained from Roche Diagnostics. Consensus sequences were reproduced from the HIV Sequence Database WWW home page (see text). The sequences shown in this table are from the sense strand.

To clarify the cause of these discrepant results, sequence analysis of the amplified regions of these cases was performed. The nucleotide sequences of these cases were found to be homologous to subtype A or E virus when they were aligned with the consensus sequences of HIV-1 subtypes A, B, and E obtained from the HIV Sequence Database WWW home page (Sequences. (Online.) <http://hiv-web.lbnl.gov>. 30 October 1999, last date accessed.). Surprisingly, the sequences of the primer regions of all cases were completely identical (fig 1). In conclusion, cases 2 and 6 are measurable by one of these kits, Ver. 1.0 plus and Ver. 1.0, respectively; and case 1 is measurable by all kits despite having the same nucleotide sequence in the primer regions as the other cases. The results of sequence analysis of the primer regions suggests that the minor differences in sequence between the virus and the primers does not always affect amplification efficiency in these kits. Although such cases might form a minor population among HIV-1 infections, these results indicate that some cases could not be measured by a single kit. As far as we have experienced, even if one kit fails to measure virus, the other will yield the expected viral load, as judged by disease history, CD4 count, treatment, and so on, suggesting that these kits are mutually complementary. If other methods, such as nucleic acid sequence based amplification or branched DNA (bDNA) systems, are available, it would be useful to test with them. We have found some cases of subtype A or E that have shown a higher viral load with bDNA (Chiron Quantiplex™ HIV RNA 2.0 assay Chiron Corporation, Emeryville, California, USA) than the Amplicor HIV-1 monitor test kit (data not shown). In patients infected with subtype B virus, the correlation between the Amplicor HIV-1 monitor test kit and the bDNA method was excellent ( $r = 0.904$ ;  $n = 21$ ). In conclusion, because the major difference in the three versions of the Amplicor HIV-1 monitor test kit is the primer set, we emphasise that for accurate quantitative measurement using this kit various additional primer sets that can amplify similar regions are needed.

SATORU YOSHIDA  
NOZOMI YUSA  
NORIHARU SATO

Department of Laboratory Medicine, Institute of  
Medical Science, University of Tokyo, 4-6-1,  
Shirokanedai, Minato-ku, Tokyo, 108-8639, Japan

MIEKO GOTO  
AIKICHI IWAMOTO

Department of Infectious Diseases and Applied  
Immunology, Institute of Medical Science, University of  
Tokyo

- 1 Triques K, Coste J, Perret JL, *et al.* Efficiencies of four versions of the Amplicor HIV-1 monitor test for quantification of different subtypes of human immunodeficiency virus type 1. *J Clin Microbiol* 1999;37:110-16.
- 2 Alaeus A, Lidman K, S nnerborg A, *et al.* Subtype specific problems with quantification of plasma HIV-1 RNA. *AIDS* 1997;11:859-65.

### Next of kin clinics

We read with interest the considered views of Professor Vanezis and Dr Leadbeatter regarding the role of forensic pathologists dealing with the next of kin of those people whose deaths are subject to medicolegal investigation.<sup>1</sup> It might be of interest to your readers to know that the issues raised by the authors have been dealt with at the department of forensic medicine, at Westmead in Sydney for the past decade.

The department offers a specialist grief counselling service, targeting the needs of

families attempting to come to terms with the complications of a coronial investigation at a time of crisis and great distress. The counsellors routinely contact the next of kin in all cases, discussing with them forensic and coronial procedures and outlining the counselling service, which includes individual sessions, group debriefing, and court support. The service operates with the full support of the New South Wales State Coroner, but is funded solely by the department of forensic medicine.

Professor Vanezis and Dr Leadbeatter propose the provision of "next of kin clinics", conducted by the pathologist, to discuss postmortem findings. Such a service is regularly provided at Westmead as part of the counselling unit's brief. Although thoroughly endorsing the authors' remarks on the need for accurate and timely information, we have found that several alterations need to be made to the model broadly outlined by the authors for the families to gain maximum benefit from the information sessions.

These include:

- Ongoing contact between the family and the counsellor from the time of necropsy to the receipt of its results, to ensure that the family is confident that forensic staff will be both frank and reliable in the delivery of information and support.
- A preliminary session between the family and the counsellor, to ensure that all the family's concerns are identified, thereby ensuring that the meeting with the pathologist is as comprehensive as possible.
- The presence of the counsellor at the meeting as mediator and support person for the family. Such a mediation role involves ensuring that all the family's issues are adequately considered, that the tendency some pathologists have to use jargon is kept under control, and that clarification is sought where necessary.

We have found that these alterations are necessary to ensure that the emotional needs of the family and the occasionally unavoidable power imbalance between grieving relatives and a medical specialist are properly dealt with. This latter concern can most clearly be seen in the reluctance of non-medically trained relatives to seek clarification and to admit to doubts and concerns while speaking with a representative of "the system", however well intentioned.

We have been pleased with the success of the service over many years, and self reported feedback from clients suggests both a sense of confidence in the forensic system and in coronial findings as a result. We are delighted that our colleagues in the Northern Hemisphere are finally becoming aware of the value of such a system.

JOHN DRAYTON  
PETER S J ELLIS  
TONY PURCELL

Department of Forensic Medicine, Institute of Clinical  
Pathology and Medical Research, Westmead Hospital,  
Westmead NSW 2145, Australia

- 1 Vanezis P, Leadbeatter S. Next of kin clinics: a new role for the pathologist. *J Clin Pathol* 1999;52:723-4.

### The authors reply

Drs Drayton *et al* are to be congratulated on setting up what appears to be a splendid service for relatives, and we note with interest their comments, particularly on how we could modify our work practice in the UK.

We have always been conscious of the fact that when running such clinics we have had to tread very carefully, bearing in mind the sen-

sitivities of relatives, as well as our medicolegal obligations to the investigating authorities. The system we have adopted is designed to provide information to the next of kin regarding the necropsy performed on their loved one, and to answer any concerns they might have regarding our findings. It is not designed to be a specialist grief counselling service. We have intentionally not attempted to take this approach because as pathologists we are not grief counsellors. Nevertheless, it would be extremely useful for all doctors to have some formal training in dealing with the bereaved. As you can appreciate, we have given some thought to the structure we have adopted, and what our role would be in such clinics in relation to our own situation in the west of Scotland, and obviously we would like to see the service that we provide extended to other areas in the UK. As we have stated in our paper, the service we offer at the present time, albeit limited when compared with the one offered in Australia, is nevertheless very welcome and we believe of some benefit to the next of kin.

PETER VANEZIS

Department of Forensic Medicine and Science, The  
University of Glasgow, Glasgow G12 8QQ, UK

STEPHEN LEADBEATTER

Wales Institute of Forensic Medicine,  
The Royal Infirmary, Cardiff CF2 1SZ, UK

## Correction

**Photodynamic treatment of pooled coumarin plasma for external quality assessment of the prothrombin time.** Van den Besselaar AMHP, Moor ACE. *J Clin Pathol* 2000;53:470-5.

Because of an error in the publishing process, the wrong figure was published as fig 6 in this paper. The following figure is the correct one. The journal apologises for this error.

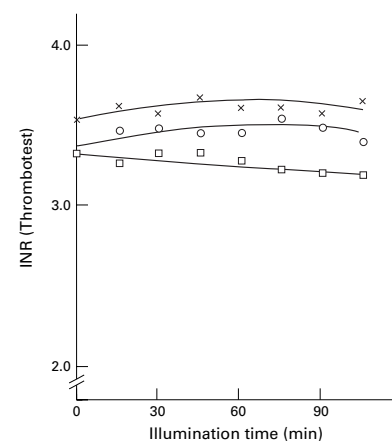


Figure 6 International normalised ratio (INR) of pooled coumarin plasma determined with bovine thromboplastin (Thrombotest) after treatment with 1 µM methylene blue and incandescent light (700 W/m<sup>2</sup>). Before illumination, either air (open circle) or nitrogen (open square) was bubbled through the plasma, or no additional treatment was given (cross).