

Familial adenomatous polyposis associated with multiple adrenal adenomas in a patient with a rare 3' APC mutation

Alex Kartheuser, Corinne Walon, Sarah West, Cor Breukel, Roger Detry, Anne-Catherine Gribomont, Tayebah Hamzehloei, Pierre Hoang, Dominique Maiter, Jacques Pringot, Jacques Rahier, P Meera Khan, Ann Curtis, John Burn, Riccardo Fodde, Christine Verellen-Dumoulin

Medical Genetics Unit, Centre for Human Genetics, Cliniques Universitaires Saint-Luc, Université Catholique de Louvain, Brussels, Belgium

A Kartheuser
C Walon
C Verellen-Dumoulin

Northern Genetics Service, Newcastle Upon Tyne, UK

S West
T Hamzehloei
A Curtis
J Burn

MGC-Department of Human Genetics, Leiden University, The Netherlands

C Breukel
P Meera Khan
R Fodde

Department of Surgery, Cliniques Universitaires

Saint-Luc, Université Catholique de Louvain, 10 Avenue Hippocrate, B-1200 Brussels, Belgium

A Kartheuser
R Detry

Abstract
Familial adenomatous polyposis (FAP) is characterised by hundreds of colorectal adenomas. Endocrine neoplasms have occasionally been reported, as have gastric polyps, which are usually hamartomatous in the fundus of the stomach and adenomatous in the antrum. A 57 year old man with colorectal, gastric, and periampullary adenomatous polyposis, in association with three bilateral adrenocortical adenomas, is presented. Mutation screening showed a 5960delA germline mutation in the adenomatous polyposis coli (APC) gene predicted to lead to a premature stop codon. This mutation was found in three of the four children of the patient. Western blot analysis of a lymphoblastoid cell line derived from the patient failed to detect any truncated APC polypeptide. This rare 3' mutation is responsible for an unusually complex and late onset phenotype of FAP. (*J Med Genet* 1999;36:65-67)

Keywords: familial adenomatous polyposis; APC mutation; adrenal adenoma

Familial adenomatous polyposis (FAP) is a dominantly inherited disease characterised by the development of hundreds of colorectal adenomas in young adults.¹ Upper gastrointestinal polyps in FAP include non-adenomatous gastric fundic gland polyps,

distal gastric adenomas, and duodenal adenomas.^{1,2} Gastric fundic polyps are usually hamartomas, which are not at risk of becoming malignant, whereas antral and duodenal polyps are adenomas and often display signs of dysplasia with a risk of subsequent carcinoma.^{1,2} Among rare extracolonic manifestations of FAP, endocrine neoplasms of the pituitary gland, pancreatic islets, and adrenal cortex have occasionally been reported.¹

Case report

Here we report a case of a 57 year old man from southern Italy who was referred for surgical treatment of complex FAP disease. His mother had died previously of colon cancer at the age of 66. This patient has three sisters and four children, who are all asymptomatic (fig 1). An upper gastrointestinal endoscopy, performed because of severe anaemia (haemoglobin 6.7 g/dl), showed multiple polyps in the

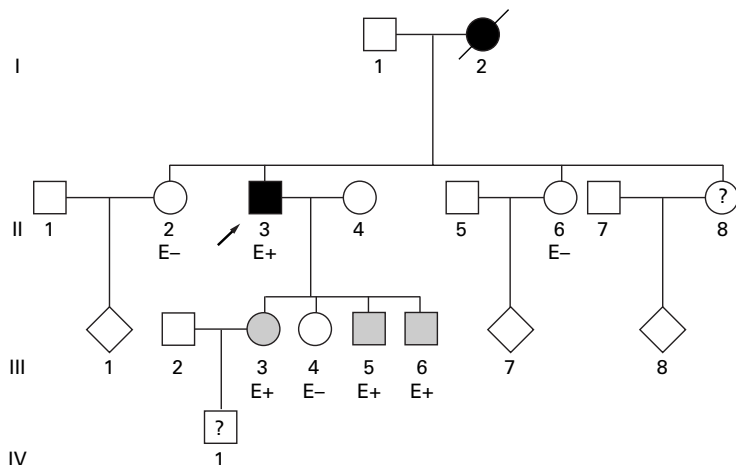


Figure 1 Family pedigree and mutation segregation. E+/-, presence or absence of the mutation; ?, not tested; arrow, proband; grey symbols represent asymptomatic carriers of the mutation.

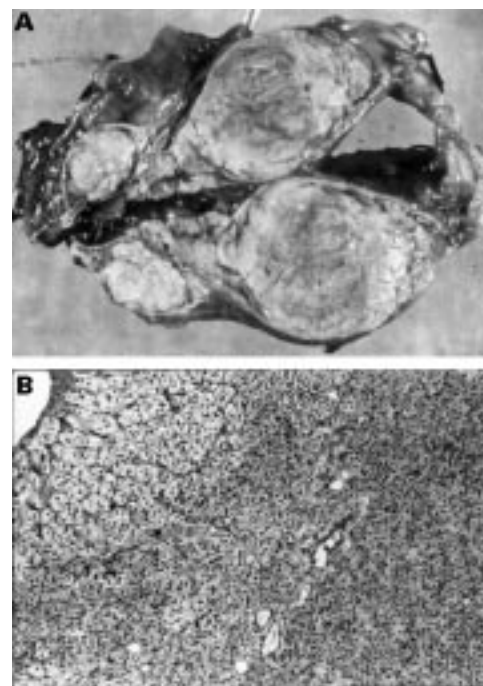


Figure 2 Pathology of adrenal masses. (A) Macroscopic appearance. The cortex of this left adrenal gland appeared slightly nodular and contained a well delimited yellowish nodule of 19 mm. (B) Microscopic appearance. The cells had an alveolar or cord-like arrangement. The tumoral nests were surrounded by fine fibrous tissue septa. Most of the cells had a clear cytoplasm rich in lipid. Their size was remarkably uniform, as were the nuclei. Signs of malignancy were absent.

Department of Ophthalmology, Cliniques Universitaires Saint-Luc, Université Catholique de Louvain, Brussels, Belgium
A-C Gribomont

Department of Internal Medicine, Cliniques Universitaires Saint-Luc, Université Catholique de Louvain, Brussels, Belgium
P Hoang
D Maïter

Department of Radiology, Cliniques Universitaires Saint-Luc, Université Catholique de Louvain, Brussels, Belgium
J Pringot

Department of Pathology, Cliniques Universitaires Saint-Luc, Université Catholique de Louvain, Brussels, Belgium
J Rahier

Correspondence to:
Dr Kartheuser

Received 3 May 1998
Revised version accepted for publication 15 June 1998

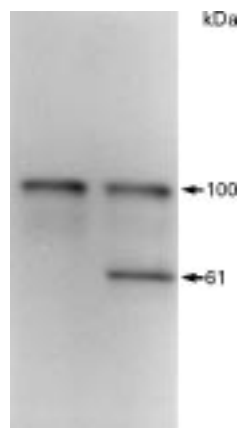


Figure 5 Protein truncation test. 14% SDS-PAGE analysis of translation product of the exon 15 segment I-Q (codons 1547-2339): *in vitro* effect of the 5960delA chain terminating mutation. The sizes of the translation products are indicated; full length product is 100 kDa for a normal subject (left lane) and the truncated product is 61 kDa for the FAP patient reported (right lane).




Figure 3 Heteroduplex analysis. Separation of PCR products of exonic fragment 15-N from a normal control (lane 3) and from two FAP patients (lanes 4 and 5). Lane 1 shows a molecular weight ladder of pBR 322 (*Msp*I). Lane 4 shows the typical heteroduplex band pattern of our patient.

stomach and a large, sessile polyp in the ampulla of Vater. Histological examination of multiple biopsies showed typical adenomas with moderate dysplasia of the duodenum and the stomach, but not the usually expected benign gastric fundic polyps. Colonoscopy showed typical colorectal polyposis with more than 100 polyps in the colon. There were only four small polyps in the rectum. A routine abdominal ultrasound (US) examination incidentally showed a hypoechogenic right adrenal mass of 2.0 cm. Adrenal masses, two on the left and one on the right, measuring 1.5, 2.3, and 2.8 cm, respectively, were also discovered on abdominal computed tomography. Endocrine evaluation of the patient excluded adrenocortical hypersecretion, pheochromocytoma, and multiple endocrine neoplasia type I. No congenital retinal pigment epithelial hypertrophy (CHRPE) could be found. Subtotal colectomy, a gastrotomy, a duodenotomy, and a left adrenalectomy were performed. Pathological examination showed more than 300 colorectal adenomatous polyps with a decreasing density from right to left. Polyps removed from the stomach were adenomatous but not benign fundic polyps; that in the duodenum was typically villous. Moderate dysplasia was found in the polyps in these three organs. Fig 2A shows the left adrenal gland and fig 2B shows the histology of the adrenal tumours.

In our patient, a typical motility shift pattern was found by heteroduplex analysis³ for exonic fragment 15-N (fig 3). DNA sequencing showed a 5960delA germline mutation in the APC gene, predicted to lead to a premature stop codon (fig 4). The presence of a stop codon in this region of the APC gene was confirmed by the protein truncation test⁴ (fig 5). Western blot analysis of a lymphoblastoid cell line derived from the proband⁵ failed to indicate the presence of a truncated APC polypeptide of the expected molecular weight (approximately 220 kDa as predicted from the chain terminating mutation) (data not shown).

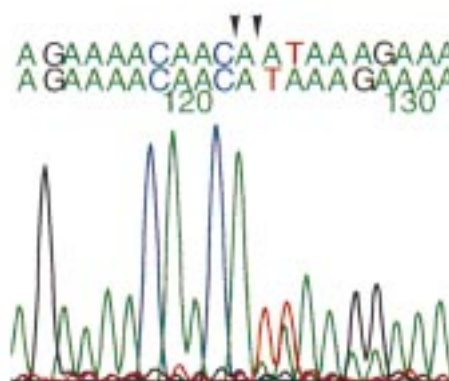


Figure 4 DNA sequencing. Direct sequencing of the 15-N mutation carried out by dye primer cycle sequencing. DNA sequence reading showed a frameshift mutation resulting from a single adenine deletion at position 5960 (codon 1981). Nucleotides are numbered according to Genebank accession number M74088 and the first codon is the first ATG initiating methionine.

Adrenal tissue was not suitable for DNA extraction to search for mutation or loss of the normal APC allele.

The other family members living in Italy were screened for the mutation and three of the four children are asymptomatic carriers (fig 1). They were advised to undergo a yearly colonoscopy, an upper GI tract endoscopy, and an abdominal US. A hyperplastic polyp was found at colonoscopy in the sigmoid colon of a 26 year old male. An adenomatous polyp of 2 cm with high grade dysplasia was removed from the sigmoid colon of a 28 year old male. A small polyp was found in the sigmoid colon of a 31 year old female.

Discussion

The mutation identified in our patient is a rare one, located at the 3' end of exon 15 of the APC gene and leading to an unusually complex and late onset phenotype. This mutation was previously reported by Scott *et al*⁶ in a pedigree from Switzerland, which could possibly share a common ancestor with our Italian patient. In the report of Scott *et al*,⁶ the patients were not assessed for adrenal tumours, although gastric polyps were found in three patients and an adenocarcinoma of the stomach in one. The location of this mutation, 5960delA (codon 1981), seems to lead to a less severe phenotype (only a few rectal polyps and late onset) but a more complex disease, involving the colon, stomach, duodenum, and both adrenal glands. Since our patient is the only member of his family who was available for investigation, further conclusions cannot be drawn about the precise phenotype associated with the present mutation.

Recently, this and other 3' mutations have been reported to lead to variable, but in general attenuated, FAP phenotypes.⁶⁻⁹ As is true for the vast majority of the APC mutations, this is a frameshift mutation predicted to result in a truncated protein product. However, as previously reported,⁷ Western blot analysis failed to show a truncated APC polypeptide of the expected length. Previous authors have postu-

lated that the instability of the corresponding mRNA or truncated protein might be responsible for the observed attenuated FAP phenotype.⁷⁻⁹

In FAP, the polyps are usually scattered fairly evenly along the entire large bowel. However, as in the present case, in over one-third of patients the density of polyps is greatest in the proximal colon and the rectum is relatively spared.¹ Colorectal adenomas usually develop in the late teens or early 20s, and in the absence of screening the age at the appearance of cancer is 39 years.¹ With respect to these various aspects of polyp distribution, number, and onset, the colorectal phenotype of our patient can be considered quite mild.

Our patient developed a true adenomatous polyposis of the whole stomach. Gastric polyps appear in 20 to 60% of cases, but these polyps are usually non-adenomatous gastric fundic gland polyps, which spare the antrum and are not at risk of becoming malignant.¹ However, gastric adenomas, solitary or multiple, involving mainly the antrum and bearing a high potential for malignant change, can also occur. In our patient, adenomas with moderate dysplasia were found in the whole body of the stomach. Whether there is an excess risk of gastric cancer in FAP is controversial; it appears to be restricted to countries in which gastric cancer is prevalent and may be influenced by environmental factors.^{1,2,10,11} In addition to the biopsies usually recommended for antral and duodenal localisation of FAP, systematic biopsies of gastric polyps should be done during upper gastrointestinal endoscopy and every adenoma should be removed.

In the general population, small, non-functioning adrenal adenomas or nodular hyperplasias are common.^{12,13} At necropsy, the adrenal glands contain grossly visible, non-functioning adenomas in about 2 to 9% of adult patients.¹³ These adrenal masses are usually single and unilateral.^{12,13} To date, 13 cases of non-functioning adrenal adenomas,¹ one case of pheochromocytoma,¹⁴ and three cases of adrenocortical carcinoma¹⁵⁻¹⁷ have been reported in association with FAP syndrome. It is difficult to know whether these associations are coincidental, but the fact that in our patient the adrenal masses are multiple and bilateral strongly suggests an underlying genetic cause. Because of the report of at least three cases presenting with a primary adrenal carcinoma, the malignant potential of adenomas should be taken into consideration in the management of patients with FAP. Any family with FAP resulting from a mutation at the 3' end of exon 15 of the APC gene should be offered abdominal ultrasound examination.

Regarding the relation between CHRPE and the location of the mutation in the APC gene, the existence of phenotypic boundaries has been proposed; mutations occurring 5' to exon 9 or beyond codon 1444 seem not to be associated with CHRPE.¹⁸ This is in accordance with our patient bearing a mutation at codon 1982

without any evidence of CHRPE on ophthalmological examination.

In conclusion, we report a patient with a rare APC mutation leading to an unstable truncated polypeptide which was responsible for an unusually complex, late onset FAP phenotype. A better genotype-phenotype correlation would be very helpful in the search for extracolonic manifestations of FAP, which become increasingly important because of their influence on the survival of patients after prophylactic colectomy. In the light of this case, we recommend systematic biopsies of gastric polyps during upper gastrointestinal endoscopy. Furthermore, to evaluate the effect of 3' APC mutations on the adrenal glands, an abdominal ultrasound examination should be performed in FAP patients carrying this type of mutation.

Grant support: CAPP Study, The Fondation St-Luc, Brussels, Belgium, Fonds de la Recherche Scientifique Médicale, Belgium (FRSM), Fonds de Développement Scientifique UCL (FDS), Dutch Royal Academy of Sciences (KNAW), Dutch Cancer Society.

- Phillips RKS, Spigelman AD, Thomson JP. *Familial adenomatous polyposis and other polyposis syndromes*. London: Edward Arnold, 1994.
- Spigelman AD, Talbot IC, Williams CB, Domizio P, Phillips RKS. Upper gastrointestinal cancer in patients with familial adenomatous polyposis. *Lancet* 1989;ii:783-5.
- Hamzehloei T, West SP, Chapman PD, Burn J, Curtis A. Four novel germ-line mutations in the APC gene detected by heteroduplex analysis. *Hum Mol Genet* 1993;3:1023-4.
- Prosser J, Condie A, Wright M, et al. APC mutation analysis by chemical cleavage of mismatch and a protein truncation assay in familial adenomatous polyposis. *Br J Cancer* 1994;70:841-6.
- Smith KJ, Johnson KA, Bryan TM, et al. The APC gene product in normal and tumor cells. *Proc Natl Acad Sci USA* 1993;90:2846-50.
- Scott RJ, van der Luijt R, Spycher M, et al. Novel germline APC gene mutation in a large familial adenomatous polyposis kindred displaying variable phenotypes. *Gut* 1995;36:731-6.
- van der Luijt RB, Meera Khan P, Vasen HFA, et al. Germ-line mutations in the 3' part of APC exon 15 do not result in truncated proteins and are associated with attenuated adenomatous polyposis coli. *Hum Genet* 1996;98:727-34.
- Caspari R, Olschwang S, Friedl W, et al. Familial adenomatous polyposis: desmoid tumours and lack of ophthalmic lesions (CHRPE) associated with APC mutations beyond codon 1444. *Hum Mol Genet* 1995;4:337-40.
- Eccles DM, van der Luijt RB, Breukel C, et al. Hereditary desmoid disease due to a frameshift mutation at codon 1924 of the APC gene. *Am J Hum Genet* 1996;59:1193-201.
- Jagelman DG, Decosse JJ, Bussey HJR, and The Leeds Castle Polyposis Group. Upper gastrointestinal cancer in familial adenomatous polyposis. *Lancet* 1988;i:1149-51.
- Offerhaus GJA, Giardiello FM, Krush AJ, et al. The risk of upper gastrointestinal cancer in familial adenomatous polyposis. *Gastroenterology* 1992;102:1980-2.
- Glazer HS, Weyman PJ, Sagel SG, Levitt RG, McClellan BC. Nonfunctioning adrenal masses: incidental discovery on computed tomography. *AJR* 1982;139:81-5.
- Abecassis M, McLoughlin MJ, Langer B, Kudlow JE. Serendipitous adrenal masses: prevalence, significance and management. *Am J Surg* 1985;149:783-8.
- Perkins JT, Blackstone MO, Riddell RH. Adenomatous polyposis coli and multiple endocrine neoplasia type 2b. A pathogenetic relationship. *Cancer* 1985;55:375-81.
- Painter TA, Jagelman DG. Adrenal adenomas and adrenal carcinomas in association with hereditary adenomatosis of the colon and rectum. *Cancer* 1985;55:2001-4.
- Marshall WH, Martin HR, MacKay IR. Gardner's syndrome with adrenal carcinoma. *Aust Ann Med* 1967;16:242-4.
- Seki M, Tanaka K, Kikuchi-Yanoshita R, et al. Loss of normal allele of the APC gene in an adrenocortical carcinoma from a patient with familial adenomatous polyposis. *Hum Genet* 1992;89:298-300.
- Olschwang S, Turet A, Laurent-Puig P, Muleris M, Parc R, Thomas G. Restriction of ocular fundus lesions to a specific subgroup of APC mutations in adenomatous polyposis coli patients. *Cell* 1993;75:959-68.