Simultaneous occurrence of two supernumerary autosomal ring chromosomes r(1) and r(16) in twins

Alan L Shanske, Patricia Dowling, Rina Schmidt, Beverly J White, Barbara Russell, Anna Bogdanow, Robert W Marion

Abstract

Ring chromosomes are estimated to occur in 3/10 000 newborns and the simultaneous occurrence of two autosomal rings must be a very rare event. Recently, the characterisation of these markers using fluorescence in situ hybridisation (FISH) has greatly enhanced cytogenetic-phenotypic correlations in patients with these marker chromosomes. This kind of analysis enabled us to clarify a unique karyotype containing a r(1) and a r(16) in identical twins born after a 26 week gestation with minimal somatic abnormalities. The origin of the rings was identified using α satellite and whole chromosome painting probes. FISH analysis showed the same abnormal female karyotype in both twins, 48,XX,+r(1)(p13q21),+r(16)(p11q11).ish r(1)(D1Z5+,wcp1+), r(16)(D16Z2+,wcp16+) in about two thirds of the cells. Each also had minor clones with a normal female karyotype or with one or the other supernumerary ring. Half of the r(1) contained CBG band negative material and the r(16) appeared to be totally CBG band positive. These twins represent the second report of the simultaneous occurrence of multiple autosomal rings. Their description may help to delineate a new chromosome disorder and shows the usefulness of FISH analysis.

(*J Med Genet* 1999;**36**:625–628)

Keywords: ring chromosome 1; ring chromosome 16; marker chromosomes; whole chromosome painting probes

Center for Congenital Disorders, Department of Pediatrics, Montefiore Medical Center/Albert Einstein College of Medicine, NW556, 111 East 210th Street, Bronx, New York 10467, USA
A L Shanske
A Bogdanow
R W Marion

Division of Neonatology, Department of Pediatrics, Montefiore Medical Center/Albert Einstein College of Medicine, Bronx, New York, USA
B Russell

Quest Diagnostics, Teterboro, New Jersey, USA
P Dowling
R Schmidt
B J White

Correspondence to: Dr Shanske.

Received 3 July 1998 Revised version accepted for publication 2 March 1999

The frequency of supernumerary marker chromosomes in humans is estimated to be 0.2-1.5/1000 pregnancies studied for prenatal diagnosis,[1 2] 3/10 000 newborns,[3] and about 40% of these are familial. Ring chromosomes represent a small percentage of these with a frequency of 1 in 25 000 conceptions.[4] The occurrence of two different rings in the same person has only been reported once.[5] The clinical significance of all markers is the potential risk for physical abnormality or mental retardation. Prospective studies of such markers probably reflect their true incidence and indicate that markers derived from the acrocentrics are the most common. The majority do not have a deleterious effect on the phenotype.[6] Many researchers have used α repeat centromeric probes to characterise marker and ring chromosomes. Markers have been found originating from all chromosomes, except from chromosomes 5, 7, 10, and 17. Distinct syndromes are associated with the occurrence of markers containing material from 12p, 18p, and 22q11.[6] Reports of ring chromosome 1 are rare.[7] Similarly, there have been only eight reports of ring chromosome 16.[8–15] We have recently had the opportunity to evaluate monozygotic twins with supernumerary ring chromosome 1 and ring chromosome 16 mosaicism.

Case reports

Twin A was the 672 g first born female product of a twin gestation delivered spontaneously to a 26 year old, gravida 2, para 1001 mother at 25/26 weeks. The Apgar scores were 5 and 7 and she required intubation for resuscitation. Examination of the fetal membranes showed a single chorion and two amniotic sacs.The newborn examination showed no dysmorphic features. She remained intubated for a total of 58 days and required pressor agents. During her four month stay in the neonatal ICU, she was treated for necrotising enterocolitis, staphylococcal sepsis, apnoea of prematurity, hyperbilirubinaemia, and nutritional rickets. She was observed to have a grade II intraventricular haemorrhage and stage III, zone III retinopathy of prematurity. Hepatomegaly noted shortly before discharge at 4 months of age was felt to be on CT scan consistent with a large haemangioma. She was readmitted along with her twin 11 days after discharge because of increasing respiratory distress secondary to a viral syndrome and remained an additional two months primarily for respiratory therapy (fig 1). She was discharged to a long care facility because of her continued increased oxygen requirement. Her physical examination at 23 months showed microcephaly, growth and developmental delays, and mild dysmorphic facial features including hypertelorism, flat nasal bridge, and epicanthic folds. A number of strawberry haemangiomas were resolving. Her head circumference was 45 cm (<2nd centile). She was able to walk and produce two words and no longer required supplemental oxygen. Radiographs showed no skeletal anomalies.

Twin B was the 632 g twin of case 1. She too was delivered spontaneously and had an Apgar score of 5 and 7. The newborn examination showed a right bifid thumb and no other abnormalities. Overall, she had a much more benign course in the hospital and was discharged after three months. She was intubated for a total of 28 days and was weaned to room

air by day 67. During her hospital stay, she was treated for hyperbilirubinaemia, apnoea of prematurity, staphylococcal sepsis, candidal sepsis, and nutritional rickets. She was observed to have grade II bilateral intraventricular haemorrhages and stage I, zone III retinopathy of prematurity. A skeletal survey showed hemivertebrae at T2 and T3 with focal scoliosis and fusion of the second and third ribs. She was readmitted at 4 months of age on the same day as her sister also for respiratory distress with apnoea and cyanosis after a two week history of an upper respiratory infection (fig 1). She remained in the hospital for an additional two months for respiratory therapy and was discharged along with her sister to a long term care facility where she is now followed in the outpatient department and continues to require supplemental oxygen via nasal cannula. Her physical examination at 23 months showed a growth retarded, microcephalic infant with a bifid right thumb and a left inguinal hernia. The head circumference was 43.5 cm (4 SD below the mean) and the metopic suture was prominent. She was able to walk and babble and still required supplemental oxygen at night. A CT scan of the head showed normal parenchyma and a normal ventricular system but closure of the metopic suture and the inferior portion of the coronal sutures.

Materials and methods

Cytogenetic analysis was performed on peripheral blood cells from the twins and their parents and from fibroblast cultures from both twins. Cultures were established and harvested according to standard cytogenetic techniques. A modified GTG banding technique was performed according to the method of Seabright.[16] CBG banding was done by a modified method of Sumner.[17] Slides were incubated using digoxigenin labelled α satellite probes for the entire chromosome set and whole chromosome painting probes for chromosomes 1 and 16 (ONCOR). Probe detection and signal amplification were done by using FITC labelled antidigoxigenin and counterstaining with propidium iodide (ONCOR). The ring chromosomes were identified by performing a sequential fluorescence in situ hybridisation (FISH) procedure, using probes for the centromere regions of all chromosomes. In the first round of analysis, three probes were mixed and applied to a single slide (eight slides in total), as follows: 1/5/19 (one probe); 2, 3, 4; 6 ,7 , 8; 9, 10, 11; 12, 13/21 (two probes); 14/22, 15 (two probes); 16, 17, 18; 20, X, Y. The slides were examined for the presence of an additional small signal corresponding to the ring chromosome. Once the group containing the extra slide was identified, each probe within that group was applied singly to each of three slides.

Results

Analysis of GTG banded metaphase chromosomes from the twins showed an abnormal female complement containing two supernumerary ring chromosomes, 48,XX,+r(1),+r(2), in the majority of cells from both twins (fig 2). The larger ring, r(1), and the smaller, r(2), were distinct from one another by size and heterochromatin. Their frequencies could be determined based on the G band analysis of 50 cells from each culture. The karyotype of twin A was 48,XX,+r(1),+r(2) [35]/47,XX,+r(1) [7]/47, XX,+ r2 [8], and that of twin B was 48,XX,+r(1),+r(2) [33]/47,XX,+r(1) [12]/ 47,XX,+r(2) [3]/46,XX [2] (fig 3). A somewhat

Figure 1 (A) Photograph of twin A at 5 months of age showing mildly dysmorphic appearance and (B) twin B at 5 months of age showing trigonocephaly owing to closure of the metopic and coronal sutures. (Photographs reproduced with permission.)

different distribution was found in a fibroblast culture from the second twin (30%, 4%, and 54%). A normal complement was found in an additional 12%. The skin biopsy from the first twin resulted in no growth. The origin of the rings could not be determined from the GTG banded karyotype. The parents' karyotypes were normal.

The origin of the markers was established by hybridisation with α satellite probes which showed the large ring to be derived from chromosome 1 (D1Z5) and the small ring to be chromosome 16 material (D16Z2) (figs 4 and 5). Whole chromosome painting probes confirmed the origin of the rings. Approximately one half of the large ring showed decreased signal confirming the size of the centromeric material. Whole chromosome painting probe 16 showed a weak but positive signal indicating that it consists mostly of heterochromatic material. CBG banding indicated that about one half of ring chromosome 1 consisted of C band positive material. This corresponded to the GTG band positive region of the ring. Ring chromosome 16 appeared to be totally CBG band positive. The parental origin of the ring chromosomes could not be identified based upon the above morphological characteristics. The karyotype of the twins based upon our analysis was interpreted as 48,XX,+r(1)(p13q21),+r(16)(p11q11).ish r(1)(D1Z5+,wcp1+), r(16)(D16Z2+,wcp16+). As a result of ring instability, random loss, or positive or negative selection, both twins are mosaics with at least 65% of the cells containing both rings. No fragments, double or multiple rings, polycentric rings, or other indications of ring instability were observed.

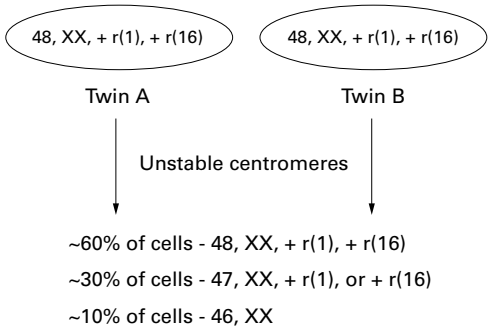

Figure 3 Mosaicism resulting from ring instability observed in both twins.

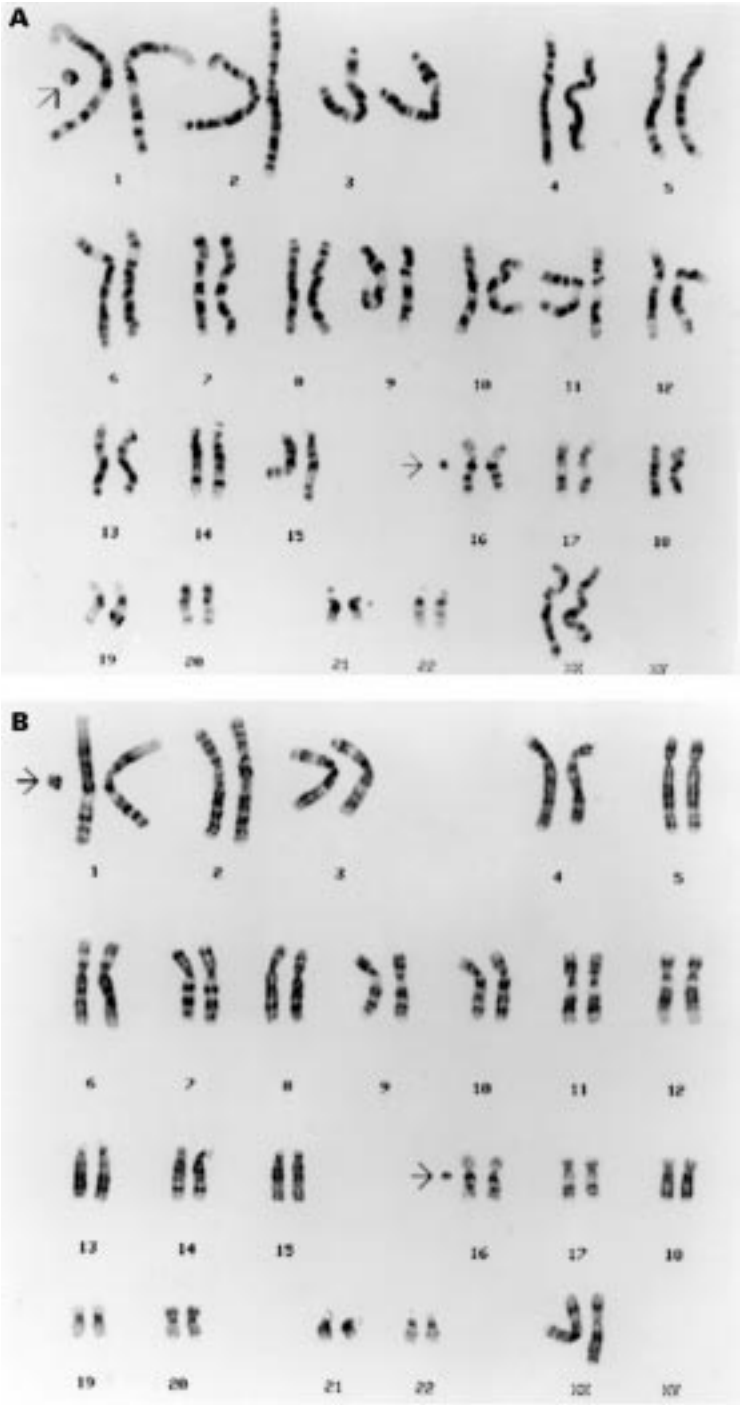

Figure 2 GTG banded karyotypes of (A) twin A and (B) twin B.

Discussion

The presence of even a single de novo marker chromosome presents great difficulty in genetic counselling concerning prognosis. Delineation of the origin of supernumerary chromosomes results in improved karyotype-phenotype correlations. The presence of the two rings in our patients to the best of our knowledge has never been reported before and represents a special clinical challenge. There have been only five published supernumerary r(1) cases.[7] Of these, one contained only heterochromatin and one occurred in the presence of a del(18). Phenotypic comparisons are difficult because of differences in the size of the ring and the tissue distribution of the mosaicism. However, all three of the phenotypically abnormal patients with a supernumerary r(1) had developmental delay and abnormal pinnae. Two of the three also had growth retardation, microcephaly, oblique palpebral fissures, and clinodactyly. There have been eight reports of a supernumerary r(16).[8–15]

Ring chromosomes arise from chromosome breaks occurring on either side of the centromere with subsequent rejoining of the broken ends of the segment containing the centromere. We postulate two mechanisms of ring formation in our twins. The first involves mitotic non-disjunction after zygote formation,

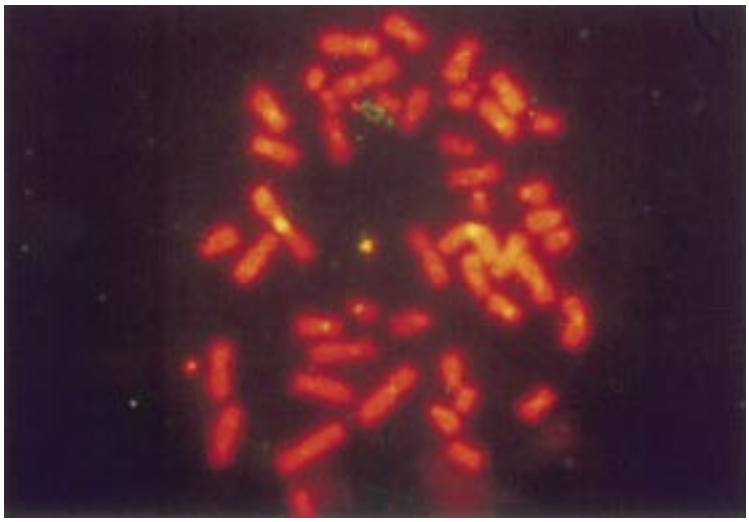

Figure 4 Metaphase from twin A stained with FITC labelled α satellite probe for chromosome 1 showing three signals including r(1).

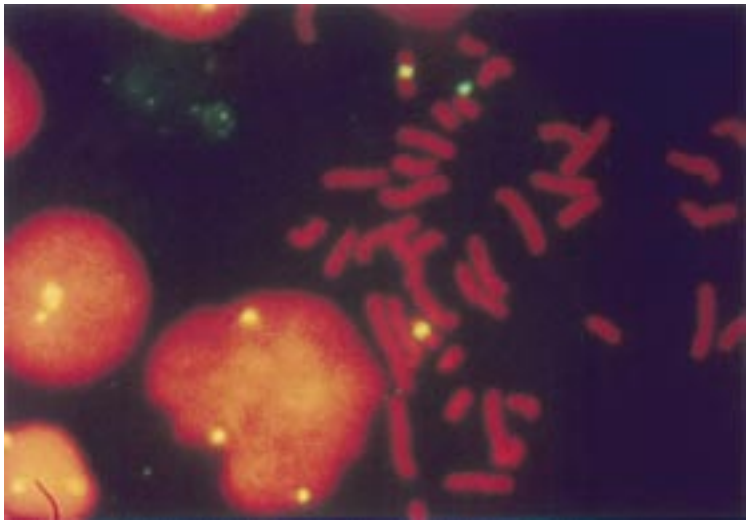

Figure 5 Metaphase from twin A stained with FITC labelled α satellite probe for chromosome 16 showing three signals including r(16).

with subsequent ring formation followed by twinning. Most patients with rings have mosaicism because of instability during cell division. In the case of our twins, loss of a ring during cell division could not have occurred until after twinning because the presence of both rings in the twins strongly suggests that they are monozygotic. Alternatively, ring formation may have occurred as a result of germline mosaicism in one or both parents, a far less likely mechanism, in which case the twins would not be monozygotic.

The presence in our patients of supernumerary rings results in partial trisomy for segments of chromosome 1. We feel our analysis shows only heterochromatin on r(16). Our cases do not resemble the phenotypic descriptions of other patients with supernumerary r(1) and are in fact discordant themselves. The difficulty in delineating a supernumerary r(1) syndrome is complicated by the rarity of case reports, the differences in breakpoints, and the variability in the degree of mosaicism. In fact, the variability in the degree of mosaicism observed between peripheral blood and fibroblasts in the second twin may explain the differences in the phenotypes of the twins. The twins exhibit some of the non-specific phenotypic changes, such as microcephaly and growth and developmental retardation, observed in patients with the ring chromosome syndrome described by Kosztolanyi *et al*.[18] These changes occur regardless of the chromosome involved and even when there is no apparent loss of chromosome material. Finally, it has also been suggested that subjects with supernumerary marker chromosomes might have an increased risk for uniparental disomy for the normal homologues of the ring chromosome and that this too might be a mechanism for somatic changes in patients with ring chromosomes. In fact, paternal isodisomy of chromosome 6 has been reported.[19]

In the future, additional investigations in the twins involving studies in other tissues, gene dosage effects, zygosity, and CA repeat polymorphisms will further clarify the clinical significance of this unique chromosome complement.

1 Hsu LYF. Prenatal diagnosis of chromosome abnormalities. In: Milunsky A, ed. *Genetic disorders and the fetus. Diagnosis, prevention and treatment.* New York: Plenum Press, 1986.
2 Sachs ES, Van Hemel JO, Den Hollander JC, Jahoda MGJ. Marker chromosomes in a series of 10,000 prenatal diagnoses. Cytogenetic and followup studies. *Prenat Diagn* 1987;7:81-9.
3 Jacobs PA. The role of chromosome abnormalities in reproductive failure. *Reprod Nutr Dev* 1990;**1**(suppl):63-74s.
4 Jacobs PA. Mutation rates of structural chromosome rearrangements in man. *Am J Hum Genet* 1981;**33**:44-54.
5 Mackie-Ogilvie C, Waddle K, Mandeville J, Seller MJ, Docherty Z. Rapid identification of multiple supernumerary ring chromosomes with a new FISH technique. *J Med Genet* 1997;**34**:912-16.
6 Gravholt CH, Friedrich U. Molecular cytogenetic study of supernumerary marker chromosomes in an unselected group of children. *Am J Med Genet* 1995;**56**:106-11.
7 Chen H, Tuck-Muller CM, Batista AS, Wertelecki W. Identification of supernumerary ring chromosome 1 mosaicism using fluorescent in situ hybridization. *Am J Med Genet* 1995;**56**:219-23.
8 Pergament E, Pietra GC, Kadtani T, Sato H, Berlow S. A ring chromosome No 16 in an infant with primary hypoparathyroidism. *J Pediatr* 1970;**76**:745-51.
9 Neidengard L, Sparkes RS. Ring chromosome 16. *Hum Genet* 1981;**59**:175-7.
10 Quintana A, Sordo MT, Estevez C, Ludena MC, San Marino C. 16 ring chromosome. *Clin Genet* 1983;**23**:243.
11 Krauss CM, Caldwell D, Atkins L. Interstitial deletion and ring chromosome derived from 16q. *J Med Genet* 1987;**24**: 308-12.
12 Chodirker BN, Ray M, McAlpine PJ, *et al*. Developmental delay, short stature, and minor facial anomalies in a child with ring chromosome 16. *Am J Med Genet* 1988;**31**:145-51.
13 Vianello MG, Cottafava F, Bartoli D, Franzone G, Casazzava R, Gastaldi R. Ring chromosome 16: a new case. *Ann Genet* 1990;**33**:36-9.
14 Callen DF, Ringenbergs ML, Fowler JCS, Freemantle CJ, Haan EA. Small marker chromosomes in man: origin from pericentric heterochromatin of chromosomes 1, 9, and 16. *J Med Genet* 1990;**27**:155-9.
15 Conte RA, Kleyman SM, Kharode C, Verma RS. Delineation of a ring chromosome 16 by the FISH-technique: a case report with review. *Clin Genet* 1997;**51**:196-9.
16 Seabright M. A rapid banding technique for human chromosomes. *Lancet* 1971;**ii**:971-2.
17 Sumner AT. A simple technique for demonstrating centromeric heterochromatin. *Exp Cell Res* 1972;**75**:304-6.
18 Kosztolanyi G. Does "ring syndrome" exist? An analysis of 207 case reports on patients with a ring autosome. *Hum Genet* 1987;**75**:174-9.
19 James RS, Temple IK, Dennis NR, Crolla JA. A search for uniparental disomy in carriers of supernumerary marker chromosomes. *Eur J Hum Genet* 1995;**3**:21-6.