

# The importance of skip lesions in temporal arteritis

D N Poller, Q van Wyk, M J Jeffrey

## Abstract

**Aim**—To determine the frequency of skip lesions in an unselected series of temporal artery biopsies and compare the results with other series.

**Methods**—The study was a retrospective review of 102 consecutive temporal artery biopsies taken in a five year period (1992–1997) in one large hospital.

**Results**—35 cases (34.3%) showed evidence of active cranial vasculitis with pathological evidence of inflammation of the intima or media, with or without giant cells. Three of these cases (8.5%) showed apparent skip lesions: normal intima, media, and adventitia in one segment while in other segments there was clear evidence of active vasculitis. Immunocytochemical stains for leucocyte common antigen (LCA) and CD15 were helpful in identifying the absence of intimal or medial inflammatory cell infiltrates within skip lesions. Skip lesions have been described in up to 28.3% of cases in some series, while others have not found evidence of skip lesions or have identified them in a much smaller percentage of cases.

**Conclusions**—In this series skip lesions were relatively rare, accounting for 8.5% of cases of active vasculitis. The degree of inflammation in temporal arteritis is discontinuous. Immunostaining for inflammatory cells, for example LCA and CD15, may be helpful in identifying the presence of an inflammatory cell infiltrate in skip lesion segments of the temporal artery.

(J Clin Pathol 2000;53:137–139)

Keywords: temporal arteritis; inflammation; skip lesion; immunohistochemistry

Temporal arteritis is a syndrome characterised by some or all of the following features: age 50 years or more, new onset of localised headache, temporal artery tenderness or decreased temporal artery pulse, raised erythrocyte sedimentation rate (ESR), and biopsy showing evidence of active arteritis characterised by mononuclear cell infiltrates or a granulomatous process with multinucleated giant cells.<sup>1</sup> Temporal arteritis is a relatively rare condition although the clinical sequelae, particularly unilateral blindness or cerebral infarction, require prompt diagnosis and urgent corticosteroid treatment in cases of active disease. The predictive value of a negative temporal artery biopsy has been questioned, although the presence of three diagnostic criteria is associated with a sensitivity of 93.5% and a diagnostic

specificity of 91.2%.<sup>1</sup> While temporal artery biopsy is one of the main diagnostic procedures in temporal arteritis there are differences in the published rates of apparent segmental inflammation, so called skip lesions. In their Mayo Clinic series, Klein *et al* reported evidence of segmental inflammation in up to 28.3% of all cases.<sup>2</sup> Other investigators have reported so called skip lesions in a lower proportion of cases, and some have failed to demonstrate their presence at all.<sup>3</sup> The object of this study was to determine the frequency of skip lesions in an unselected series of temporal artery biopsies accrued over a five year period and then to compare our own results with those of others.

## Methods

### PATIENTS

We carried out a retrospective review of 102 sequential cases of temporal artery biopsy taken in one centre (Portsmouth Acute Hospitals NHS Trust) in the period 1992–1997. All the archival slides from these 102 cases were retrieved and were reviewed blind by either DNP or QvW, without knowledge of clinical information or the previous pathology report. In cases of doubt or diagnostic difficulty a consensus diagnosis was reached, after simultaneous review of slides from the case in question by both pathologists.

In our hospital it is customary to perform only one (unilateral) temporal artery biopsy. The majority of specimens are sent for examination by the ophthalmology unit. After receipt in the laboratory, each segment of artery is divided at 3–4 mm intervals, then embedded in a tissue cassette and processed for histological examination through alcohol/water mixtures, then tissue processing solution into paraffin wax. Haematoxylin and eosin (H&E) stained sections 4 µm thick are cut from the blocks, followed by three additional sets of deeper cut H&E stained sections cut onto three additional slides, with a stain for collagen and elastin (elastic van Gieson) also performed on each of the three levels. The length of the temporal artery specimen was at least 6 mm in all the cases included in the series. For the purposes of this study, two categories of vasculitis were recognised: classic giant cell or granulomatous arteritis and atypical or non-granulomatous arteritis.<sup>1</sup> For a diagnosis of active vasculitis, the presence of either acute inflammatory cells within the intima or media of any vessel segment from a given case was required, together with at least some damage to, or destruction of, the internal elastic lamina.<sup>4</sup> The definition of a skip lesion was that as described by Klein *et al*<sup>2</sup>—that is, one or

Department of Pathology, Queen Alexandra Hospital, Cosham, Portsmouth PO6 3LY, UK  
D N Poller  
Q van Wyk  
M J Jeffrey

Correspondence to:  
Dr Poller  
email david@poller.demon.co.uk

Accepted for publication  
24 August 1999

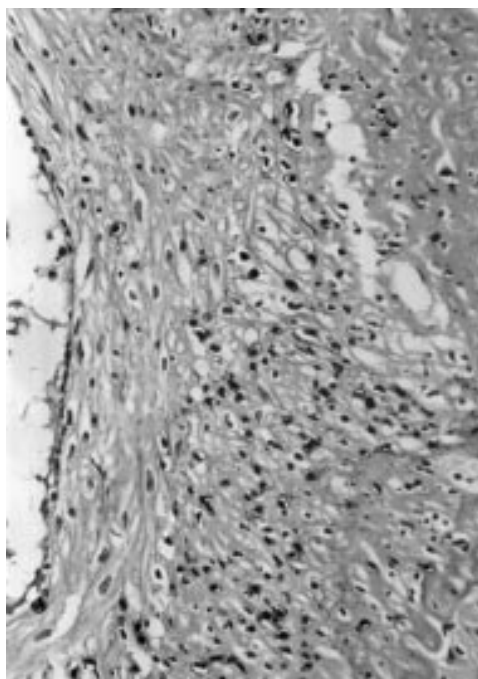


Figure 1 Segment of vessel wall showing active inflammation. Haematoxylin and eosin stain.

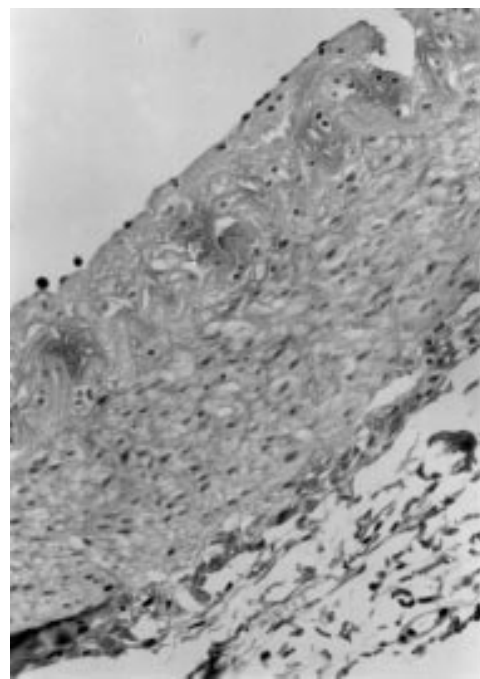


Figure 2 Segment of vessel wall from the same biopsy specimen showing no evidence of mural inflammation (skip lesion). Haematoxylin and eosin stain.

more sections of a temporal artery with appearances of typical arteritis while other sections from the same artery had none of the characteristic features of arteritis. The presence or absence of granulomatous inflammation, intimal thickening, or reduplication/destruction of the internal elastic lamina were separately recorded in each case. In the three cases where skip lesions were identified, stains for LCA and CD 15 were performed to demonstrate the presence of lymphoid cells (LCA) or neutrophilic inflammation (CD15) within the vessel wall in affected skip segments. In this study cases were only designated as positive for vasculitis if acute inflammatory cells were present within the intima or media of any segment. The specimen was designated as negative for vasculitis if no evidence of inflammatory cells was identifiable in the vessel wall in any of the segments examined.

#### IMMUNOHISTOCHEMISTRY

Sections were cut from archival blocks of formalin fixed paraffin embedded tissue at 4–6  $\mu\text{m}$ . After rehydration through xylene and graded alcohol/water mixtures sections were rinsed in Tris-buffered saline at pH 7.4. Antigen retrieval was performed by heating in a steam pressure cooker for two minutes followed by incubation of sections in 3% hydrogen peroxide in distilled water for five minutes. The slides were then rinsed with distilled water and placed in Tris buffered saline for a further five minutes. Endogenous binding sites were blocked with normal goat serum for 30 minutes. For CD15, incubation with C3D1 primary antibody at 1:50 dilution was performed (Dako); for leucocyte common antigen (LCA) a mixture of two monoclonal antibodies 2B11 and PD7/26 (Dako) at 1:200 dilution was used. Sections were then rinsed with Tris

buffered saline, and bathed in Tris buffered saline for a further five minutes, followed by incubation with polyspecific antimouse, anti-rabbit biotinylated goat antibody (Dako, StreptABC complex HRP duet) for 20–30 minutes. The sections were again rinsed in Tris buffered saline, incubated with streptavidin-biotin complex/horse radish peroxidase solution for 20 minutes, then rinsed in Tris buffered saline with diaminobenzidine as a chromogen, followed by rinsing with distilled water. The slides were counterstained with haematoxylin. Human tonsillar tissue was used as a positive control for both CD15 and LCA staining. A negative control was performed with both antibodies, with omission of the primary antibody step in each batch of LCA or CD15 staining.

#### Results

Thirty five of the 102 cases evaluated (34%) showed evidence of active arteritis according to the criteria of the American College of Rheumatology<sup>1</sup> (fig 1).

Three of 35 active arteritis cases (8.5%) showed skip lesions on H&E staining (fig 2), with at least one transverse histological section from a given case showing normal intima, media, and adventitia; other segments from these cases showed unequivocal active vasculitis (table 1).

Table 1 Presence of skip lesions or granulomatous inflammation in cases showing evidence of active vasculitis

|                 | Inflammation<br>with granulomas | Inflammation<br>without granulomas | Total |
|-----------------|---------------------------------|------------------------------------|-------|
| Skip lesions    | 2                               | 1                                  | 3     |
| No skip lesions | 27                              | 5                                  | 32    |
| Total           | 29                              | 6                                  | 35    |

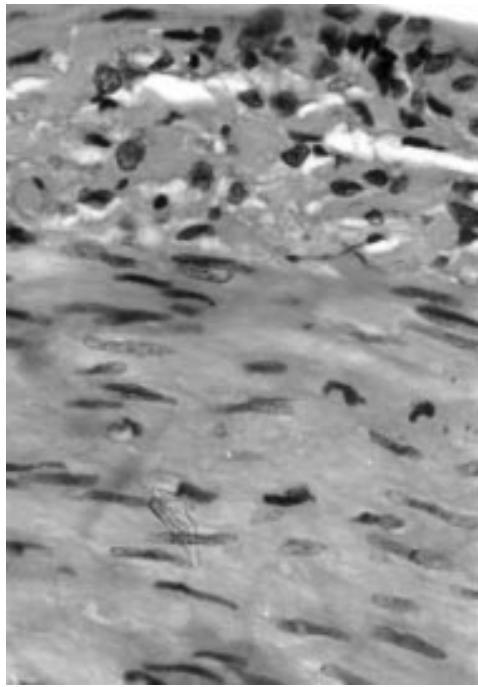


Figure 3 Photomicrograph of leucocyte common antigen (LCA) stain of inflammatory cells in the adventitia of the same vessel wall as in figs 1 and 2, not readily apparent on H&E but confirmed on LCA staining

Two of the skip lesion cases showed evidence of granulomatous inflammation and one showed evidence of active inflammation without granulomata. Evidence of intimal thickening and reduplication of the internal elastic lamina was also identified in many other cases classified as normal that showed no evidence of active vasculitis (that is, the absence of acute inflammatory cells or lymphoid cells within the vessel wall). The three cases showing evidence of skip lesions each showed at least one segment where no acute inflammatory cells or lymphoid cells were readily identifiable in the intima or media on H&E staining but the adjacent segments of vessel showed typical features of active inflammation. Additional immunocytochemical stains for LCA and CD15 proved helpful in identifying the absence of intimal or medial inflammatory cell infiltrates within skip lesions, as lymphocytes and polymorphs were not seen within the intima and media of the skip lesion segments (fig 3), but were confirmed in the intima and media of adjacent segments showing active vasculitis.

### Discussion

The importance of temporal artery biopsy in the diagnosis of temporal arteritis is beyond doubt, as exemplified by its inclusion in the American College of Rheumatology criteria for diagnosis of temporal arteritis.<sup>1</sup> The practice of bilateral temporal artery biopsy has been advocated by some, as in the Mayo Clinic series,<sup>2</sup> given that skip lesions (foci of discontinuous vasculitis) may occur in around one third of cases. Our own study, although small, suggests

that foci of discontinuous inflammation occur in around 10% of cases.

In this series no attempt was made to correlate the microscopic findings with clinical presentation or follow up as this was a retrospective study.

While the identification of a scattering of adventitial inflammatory cells on LCA and CD15 staining within skip lesions is non-specific and may be seen in atheromatous disease of the temporal artery, the absence of inflammatory cells within the intima or media confirms the H&E appearances of a skip lesion. As it is the practice in our laboratory to take a substantial portion of temporal artery at least 6–7 mm in length, we do not consider that inadequate length of arterial wall is likely to have been a significant factor in our study,<sup>5</sup> particularly as the proportion of positive biopsies is not dissimilar to that reported in other series.<sup>6</sup> The lessons from this study are first, that skip lesions are relatively rare in temporal arteritis; second, that the identification of skip lesions does not require multiple levels to be examined from the temporal artery biopsy specimen, as skip lesions, if present, should be apparent on examination of one set of sections from each segment of temporal artery within the tissue cassette; and third, that giant cell change may be present in cases of skip lesions, although the numbers of cases were too small in this series to make valid inferences concerning the relation of giant cell change to the presence or absence of skip lesions. Additional immunostains for LCA and CD15 (Hapten X) may be helpful in diagnosis. In two cases where no inflammatory cells were evident on H&E sections of the vessel from the area of the skip lesion, inflammatory cells were identified by immunohistochemistry in the adventitia. This may prove helpful in future, and it is now the practice in our laboratory to perform stains for LCA and CD15 where skip lesions are suspected but where no definite inflammatory cells are seen on H&E staining in the affected segment.

Skip lesions are relatively uncommon in temporal arteritis and their identification indicates that the inflammation is discontinuous. The examination of multiple levels of temporal artery, as was previously our practice in this institution, is probably unnecessary provided that the artery specimen is of adequate length, and that the whole length of the vessel is processed for histological examination.

- 1 Hunder GG, Bloch DA, Michel BA, *et al.* The American College of Rheumatology 1990 criteria for classification of giant cell arteritis. *Arthritis Rheum* 1990;33:1122–8.
- 2 Klein RG, Campbell RJ, Hunder GG, *et al.* Skip lesions in temporal arteritis. *Mayo Clin Proc* 1976;51:504–10.
- 3 Cohen DN, Smith TR. Skip areas in temporal arteritis: myth versus fact. *Trans Am Acad Ophthalmol* 1974;78:772–83.
- 4 Lie JT. Systemic, pulmonary and cerebral vasculitis. In: Stehbens WE, Lie JT, eds. *Vascular pathology*. London: Chapman and Hall, 1995:623–56.
- 5 Sudlow C. Diagnosing and managing polymyalgia rheumatica and temporal arteritis. *BMJ* 1997;315:549.
- 6 Lie JT. Temporal artery biopsy diagnosis of giant cell arteritis: lessons from 1109 biopsies. *Anat Pathol* 1996;1:69–97.