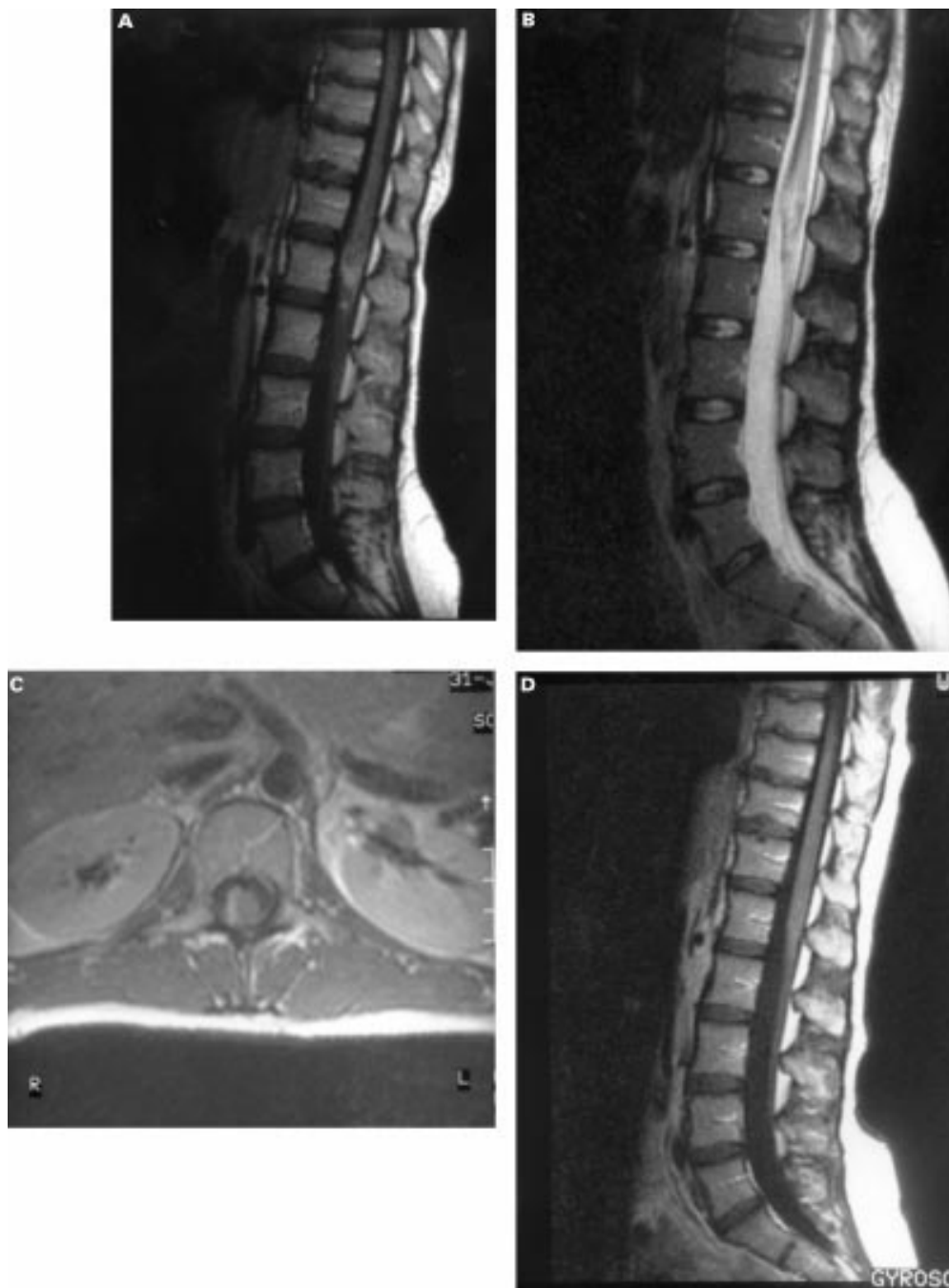


NEUROLOGICAL PICTURE

Spinal cord schistosomiasis

A 29 year old woman developed a progressive radicular pain in her right leg 2 weeks before admission. Examination disclosed hypaesthesia on the lateral side of the right foot, a paresis of the foot flexor and extensors, Medical Research Council (MRC) grade 4, with a positive straight leg raising test and absent right ankle

tendon reflex. Six months before admission she had travelled in Africa and swam in Lake Malawi. Gadolinium enhanced T1 weighted and T2 weighted MRI (figure, A and B) showed swelling of the conus medullaris with irregular enhancement. On transverse gadolinium enhanced T1 weighted MRI (figure, C) on



the right a perimedular slightly enhancing space occupying lesion was shown. Analysis of CSF disclosed a pleiocytosis ($125.10^6/l$ leucocytes, predominantly monocytes with sporadic eosinophils). The protein concentration was 0.64 g/l and glucose 3.4 mmol/l. Schistosomiasis of the spinal cord was diagnosed based on the clinical presentation, exposure history, and demonstration of schistosomiasis antibodies in the serum (enzyme linked immunosorbent assay (ELISA) 1:64, (immunofluorescence assay (IFA)>1:1024. Ova were not found in urine or faeces. After treatment with praziquantel (40 mg/kg in one dose) and prednisone (1 mg/kg for 5 days) she improved. Because of recurrence of the radicular pain, progression of

her paresis, and impaired sensation in the L5 and S1 dermatoma on the right, she was additionally treated with praziquantel (20 mg/kg for 3 days) and prednisone (1 mg/kg for 14 days). Six months later only a slight hypaesthesia in the S1 dermatoma on the right persisted. Absent swelling and only minimal perimedullary changes were seen on a gadolinium enhanced T1 weighted MRI (figure, D).

HARRY VAN LEUSEN

WIM V M PERQUIN

*Department of Neurology, Westeinde Hospital,
Medisch Centrum Haaglanden PO Box 432,
2512 VA, The Hague, The Netherlands*

Correspondence to: Dr Wim V M Perquin
perquinw@KNMG.NL