

SHORT REPORT

Idiopathic ocular neuromyotonia: a neurovascular compression syndrome?

C Tilikete, C Vial, M Niederlaender, P L Bonnier, A Vighetto

Abstract

Ocular neuromyotonia in the muscles innervated by the right oculomotor nerve was diagnosed in a patient without a history of radiation therapy. Electromyography of the levator palpebrae showed continuous motor unit activity. Brain MRI disclosed a close contact between the right third cranial nerve and a basilar artery dolichoectasia. The patient partly benefited from carbamazepine therapy. This unique finding suggests that neurovascular compression syndrome could be an hitherto unrecognised cause of ocular neuromyotonia.

(J Neurol Neurosurg Psychiatry 2000;69:642-644)

Keywords: ocular neuromyotonia; neurovascular compression syndrome; carbamazepine

Neuro-ophthalmology Unit, Hôpital Neurologique et Neurochirurgical P Wertheimer, 59 Bd Pinel, 69003 Lyon, France
C Tilikete
A Vighetto

Electromyography Unit, Hôpital Neurologique et Neurochirurgical P Wertheimer, 59 Bd Pinel, 69003 Lyon, France
C Vial

Neuro-radiology Unit, Hôpital Neurologique et Neurochirurgical P Wertheimer, 59 Bd Pinel, 69003 Lyon, France
M Niederlaender

Radiology Unit, Clinique de la Sauvegarde, Av des sources, 69 009 Lyon, France
P L Bonnier

Correspondence to:
Dr Caroline Tilikete
caroline.tilikete@free.fr

Received 6 December 1999
and in revised form
24 February 2000
Accepted 6 March 2000

specifically there was no history of radiation treatment.

Neuro-ophthalmological examination showed normal visual acuity, visual field, and fundi. Between episodes, the patient had mild ptosis, poorly reactive miosis, and slight limitation of infraduction and supraduction of the right eye. Orthoptic measurements showed a small exophoria worsening on left gaze, a right hypophoria in primary and far up gaze, and a small right hyperphoria in far down gaze. There was no evidence of primary misdirection phenomena. Her right pupil was 2.4 mm and the left pupil was 2.8 mm diameter. Cocaine instillation resulted in a bilateral pupil dilation (RE=3.5 mm and LE=3.7 mm) ruling out ocular sympathetic paresis. Ptosis and limitation of eye movements suggested a minimal right third nerve palsy. Neurological examination was otherwise normal.

Diplopic paroxysms could occur spontaneously but were often triggered by holding the eyes upwards for 20 to 30 seconds. During an attack, the right eye showed mild esotropia, marked limitation of supraduction, and infraduction with lid retraction, mild limitation of abduction, and no change in the pupil size. Paroxysmal diplopia could not be triggered by hyperventilation.

Electromyography with a concentric needle (diameter=0.3 mm) was normal, showing no spontaneous activity or myotonia in the first dorsal interosseus, the deltoid, and the orbicularis oculi. However, EMG was abnormal in the right levator palpebrae, disclosing spontaneous continuous muscle unit activity, with brief bursts of motor unit potentials, firing at high frequency. Voluntary contraction of this muscle was normal and no afterdischarges were recorded.

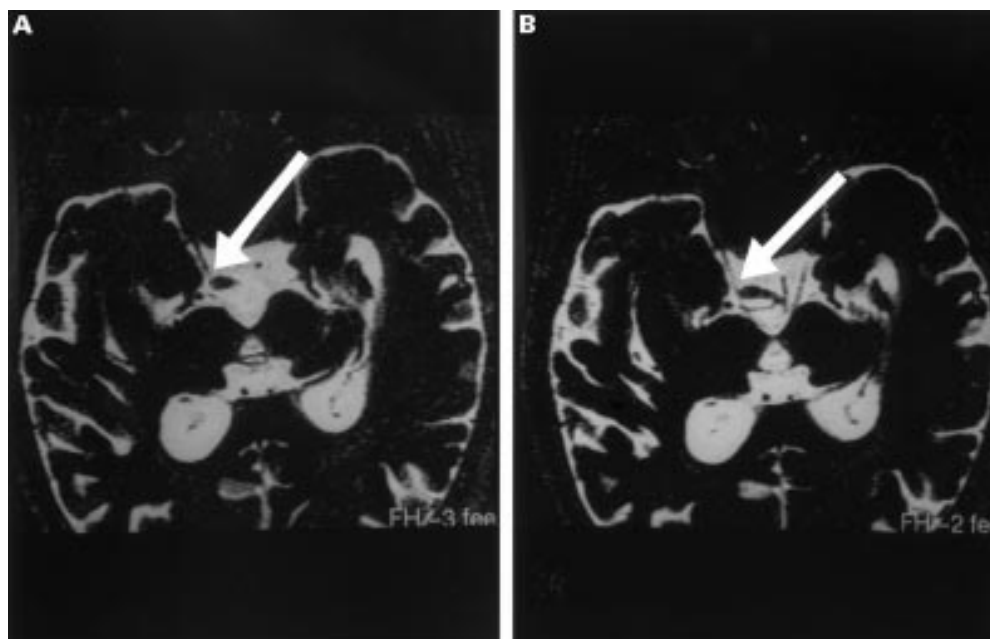
Brain CT (GE, slice thickness=5 mm) with and without contrast enhancement did not show any brain stem lesion but disclosed a dolichoectasia of the basilar artery displaying a large right sided loop anterior to the mesencephalon. T2 MRI (Philips Gyroscan T5-NT; 0.5 tesla with head coil; TR=5000 ms, TE=450 ms, TF=69; slice thickness=1 mm) of the brain stem using fast spin echo high resolution (FSE-HR) in the plane of the third nerve was performed. It showed a contact between the loop of the dolichoectasic basilar artery and the right oculomotor nerve in the premen-

Ocular neuromyotonia is a rare paroxysmal involuntary contraction of one or more ocular motor muscles resulting in paroxysmal diplopia and strabismus. Among 29 patients reported in the literature, 16 had received radiation therapy to the parasellar and sellar regions a few months to 18 years before.¹⁻⁶ In seven cases, ocular neuromyotonia resulted from compressive lesions such as a clivus chordoma, a supraclinoid carotid aneurysm, a Paget bone dystrophy, a mycormycosis of the cavernous sinus, arachnoiditis, and Graves' disease.^{3-5 7} In the six remaining patients, no lesion was found.^{3 5 8 9} We document with EMG and MRI a unique case of neurovascular compression syndrome associated with idiopathic ocular neuromyotonia.

Case report

A 67 year old man presented with a 1 month history of episodic diplopia. He reported spells of horizontal or oblique double vision that occurred spontaneously five or six times a day, lasting less than 10 seconds. While complaining of diplopia, his wife noticed a transient esodeviation of the right eye. He was symptom free between attacks.

History disclosed abdominal aortic aneurysm, lumbar sympathectomy for arteriopathy, and asymptomatic 50% stenosis of the left carotid artery. There was no history of ocular motor, anisocoria, or neurological disorder and



FSE-HR T2 MRI of the brain stem in the plane of the third nerves showing a contact between the loop of the dolichoectatic basilar artery and the right oculomotor nerve (arrows) in the premesencephalic fossa, close to the root exit zone.

cephalic fossa, close to the root exit zone (figure).

The patient was treated with 100 mg carbamazepine daily. He subjectively reported a 50% decrease of spell frequency within a few days. However, on examination, the same paroxysms of ocular spasms could still be triggered by holding the eyes upward. Finally, carbamazepine was poorly tolerated even at the low dose and was stopped. Spell frequency then returned to its pretest level. Gabapentine (300 mg three times a day) and acetazolamide (250 mg twice a day) trials yielded no benefit. After a 1 year follow up, the patient remained medication free and still had the same eye movement disorder.

Discussion

The paroxysmal limitation of right eye movements that occurred in this patient was typical of ocular neuromyotonia affecting muscles innervated by the oculomotor nerve. Indeed, the clinical hallmark of ocular neuromyotonia is transient diplopia and strabismus that develop spontaneously and after holding eccentric gaze, due to a tonic contraction or spasm of ocular muscles.⁸ In this patient, sustained upgaze induced spasms of the levator palpebrae and superior rectus of the right eye with resulting lid retraction and limitation of infraduction. Concomitant spasms of inferior oblique, inferior rectus, and medial rectus best explained the limitation of supraduction and abduction of the same right eye. This coactivation of muscles related to the same ocular motor nerve is a frequent symptom of ocular neuromyotonia.³ Our case associated ocular neuromyotonia with a chronic third nerve deficit. Half of the reported cases of ocular neuromyotonia have also a chronic ocular motor nerve involvement. Involvement of pupil motility has been rarely reported in ocular neuromyotonia of the third nerve, as permanent

parietic pupil dilation, rarely as transient pupil contraction occurring during the diplopic spells, and in one recent case as permanent tonic pupil.^{3,7} Right miosis of our patient could either be related to unknown physiological anisocoria or permanent tonic pupil related to ocular neuromyotonia. Other permanent excitatory manifestations in the third nerve dependent muscles have been reported, such as lid retraction and pupil synkinesis.

Neuromyotonia (not limited to ocular neuromyotonia) is a syndrome of spontaneous muscle hyperactivity that can be triggered by voluntary muscle contraction, due to abnormal excitability of peripheral nerve motor axons.¹⁰ Neuromyotonia belongs to the syndromes of continuous motor unit activity which encompass different diseases that vary in their clinical presentation and associated electrophysiological abnormalities, but have in common sustained involuntary motor unit activity.¹⁰ In continuous motor unit activity, EMG shows continuous hyperactivity such as neuromyotonic and myokimic discharges and fasciculations. Continuous motor unit activity is associated with peripheral motor nerve diseases, either in a diffuse or a focal distribution.¹⁰ Ocular neuromyotonia is likely to be related to focal continuous motor unit activity. Indeed, in the first reported cases of ocular neuromyotonia extraocular muscle EMG showed neurogenic abnormalities.^{1,2} Since then, the disease has been clinically recognised without EMG investigation. In our patient, we were able to record EMG activity in the levator palpebrae, and we showed unambiguous signs of continuous motor unit activity. This result indicates that ocular neuromyotonia, at least in our case, meets diagnosis criteria for focal continuous motor unit activity.

Radiation induced plexus lesion is a well established cause of focal limb continuous motor unit activity. Many cases of ocular neu-

romyotonia also occurred after cerebral radiation therapy. Focal continuous motor unit activity may involve other cranial nerves. Among them, hemifacial spasm usually results from neurovascular compression syndrome and recently, a case of superior oblique myokimia has also been related to a neurovascular compression.^{11 12} Brain MRI in our patient clearly demonstrated a close contact between dolichoectasic basilar artery loop and the third nerve, near the root exit zone. Abnormal enlargement and elongation of the basilar artery (vertebrobasilar dolichoectasia) is a well recognised finding in brain imaging studies and affects 1.7% of the population.¹³ This condition is asymptomatic but in 6% of patients, it may cause rostral brain stem signs and symptoms, usually related to ischaemia or compression. Compression by a dolichoectasic basilar artery has already been involved in ocular motor nerve paresis and in hemifacial spasm.^{10 14} Although we cannot rule out a coincidental finding, we suggest that it could explain the oculomotor nerve ocular neuromyotonia in our case.

Ephaptic neural transmission is the potential mechanism for hemifacial spasm, ocular neuromyotonia, and likely superior oblique neuromyokimia. In our patient, as in hemifacial spasm, this ephaptic neural transmission could originate in a segmental demyelinated portion of the nerve, where vascular compression occurs.⁸ However, hyperventilation, which may precipitate manifestations of demyelinating lesion on cranial nerves, did not trigger ocular neuromyotonia spells in our patient.¹⁵ On the other hand, sensitivity to carbamazepine (a membrane stabilising agent), even at low doses such as 100 mg twice a day in ocular neuromyotonia, is consistent with this concept. Our patient had decreased diplopic spell

frequency with 50 mg carbamazepine twice a day. Unfortunately, the medication was poorly tolerated and had to be stopped. Other membrane stabilising agents such as gabapentine and acetazolamide were not efficient in our case.

We suggest that some idiopathic ocular neuromyotonias might be explained by vascular compression of one ocular motor nerve, which might be identified by specific MRI investigation.

We thank Professor DS Zee for helpful commentaries, and Mrs M Bongrand for orthoptic assistance.

- 1 Ricker VK, Mertens HG. Okulare neuromyotonie. *Klin Monatsbl Augenheilkd* 1970;156:837-42.
- 2 Papst W. Zur differentialdiagnose der okularen neuromyotonie. *Ophthalmologica* 1972;164:252-63.
- 3 Ezra E, Spalton D, Sanders MD, et al. Ocular neuromyotonia. *Br J Ophthalmol* 1996;80:350-5.
- 4 Yee RD, Purvin VA. Ocular neuromyotonia : three case reports with eye movement recording. *J Neuroophthalmol* 1998;18:1-8.
- 5 Shults WT, Hoyt WF, Behrens M, et al. Ocular neuromyotonia. A clinical description of six cases. *Arch Ophthalmol* 1986;104:1028-34.
- 6 Morrow MJ, Kao GW, Arnold AC. Bilateral ocular neuromyotonia: oculagraphic correlations. *Neurology* 1996;46:264-6.
- 7 Abdulla N, Eustace P. A case of ocular neuromyotonia with tonic pupil. *J Neuroophthalmol* 1999;19:125-7.
- 8 Frohman EM, Zee DS. Ocular neuromyotonia: clinical features, physiological mechanisms and response to therapy. *Ann Neurol* 1995;37:620-6.
- 9 Safran AB, Magistris M. Terminating attacks of ocular neuromyotonia. *J Neuroophthalmol* 1998;18:47-8.
- 10 Auger RG. Diseases associated with excess motor unit activity. *Muscle Nerve* 1994;17:1250-63.
- 11 Milandre L, Bonnefoie B, Pestre P, et al. Dolichoectasies artérielles vertébrobasilaires. *Rev Neurol* 1991;147:714-22.
- 12 Samii M, Rosahl SK, Carvalho GA, et al. Microvascular decompression for superior oblique myokimia: first experience. *J Neurosurg* 1998;89:1020-4.
- 13 Yu YL, Moseley IF, Pullicino P, et al. The clinical picture of ectasia of the intracerebral arteries. *J Neurol Neurosurg Psychiatry* 1982;45:29-36.
- 14 Moschner C, Moser A, Kömpf D. Bilateral oculomotor nerve palsy due to dolichoectasia of the basilar artery. *Neuroophthalmology* 1997;17:39-43.
- 15 Walker MF, Zee DS. The effect of hyperventilation on downbeat nystagmus in cerebellar disorders. *Neurology* 1999;53:1576-9.