

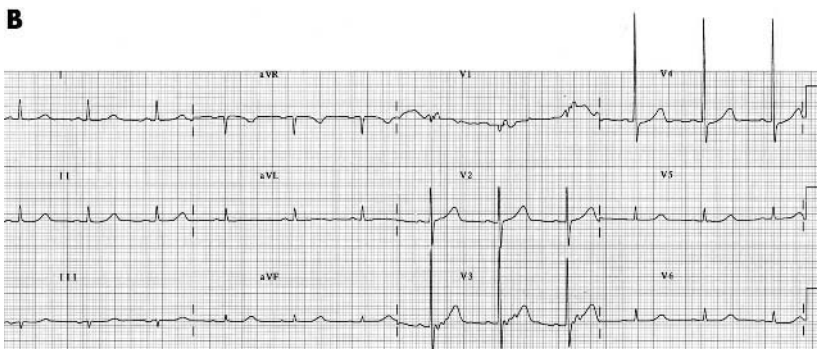
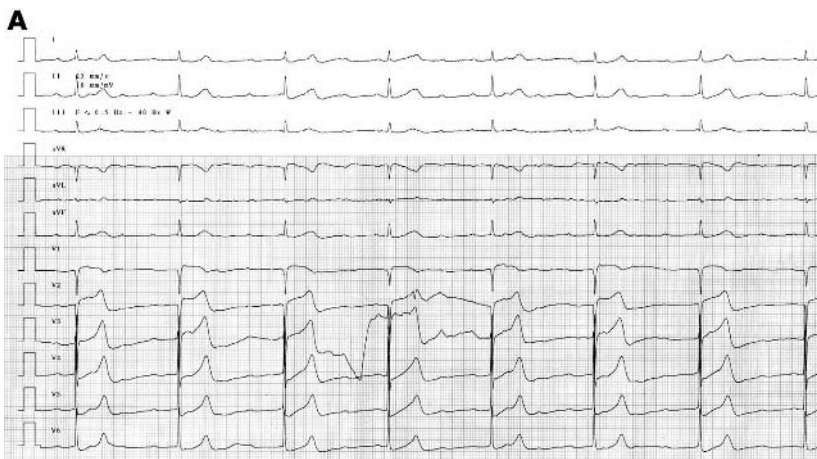IMAGES IN CARDIOLOGY.....

Heart 2005;91:e5 (<http://www.heartjnl.com/cgi/content/full/91/1/e5>). doi: 10.1136/hrt.2004.046524

Hyperkalaemia induced complete atrioventricular block with a narrow QRS complex

A 77 year old woman was admitted to the hospital because of dyspnoea and dizziness for 3 hours. Upon physical examination, her blood pressure was 80/40 mm Hg, with a regular pulse rate of 33 beats per minute. The ECG on admission exhibited P waves with a rate of 100 beats/min and a positive pattern in leads II, III and aVF, third degree atrioventricular (AV) block, AV dissociation with a ventricular rate of 33 beats/min, an 80-ms wide QRS complex, and QT interval of 640 ms (panel A). Temporary percutaneous pacing was begun immediately, resulting in a prompt improvement in the stabilisation of the haemodynamic status. The laboratory findings included a serum potassium level of 7.99 mEq/l, sodium 137.1 mEq/l, urea nitrogen 46.62 mg/dl, and creatinine 3.22 mg/dl. The arterial blood gas analysis revealed a pH of 7.41, pO₂ 74.0 mm Hg, and pCO₂ 31.8 mm Hg. Her blood potassium level decreased rapidly, and after 2 hours of being treated with a glucose solution, insulin and bicarbonate, it became 5.03 mEq/l. At that time her ECG exhibited normal sinus rhythm (panel B).

Hyperkalaemia induced complete AV block without prolongation of the QRS complex is a rare condition. Hyperkalaemia can be responsible for a wide spectrum of electrocardiographic abnormalities. In general, hyperkalaemia produces a gradual depression of the excitability, conduction velocity of the specialised pacemaker cells and conducting tissues throughout the heart. High serum potassium levels are thought to impair the conduction in the Purkinje fibers and ventricles more than



in the AV node, although complete atrioventricular block can occur. In this case temporary pacing and excretion of the excessive levels of the serum potassium were essential.

N-H Kim
S K Oh
J-W Jeong
cardionh@wonkwang.ac.kr