

## IMAGES IN CARDIOLOGY .....

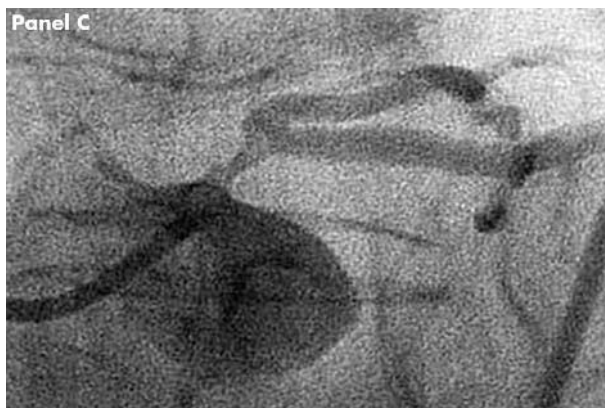
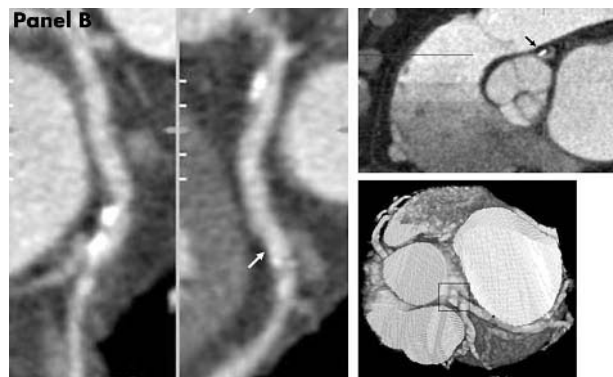
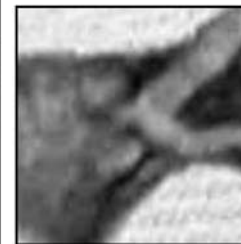
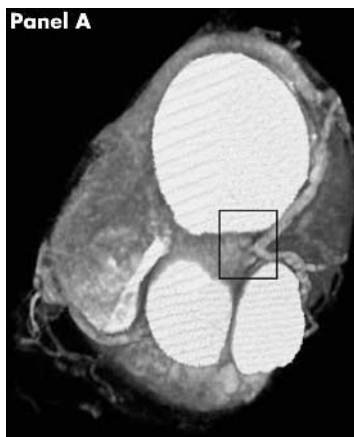Heart 2005;91:e53 (<http://www.heartjnl.com/cgi/content/full/91/7/e53>) doi: 10.1136/hrt.2004.049916

## Balanced myocardial ischaemia: a case of "normal" stress Tc99 sestamibi scan and diagnosis

**A** 78 year old woman suffered a near syncopal event and was diagnosed with a possible transient ischaemic attack (TIA). Clinical history revealed a vague 3 year history of stable exertional chest pain. Initial diagnostic evaluation included a transthoracic echo (negative for cardiac pathology) and carotid ultrasound that showed mild plaque only. An adenosine sestamibi scan showed no resting or stress induced perfusion defects, although ST segment depression was noted on the ECG. Coronary computed tomography (CT) angiogram was performed (Siemens Sensation 16) to assess her coronary arteries.

The CT angiogram demonstrated a severe, calcified ostial left main lesion (panels A and B), confirmed by invasive coronary angiography (panel C). Successful coronary artery bypass surgery followed.

Stress induced hypoperfusion using Tc99 sestamibi scans depend on relative differences in regional myocardial perfusion. Coronary CT angiography provides a non-invasive anatomic image of the coronary arteries and in this case allowed detection of a life threatening left main lesion. This lesion likely caused a balanced decrease in myocardial perfusion and resulted in a false negative nuclear stress perfusion study.



J R Lesser  
R Bae  
B Flygenring  
S S Sharkey  
J Lindberg  
R S Schwartz  
[rss@rsschwartz.com](mailto:rss@rsschwartz.com)